

Incidental Schistosomiasis In A Dermoid Cyst Of The Ovary: A Case Report

N Sarma, S Agnihotri, N Jeebun

Citation

N Sarma, S Agnihotri, N Jeebun. *Incidental Schistosomiasis In A Dermoid Cyst Of The Ovary: A Case Report*. The Internet Journal of Parasitic Diseases. 2007 Volume 3 Number 1.

Abstract

Schistosomal infestation of the female genital system is uncommon and involvement of ovaries is even rarer. Incidental schistosomiasis of various ovarian lesions have been cited in the literature. A case of schistosomiasis of the dermoid cyst of the ovary is presented to highlight the rare occurrence of this lesion.

INTRODUCTION

The Schistosomes are the most important of the trematodes that infect humans, not only because of the morbidity and the mortality they produce, but also because of the sheer number of infected people worldwide₁. The *Schistosoma hematobium* species colonizes the venules of the pelvic venous plexuses draining the Urinary bladder, less commonly the female genital system, and the veins of the lower sigmoid and rectum₂.

Schistosomiasis of the female genital tract is common in some areas of Africa₃. Female

Genital schistosomiasis is a neglected disease manifestation of infection. *Schistosoma* may affect cervix, vagina, vulva, fallopian tubes and ovaries. Infertility, ectopic pregnancies, abortion, ovarian cysts and cervicitis are described sequelae of infection. The presence of *Schistosoma* eggs in a teratoma of the ovary is a very rare occurrence. Only 4 such cases appear to have been documented in the world literature_{4,5,6,7}. We present here a case of incidental finding of *Schistosoma hematobium* eggs in a benign cystic teratoma of the ovary because of its rarity.

CASE REPORT

A 28 year old female presented with dull aching pain in the left lower abdomen of two months duration. The pain was not related with change in posture or menstruation. The patient was married with two children. Physical examination did not reveal any significant findings but for a suspicious mass in the left iliac fossa. There were no significant obstetric or gynecological symptoms or findings attributable

to this mass. Ultrasound examination suggested a cystic mass of the left ovary measuring about 7X4 cms. Right ovary was normal. A provisional diagnosis of dermoid cyst of the ovary was made. The ovarian mass was excised and sent for histopathological examination.

GROSS APPEARANCE

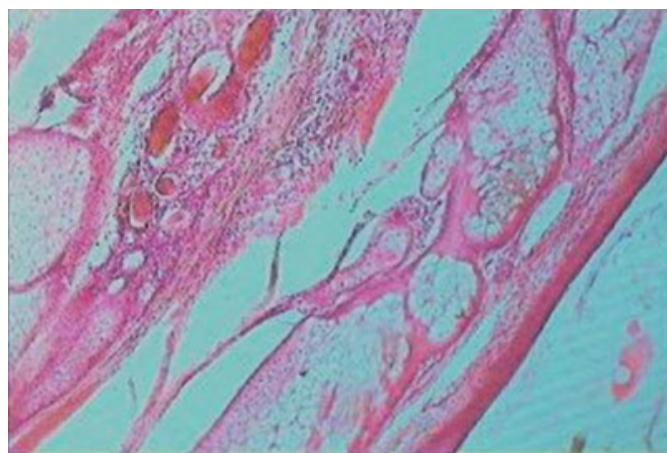
The mass received was well circumscribed, smooth, grayish brown, cystic and measured 7X4X3cms. On opening, the mass showed unilocular cystic appearance containing grayish putty like material entangled with plenty of hair. The inner surface of the cyst wall was rough, grayish brown with hair protruding at places. In one area there was a small firm to hard elevated protrusion into the cyst cavity which measured 0.8X0.5 cms.

MICROSCOPIC APPEARANCE

Multiple sections taken from the cyst wall and the firm to hard area revealed the characteristic features consistent with dermoid cyst of the ovary (fig.1).

Figure 1

Figure 1: Low power view showing the predominant ectodermal element with hair, epidermis Sebaceous glands,dermis and subcutaneous fat. H & E 4 X



In addition to these findings there were *S. Hematobium* eggs scattered through out and seen exclusively in the dermis and the subcutaneous fat. Some of these eggs were calcified and foci of moderate inflammatory infiltrate was seen through out(fig.2,3). Adult parasite was not identified.

Figure 2

Figure 2: High power view showing *Schistosoma* hematobium eggs and the inflammatory infiltrate around them. H & E 10 X

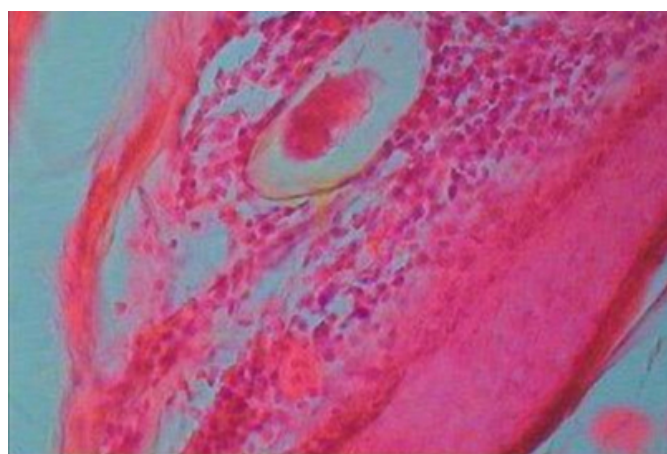
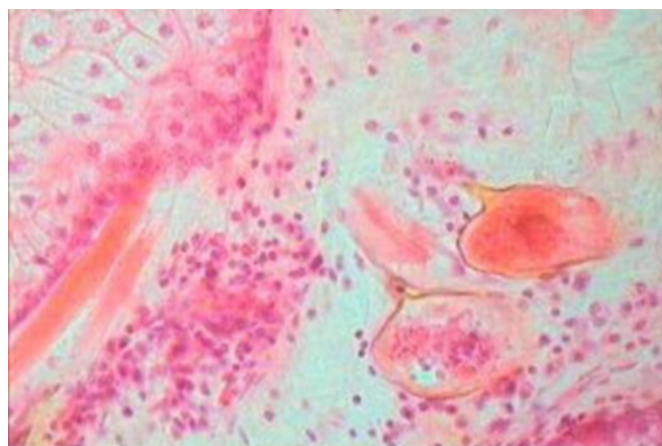


Figure 3

Figure 3: High power view showing *Schistosoma* hematobium egg surrounded by inflammatory infiltrate. H & E 40 X



DISCUSSION

Schistosomiasis is a helmenthic parasitic infection afflicting about 250 million people around the world ⁸. Female genital schistosomiasis was described for the first time in a young Egyptian woman more than a century ago⁹. Female genital schistosomiasis is a neglected disease manifestation of Schistosomiasis. According to postmortem and histopathological examination studies the frequency of female genital schistosomiasis in the upper reproductive tract ranges from 2 percent to 83 percent¹⁰. In the lower reproductive tract the prevalence is 33 percent to 75 percent¹¹. In one study conducted over a period of 12 years showed the varied distribution of genital Schistosomiasis as follows: Ovary 21%,Fallopian tube 16%,Uterine cervix 42%,Vulva,Vagina and Clitoris 21% ¹².

Various pathological processes of the ovary are seen to be associated with Schistosomiasis, such as oophoritis, ovarian cyst, hilar obstruction and para ovarian adhesions and granulomatous lesions. These lesions can be responsible for anovulation leading to infertility¹³.In our study the patient presented with the mass without any finding suggestive of the pathological processes mentioned above.

There are only four reports of *Schistosoma* hematobium eggs being found in a teratoma of the Ovary ^{4, 5, 6, 7}. In all these cases the finding of *Schistosoma* eggs was considered as incidental finding than as causative finding. There is no evidence so far to say that schistosomiasis can be a pathogenic factor in the development of teratoma of the ovary. In the present study also the finding of *Schistosoma* eggs appear to be an incidental finding and the patient did

not have any indication of schistosoma infection in other locations of the genital tract.

Recently female genital schistosomiasis has been described wherein there was no involvement of Urinary bladder and Ureters. In this community based study from Africa 30-75% of the women infected with *Schistosoma hematobium* had egg associated lesions in the lower genital tract¹⁴.

Genital Schistosomiasis is nearly always caused by *S. Hematobium* and usually is a complication of Schistosomiasis of the Urinary bladder and Intestine. In the present study also the eggs found in dermoid cyst of the ovary were *Schistosoma hematobium* eggs.

CONCLUSION

Diagnosis of genital schistosomiasis is essential as it often and easily goes unnoticed or undetected. Genital Schistosomiasis adds to the disease burden of women of all age groups. Incidental findings like in the present one should alert the physician and the community health worker to conduct regular reproductive health checkup so that no case of Schistosomiasis should go undetected and thus untreated.

CORRESPONDING AUTHOR

DR.N.HARIHARANADHA SARMA.M.D, PROFESSOR OF PATHOLOGY SSR MEDICAL COLLEGE BELLE RIVE MAURITIUS. e-mail: nandyalahari@yahoo.com

References

1. Beaver PC, Jung RC, Cupp EW. Clinical parasitology.9th ed. Philadelphia: Lea & Febiger;1984.
2. Hall SC, Kehoe EL. Prolonged survival of *Schistosoma japonicum*.Calif Med.1970 Aug; 113(2):75-7.
3. Berry A. A cytopathological and histopathological study of bilharziasis of the female genital tract. J Pathol Bacteriol.1966.Apr; 91(2):325-8.
4. Abuzikry AM, Fahmy K. Bilharziasis in a dermoid cyst of the ovary. J Obstet Gynecol Br Commonw.1963 oct; 70:891-3.
5. Paradinas FJ. Schistosomiasis in a cystic teratoma of the ovary. J Pathol. 1972 Feb;106(2): 123-6.
6. Sunder-Raj S. Cystic teratoma of ovary associated with schistosomiasis. East Afr Med J.1976 Feb; 53(2):111-4.
7. Melato M, Muuse MM, Hussein AM, Falconieri G. Schistosomiasis in a cystic teratoma of the ovary. Clin Exp Obstet Gynecol.1987 Jan; 14(1):57-9.
8. Chitsulo L, Engels D, Montresor A, Sovioli L. The global status of schistosomiasis and it's control.Acta Trop.2000 Oct 23; 77(1):41-51.
9. Madden FC. A case of Bilharzia of the vagina.Lancet.1899; 1716-8
10. Feldmeier H, Poggensee G, Krantz I, Helling-Giese G.Female genital schistosomiasis. New challenges from gender perspective.Trop Geograph Med.1995; 47(2 suppl):S2-15.
11. Leutscher P, Ravaoalimalala VE, Raharisolo C et al.Clinical findings in female genital schistosomiasis in Madagascar.Trop Med Int Health.1998 Apr;3(4):327-32.
12. Gouzou A,Baldassini B,Opa JF. Anatomicopathological aspects of genital bilharziasis in women. Med Trop(Mars).1984 Oct-Dec;44(4):331-337.
13. Helling-Giese G, Kjetland EF, Gundersen SG et al. Schistosomiasis in women: manifestations in the upper reproductive tract. Acta Tropica.1996 Dec 30; 62(4):225-38.
14. Poggensee A, Kiwelu I, Saria M, Richter JD, Krantz I, Feldmeier A.Schistosomiasis of the lower reproductive tract without egg excretion in urine. Am J Trop Med Hyg.1998 Nov; 59(5):782-3.

Author Information

N. Hariharanadha Sarma, M.D.

Professor and head, Department of Pathology, SSR Medical College

Smriti Agnihotri, M.D.

Reader, Department of Pathology, SSR Medical College

Nilima Jeebun, M.D.

Associate professor, Department of Pathology, SSR Medical College