

# Pneumosinus Dilatans of the Frontal Sinus

K Saravanan, N Saravanappa

## Citation

K Saravanan, N Saravanappa. *Pneumosinus Dilatans of the Frontal Sinus*. The Internet Journal of Radiology. 2007 Volume 8 Number 1.

## Abstract

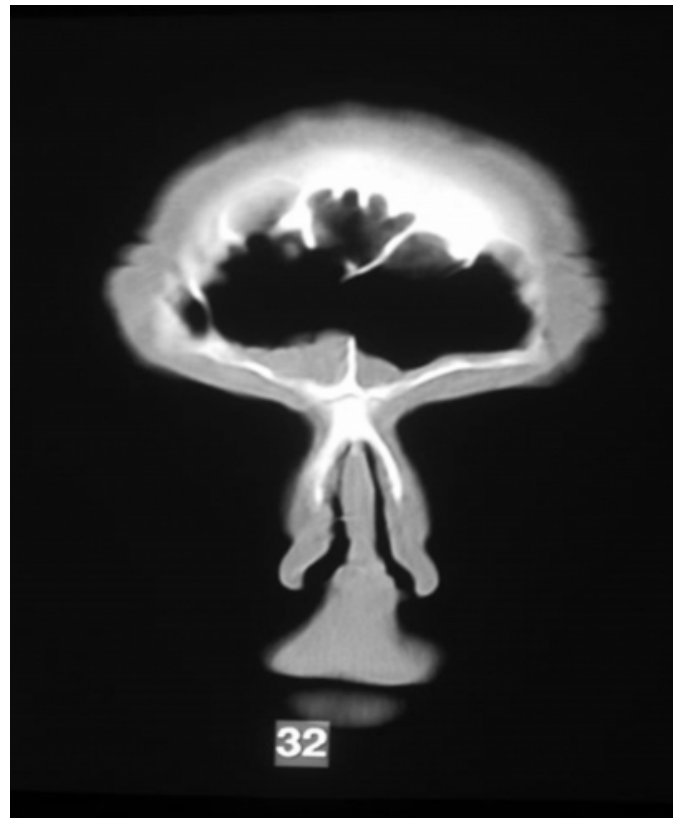
Pneumosinus dilatans is a rare condition of the aerated paranasal sinuses, predominantly affecting the frontal sinus. A review of the literature along with possible etiological mechanisms is presented in this report.

## CASE REPORT

A 46-year-old male patient presented initially to the ENT department with symptoms of bilateral nasal obstruction about 9 years ago. He was found to have bilateral extensive nasal polyps for which he had intranasal polypectomy and septoplasty. The intranasal polypectomy was repeated 2 years later. The gentleman was re-attended the department with similar complaints recently and was found to have polyps again in both the nostrils. Computerised tomography of the paranasal sinuses showed bilateral mucosal disease in both ethmoidal and maxillary sinuses but only limited disease in the frontal recess. The frontal sinus was clear and was found to be extensively pneumatised.

## Figure 1

Figure 1: Computerised tomography of frontal sinus showing enlarged frontal sinus with mucosal thickening at frontal recess



The patient underwent endoscopic intranasal polypectomy and functional endoscopic sinus surgery. He is being followed up for signs of recurrence of the disease.

## DISCUSSION

Benjamin first described Pneumosinus dilatans in 1918<sup>1</sup>. It is a rare condition affecting the paranasal sinuses characterised by expansion of the sinus wall beyond its normal margins.

This predominantly affects the frontal sinus (65%)<sup>2</sup>, followed by the sphenoid, maxillary and ethmoid sinuses in the descending order of frequency. Males are more commonly affected and the peak age incidence is the third to fourth decade. The commonest presentation of this condition, which is usually bilateral, in the frontal sinus, is enlarged forehead without underlying sinus disease. The macroscopic and microscopic appearance of the sinus mucosa is normal or associated with minimal inflammation. Progressive enlargement of the affected sinus needs surgical treatment to avoid pressure effects to the surrounding important structures. Computerised topographic imaging clinches the diagnosis and is the imaging modality of choice. Radiological classification of this condition is as follows: Hypersinus-enlarged sinus with normal walls, pneumosinus-sinus wall expanded beyond the normal boundaries and pneumocele-expanded sinus wall associated with thinning.

The etiology of this condition is largely unknown but there are various theories trying to explain its origin<sup>3</sup>. The most widely accepted theory is that of a ball valve mechanism theory with partial obstruction to the sinus opening, as the condition stops progressing after surgical creation of a naso-

antral window. The other proposed theories include spontaneous drainage of mucocoele, infection with gas forming organisms within the sinus, congenital and hormonal. The patient in this case report had extensive ethmoidal and maxillary sinus disease but only limited disease at the frontal recess. The presence of disease in the frontal recess only supports the ball valve mechanism theory however as there were no previous scans to compare with it was difficult to prove that the pneumosinus developed due to ball valve mechanism theory.

In summary pneumosinus dilatans is a rare condition affecting mainly the frontal sinus, the diagnosis of which is usually confirmed by computerised tomography, and it requires no treatment if the condition is not progressive.

### **References**

1. Benjamins CE. Pneumosinus frontal dilatans. *Acta Otolaryngol* 1918; 1:412-422
2. Walker J L, Jones N S. *Journal of laryngology otology*. Pneumosinus dilatans of the frontal sinus: two cases and a discussion of its etiology. 2002; 116:382-385
3. Adams WM, Jones RI, Chavda SI, Pahor AL, Taifa KT. Pneumosinus dilatans: a discussion of four cases and possible etiology. *Rhinology* 1998; 1:40-2

**Author Information**

**K. Saravanan, MRCS, DO-HNS**

Dept of ENT, Staffordshire General Hospital

**N. Saravanappa, FRCS(ORL-NHS)**

Dept of ENT, Staffordshire General Hospital