

Malignant Ascites Of Unknown Primary Tumour Site: A Clinical Dilemma

S Kumar Sahu, R Verma, P Sachan, D Bahl

Citation

S Kumar Sahu, R Verma, P Sachan, D Bahl. *Malignant Ascites Of Unknown Primary Tumour Site: A Clinical Dilemma*. The Internet Journal of Surgery. 2006 Volume 11 Number 1.

Abstract

Malignant Ascites is an adverse event in the course of malignancy. In 10-20% of cases, the primary tumor may be difficult to detect and presents as a clinical enigma. Ascitic fluid analysis, tumor markers, radiological imaging and even diagnostic laparoscopy may fail to detect the primary tumor. Due to the limited survival rate, supportive and symptomatic therapy remains the mainstay of the management and an aggressive approach is not indicated.

We present a case of malignant ascites in which the primary tumor remained unknown.

INTRODUCTION

Malignant ascites, a manifestation of advanced malignant disease usually follows peritonitis carcinomatosa, indicating the presence of malignant cells in the peritoneal cavity.¹

The common primary sites associated with malignant ascites are ovary, endometrium, colon, rectum, cervix and stomach.^{2,3} Malignant ascites is also associated with lymphoma, breast carcinoma, carcinoma of the prostate and digestive endocrine tumours such as carcinoid tumours.^{25,26,27,28}

CASE REPORT

A 40-year-old male, with an average body built, presented with a progressive distension of the abdomen since 15 days. There was no history of fever, loss of weight, vomiting, jaundice and altered bowel habits. Examination revealed only a gross ascites. Digital rectal examination was found to be normal.

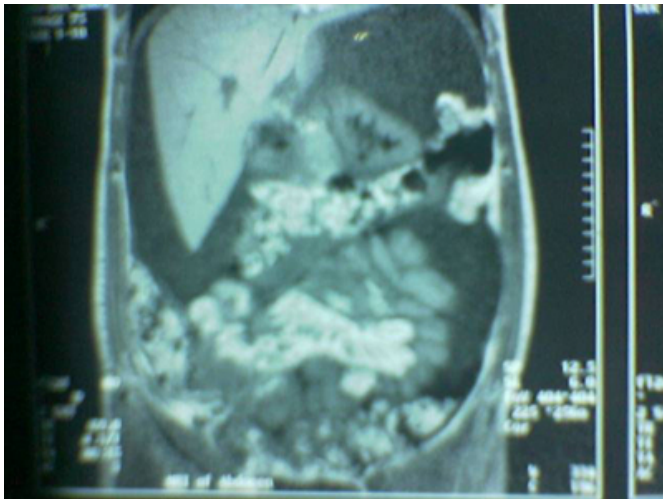
The relevant laboratory findings were: Haemoglobin 13.9gm/dl, Total Leukocyte Count 14390, Differential Leukocyte Count: Neutrophils 68%, Lymphocytes 31%, Eosinophils 1% and ESR 17mm (1st hr). Liver function tests and renal function tests were within normal limits. Chest X-ray was normal. Plain X-ray of the abdomen showed a diffuse haziness suggestive of ascites.

Repeated therapeutic abdominal paracentesis (which showed

a grossly hemorrhagic ascites) was performed to relieve the symptoms. Biochemical analysis of ascitic fluid showed: Glucose 143mg/dl and Protein 5.8gm/dl. The cytological study of the centrifuged ascitic fluid showed atypical cells with marked anisocytosis, altered N:C-ratio and anisonucleosis. Serum - Ascites Albumin Gradient (SAAG) was found to be 6gm/l.

MRI of the abdomen suggested ascites with a thickened omentum and mesentery with mesenteric lymphadenopathy. (Fig-1) A diagnostic laparoscopy was planned and revealed ascites with peritoneal seedlings, partially distended ileal loops adhered to the pelvic cavity and a thickened and rolled up omentum around the greater curvature of the stomach, biopsy of which showed chronic inflammation with fibrosis.

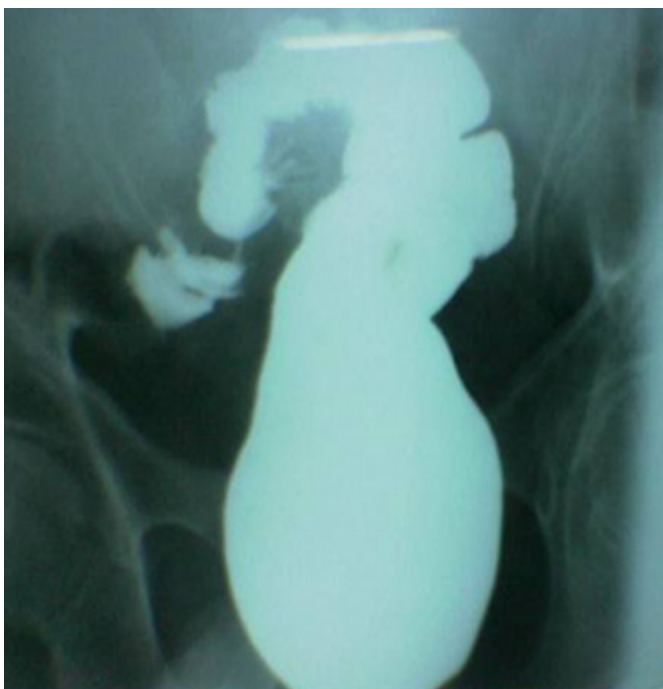Figure 1



MRI of the abdomen showing ascites with a thickened omentum.

Post-operatively, the patient was subjected to upper GI endoscopy, which was found to be normal. A colonoscopy was done in which the scope could not be negotiated beyond 30cm from the anal verge, suggesting a stricture without any obvious growth. A Barium enema was planned which showed a narrowing at the recto-sigmoid junction. (Fig-2) However, Carcino-Embryonic Antigen (CEA) study was within normal limits. Malignant ascites of unknown primary tumor was a clinical dilemma.

Figure 2



Barium enema showing a suspicious narrowing in the region of the recto-sigmoid junction.

DISCUSSION

In 10-20% of malignant ascites, the primary tumor may be difficult to detect.^{2,3}

Although lymphatic obstruction has been considered the major pathophysiologic mechanism behind its formation, recent evidence suggests that immune modulators, vascular permeability factors such as vascular endothelial growth factor and basic fibroblast growth factor and metalloproteinase are contributing significantly to the process.^{1,4}

A grossly bloody peritoneal effusion along with a Serum-Ascites Albumin Gradient (SAAG) less than 11gm/l is commonly associated with malignant ascites.^{3,5} Markedly elevated ascitic fluid levels of vascular endothelial growth factor, cholesterol, type IV collagenase, fibronectin, protein and lactate dehydrogenase are diagnostic of malignant ascites.^{6,7,8,9,10} Malignant cells will be detected in ascitic fluid in nearly 40-60% of patients.^{10,11} Elevated levels of tumor markers such as CEA, CA-125, CA 19-9, PSA and -HCG may help in the diagnosis.¹²

Radiological imaging such as CT scan may not detect a primary in 10-20% cases of malignant ascites.^{2,13}

Laparoscopy with biopsy, when necessary, has an excellent effectiveness and accuracy for the diagnosis of the primary tumor in malignant ascites of unknown origin.¹⁴

The management of malignant ascites of unknown primary tumor is in evolution. Repeated abdominal paracentesis may be useful in reducing symptoms. Intraoperative placement of Foley's catheter for continuous drainage of malignant ascites carries a high mortality rate.¹⁵ Intraperitoneal instillation of radioisotope chromic phosphate colloid (³²P), immunotherapeutic agents such as trifunctional antibodies, endostatin adenoviral vector and triamcinolone hexacetanide have been tried. Octreotide as an agent for palliative care has also been studied.^{16,17,18,19,20}

Newer approaches such as cytoreductive surgery and intraperitoneal chemotherapy administration under hyperthermic conditions (40 & 3176;C to 43 °C) have been reported with success.²¹ Peritoneal venous shunts such as LeVeen and Denver shunt offer palliation.²² Abdominal compartment syndrome and spontaneous bacterial peritonitis have been reported with untreated malignant ascites.^{23,24}

However, the median survival of such patients is usually measured in days.²

CORRESPONDENCE TO

Dr. Shantanu Kumar Sahu Department of General Surgery Himalayan Institute of Medical Sciences Swamiramnagar Dehradun Uttarakhand. E-mail- Intshantanu@yahoo.co.in Mob- 9412933868.

References

1. Tamsma JT, Keizer HJ, Meinders AE. Pathogenesis of malignant ascites: Starling's law of capillary hemodynamics revisited. *Ann Oncol.* 2001 Oct; 12(10): 1353-7.
2. Ringenberg QS, Doll DC, Loy TS, Yarbrow JW: Malignant ascites of unknown origin. *Cancer.* 1989 Aug 1; 64(3): 753-5.
3. Malik I, Abubakar S, Rizwana I, Alam F, Rizvi J, Khan A. Clinical features and management of malignant ascites: *J Pak Med Assoc.* 1991 Feb; 41(2): 38-40.
4. Aslam N, Marino CR. Malignant ascites: new concepts in pathophysiology, diagnosis, and management. *Arch Intern Med.* 2001 Dec 10-24; 161(22): 2733-7.
5. Barbare JC, Diab G, Delavenne J, Philippe JM, Vorhauer W, Latrive JP, Capron JP. Concentration of lipids in ascitic fluid and the concentration gradient of albumin in blood and ascites: diagnostic significance: *Ann Gastroenterol Hepatol (Paris).* 1989 Nov; 25(6): 251-6.
6. Zebrowski BK, Liu W, Ramirez K, Akagi Y, Mills GB, Ellis LM. Markedly elevated levels of vascular endothelial growth factor in malignant ascites. *Ann Surg Oncol.* 1999 Jun; 6(4): 373-8.
7. Mortensen PB, Kristensen SD, Bloch A, Jacobsen BA, Rasmussen SN. Diagnostic value of ascitic fluid cholesterol levels in the prediction of malignancy: *Scand J Gastroenterol.* 1988 Nov; 23(9): 1085-8.
8. Sun XM, Dong WG, Yu BP, Luo HS, Yu JP. Detection of type IV collagenase activity in malignant ascites: *World J Gastroenterol.* 2003 Nov; 9(11): 2592-5.
9. Adamsen S, Jonsson P, Brodin B, Lindberg B, Jorpes P. Measurement of fibronectin concentration in benign and malignant ascites: *Eur J Surg.* 1991 May; 157(5): 325-8.
10. Castaldo G, Oriani G, Cimino L, Topa M, Mostarda I, Castellano L, Del Vecchio-Blanco C, Budillon G, Salvatore F, Sacchetti L. Total discrimination of peritoneal malignant ascites from cirrhosis- and hepatocarcinoma-associated ascites by assays of ascitic cholesterol and lactate dehydrogenase: *Clin Chem.* 1994 Mar; 40(3): 478-83.
11. R O S Karoo, T D R Lloyd, G Garcea, H D Redway and G S R Robertson. How valuable is ascitic cytology in the detection and management of malignancy? *Postgraduate Medical Journal* 2003; 79:292-294.
12. Shahangian S, Fritsche HA. Serum tumor markers as diagnostic aids in patients with unknown primary tumors. *Cancer Bulletin* 1989; 41:152.
13. Villanueva A, Perez C, Sabate JM, Llauger J, Gimenez A, Sanchis E, Garcia T, Moreno A. Peritoneal carcinomatosis. Review of CT findings in 107 cases: *Rev Esp Enferm Dig.* 1995 Oct; 87(10): 707-14.
14. Roskos M, Popp MB. Laparoscopic diagnosis and management of malignant ascites. *Surg Laparosc Endosc Percutan Tech.* 1999 Oct; 9(5):365-8.
15. Kuruvilla A, Busby G, Ramsewak S. Intraoperative placement of a self-retaining Foley catheter for continuous drainage of malignant ascites: *Eur J Gynaecol Oncol.* 2002; 23(1): 68-9.
16. Jackson GL, Blosser NM: Intracavitary chromic phosphate (P32) colloidal suspension therapy. *Cancer* 1981; 48: 2596.
17. Heiss MM, Strohlein MA, Jager M, Kimmig R, Burges A, Schoberth A, Jauch KW, Schildberg FW, Lindhofer H. Immunotherapy of malignant ascites with trifunctional antibodies. *Int J Cancer.* 2005 Nov 10; 117(3): 435-43.
18. Wu Y, Zhao M, Yang L, Liu J, Wei YQ, Zhao X. Inhibition of malignant ascites with endostatin adenoviral vector: *Sichuan Da Xue Xue Bao Yi Xue Ban.* 2004 May; 35(3): 316-9.
19. Mackey JR, Wood L, Nabholz JM, Jensen J, Venner P. A Phase II Trial of Triamcinolone Hexacetanide for Symptomatic Recurrent Malignant Ascites Pain Relief. *J Pain Symptom Manage.* 2000 Mar; 19(3): 193-9.
20. Cairns W, Malone R. Octreotide as an agent for the relief of malignant ascites in palliative care patients: *Palliat Med.* 1999 Sep; 13(5): 429-30.
21. Spurgeon JM, Cotlar AM. Cytoreductive Surgery in the Management of Malignant Ascites from Adenocarcinoma of Unknown Primary (ACUP). *Current Surgery.* 2005; 62(5): 500-503.
22. LeVeen HH, Wapnick S, Grosberg S, Kinney MJ: Further experience with peritoneo-venous shunt for ascites. *Ann Surg* 1976; 184: 574. 24.
23. Etzion Y, Barski L, Almog Y. Malignant ascites presenting as abdominal compartment syndrome. *Am J Emerg Med.* 2004 Sep; 22(5): 430-1.
24. Makharia GK, Sharma BC, Bhasin DK, Singh K. Spontaneous bacterial peritonitis in a patient with gastric carcinoma: *J Clin Gastroenterol.* 1998 Oct; 27(3): 269-70.
25. Vasseur B, Cadiot G, Zins M, Flejou JF, Belghiti J, Marmuse JP, Vilgrain V, Bernades P, Mignon M, Ruszniewski P. Peritoneal carcinomatosis in patients with digestive endocrine tumors. *Cancer.* 1996 Oct 15; 78(8): 1686-92.
26. Wilailak S, Linasmita V, Srivannaboon S. Malignant ascites in female patients: a seven-year review: *J Med Assoc Thai.* 1999 Jan; 82(1): 15-9.
27. Catton PA, Hartwick RW, Srigley JR. Prostate cancer presenting with malignant ascites: signet-ring cell variant of prostatic adenocarcinoma. *Urology.* 1992 May; 39(5): 495-7.
28. Mackey JR, Venner PM. Malignant ascites: demographics, therapeutic efficacy and predictors of survival. *Can J Oncol.* 1996 Nov; 6(2):474-80.

Author Information

Shantanu Kumar Sahu

Assistant professor, Department of General Surgery, Himalayan Institute of Medical Sciences

R. K. Verma

Associate Professor, Department of General Surgery, Himalayan Institute of Medical Sciences

P. K. Sachan

Professor, Department of General Surgery, Himalayan Institute of Medical Sciences

Dig Vijay Bahl

Professor and HEad, Department of General Surgery, Himalayan Institute of Medical Sciences