Wooden Splinter Dermatitis

M Chen, D Sarma

Citation

M Chen, D Sarma. *Wooden Splinter Dermatitis*. The Internet Journal of Dermatology. 2006 Volume 5 Number 2.

Abstract

A case of a wooden splinter dermatitis occurring in the foot of a 69-year old female is reported. The clinical features, pathology and treatment of this common injury are briefly reviewed.

INTRODUCTION

Wooden splinter is not an uncommon cause of injury to human skin. The toxicity and allergenicity of the splinter [1] together with the introduction of microorganisms or fungi into the open wound [2] may lead to acute inflammation, abscess, foreign body granuloma or even disseminated infection. Without clear clinical history, the lesion can be easily misdiagnosed as wart or even malignancy [3].

CASE REPORT

A 69-year-old white female noticed a small painful nodule on the heel of her left foot. On clinical examination, the nodule measured approximately 1 cm in diameter. The skin surface was uneven but not ulcerated. The patient denied any history of trauma. Clinical impression was “wart”. The patient underwent a wedge excision of the lesion.

Microscopically, the center of the lesion contained a pointed wooden splinter (approximately 0.7 cm in length), with abscess formation and granulomatous reaction in the dermal tissue surrounding the splinter (Figure 1). Special stain (GMS) was negative for fungus. Viral changes were not noted in the epidermis.

Figure 1

Figure 1: Note the pointed wooden splinter in the center of the lesion perforating through the epidermis into the dermis with perisplinter abscess.

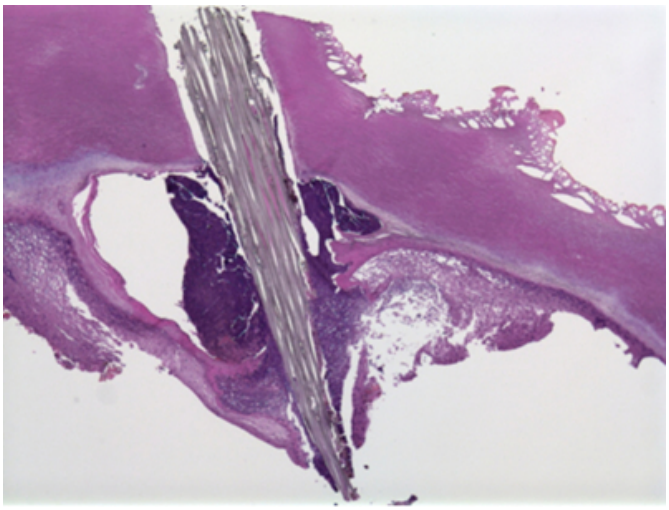

COMMENT

The splinter injuries commonly involve the extremities. The reaction of the skin due to the wooden splinter injury is much more intense than that seen in splinter injuries by inert foreign bodies, such as, glass, metal, and plastic because the wood may release toxic and allergenic substances. The lesion can be further complicated if bacterial or fungal infection occurs. An acute neutrophilic and eosinophilic inflammation with marked edema followed by an abscess formation may follow. A granulomatous inflammation with foreign-body giant cells is seen in older lesion.

A clear history of penetration injury is critical for an accurate diagnosis. On physical, most superficial splinters can be visualized or palpated. However, deep splinters may be problematic. Local sign of inflammation or infection may hint a foreign body in place. Standard radiographs may

detect a radiopaque foreign body [1].

When possible, the wooden splinter should be removed before inflammation or infection occurs. However, the physician must resist the temptation to remove the splinter by simply pulling it out of the wound because this may leave small fragment behind. A superficial horizontal splinter may be lifted with a forcep after an incision along the length of the long axis of the splinter. The vertical splinters may need deeper incisions around the splinters after proper local anesthesia and cleansing. Deeper splinters, especially those close to important structures such as nerves, tendons, blood vessels, or vital organs, should be referred for surgical removal.

CORRESPONDENCE TO

Deba P Sarma, M.D. Department of Pathology Creighton University Medical Center 601 North 30th Street Omaha, NE 68131 Email: debasarma@creighton.edu

References

1. Lammers RL, Magill T. Detection and management of foreign bodies in soft tissue. Emerg Med Clin North Am. 1992; 10:767-81.
2. Mehregan AH, Rudner EJ. Implantation dermatosis. Wood splinter with fungus contamination. J Cutan Pathol. 1980; 7:2.
3. Shah AS, Coldiron BM. Foreign-body granuloma due to an unsuspected wooden thorn. Am Fam Physician. 1992; 45:673-4.

Author Information

Mingkui Chen, M.D., Ph.D.
Department of Pathology, Creighton University Medical Center

Deba P. Sarma, M.D.
Department of Pathology, Creighton University Medical Center