

Cleopatra's Needle Causing Silicone embolism

A Amchentsev, L Irugulapati, N Kurugundla, A Devakonda, L George, S Raoof

Citation

A Amchentsev, L Irugulapati, N Kurugundla, A Devakonda, L George, S Raoof. *Cleopatra's Needle Causing Silicone embolism*. The Internet Journal of Pulmonary Medicine. 2006 Volume 8 Number 1.

Abstract

Silicone is a material with minimal tissue reaction, which is utilized by physicians and illegally by nonmedical personnel. "Cleopatra's Needle", "pumping party" are terms used to describe the liquid silicone injection of breasts in the buxom belles of Hollywood and Las Vegas. Unfortunately, its use is associated with severe adverse effects, including death. This case report describes silicone embolism syndrome in a young female who had subcutaneous liquid silicone injections prior to admission. The patient presented to the hospital with respiratory distress, hemoptysis, and bilateral lower lobe consolidation. During observation we did not find any signs of infection, and all other rare causes were excluded.

ABBREVIATIONS

SES- Silicone embolism syndrome

LSI- Liquid silicone injection

CT- Computerized tomography

INTRODUCTION

Liquid silicone is an inert material that is utilized for cosmetic procedures by physicians and illegally by nonmedical personnel. Silicone is a material with minimal tissue reaction, thermal stability, low surface tension, lack of immunogenicity, and little change in physical property with aging. Silicone molecules have a backbone of silicon attached to carbon and other organic groups.

"Cleopatra's Needle" is a term used to describe the liquid silicone injection (LSI) of breasts in the buxom belles of Hollywood and Las Vegas. Unfortunately, its use is associated with infrequent severe adverse effects, including death.

We describe the case of young girl, working as a photo model presenting with rare pulmonary complication after LSI to buttocks.

CASE DESCRIPTION

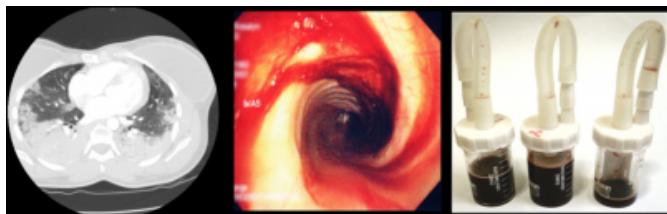
A 24-year-old female with unremarkable medical history was admitted with complaints of worsening dyspnea, pleuritic chest pain, cough with hemoptysis for 6 days. She denied fever, chills, or night sweats. Detailed history revealed that her symptoms started within 30-45 minutes after she received LSI 500ml into each buttock by

unlicensed practitioner. Also she remembered that post injection course was complicated by bleeding from site of injection. On physical exam she was tachypnoeic, in moderate respiratory distress. Lung auscultation revealed rhonchi and decreased breath sounds bilaterally. Her labs were significant for hemoglobin of 8.9 g/dL and blood gas analysis revealed respiratory alkalosis with moderate hypoxemia. Her chest x-ray showed extensive bilateral consolidation in lower lobes.

Computerized tomography (CT) of the chest with contrast showed no evidence of pulmonary embolus but air space consolidation, bilaterally, at the lung bases (Fig. 1A). Extensive series of tests (echo, drug screen, HIV, connective tissue diseases, viral and bacterial cultures) were negative. Bronchoscopy showed presence of blood and was negative for any malignant or infectious etiologies. The bronchoalveolar lavage remained hemorrhagic even after sequential sampling (Fig. 1B and 2C).

Figure 1

Figure 1: A) Computerized tomography of the chest with contrast demonstrating extensive bilateral lower lobes air space consolidation, bilateral breast implants. B) Flexible bronchoscopy view showing presence of the blood in lower lobes bilaterally. C) The bronchoalveolar lavage samples.



Patient was treated symptomatically, and improvement was noticed after 5 days. Repeated CT showed resolution of bilateral consolidation. Patient was discharged, and did not return for follow up.

DISCUSSION

Since the first description of systemic illness with pulmonary involvement following silicone injections (²), only 3 cases have been reported and reviewed in the English language literature (³). It appears to be a serious, potentially life-threatening illness and the pathogenesis of it has not yet been well established.

In pathogenesis of silicone embolism syndrome (SES), the following mechanisms may play role: high local tissue pressure, alveolar hemorrhage, the ingestion of silicone by alveolar macrophages provoking an inflammatory response(⁴), and development of delayed hypersensitivity to silicone(⁵).

Majority of the patients present most frequently with

hypoxemia, dyspnea, fever, alveolar hemorrhage within the first 24 hours of injection. Two clinical patterns were noticed in SES patients: patients who are presenting typically with respiratory distress and mortality close to 7% and the second clinical pattern of severe neurological changes and high mortality rate reaching 100% (³).

Chest CT frequently shows diffuse air-space disease, mostly subleural with foci of ground-glass opacification (⁶).

Finding of silicone particles in the macrophages confirms the diagnosis SES following silicone injection (³).

Spectrophotometry and electron microscopy demonstrates nonstaining globular deposits typical of silicone in the alveolar wall capillaries and within alveolar macrophages. Management mostly supportive and includes rest, high-flow oxygen, although mechanical ventilation is necessary in some cases. Symptoms generally remit without sequelae (³).

This case shows the importance of recognizing silicone embolism syndrome in patients presenting with acute onset of symptoms after illegal silicone injection.

References

1. E. Norling, Cleopatra's Needle, Orange County (Cal.) Bulletin, October, 1968.
2. Ellenbogen R, Ellenbogen B, Rubin L: Injectable fluid silicone therapy. Human morbidity and mortality. JAMA 1975; 234:308-309.
3. Schmid A, Tzur A, Leshko L, Krieger BP. Silicone embolism syndrome: a case report, review of the literature, and comparison with fat embolism syndrome. 2005; 127(6):2276-81.
4. Chastre J, Brun P, Soler P, Basset F, Trouillet JL, Fagon JY, et al. Acute and latent pneumonitis after subcutaneous injections of silicone in transsexual men. Am Rev Respir Dis. 1987; 135(1):236-40.
5. Narini PP, Semple JL, Hay JB. Repeated Exposure to Silicone Gel Can Induce Delayed Hypersensitivity. Plast Reconstr Surg. 1995; 96(2):371-80.

Author Information

Alexey Amchentsev, M.D.

New York Methodist Hospital

Lavanya Irugulapati, M.D.

New York Methodist Hospital

Navatha Kurugundla, M.D.

New York Methodist Hospital

Arun Devakonda, M.D.

New York Methodist Hospital

Liziamma George, M.D.

New York Methodist Hospital

Suhail Raoof, M.D.

New York Methodist Hospital