

# Proposed Otoplasty Model: Innovative Use for a Hearing Aid Demonstration Mould

L Wu, K Pang, Y Ng, S Yeak

## Citation

L Wu, K Pang, Y Ng, S Yeak. *Proposed Otoplasty Model: Innovative Use for a Hearing Aid Demonstration Mould*. The Internet Journal of Plastic Surgery. 2006 Volume 3 Number 1.

## Abstract

Prominent ear is a cosmetic deformity that can have severe emotional and behavioural effect on a child. Otoplasty describes the surgical procedures designed to give the auricle a more natural and anatomic appearance. Otoplasty can be categorized as either cartilage splitting (cutting) or cartilage scoring. Cartilage-splitting involve full-thickness incisions through the cartilage and repositioning of large blocks of auricular cartilage. Cartilage-scoring such as Stentrom's scoring techniques involves making partial-thickness incisions, while attempting to avoid sharp angulations and to re-produce smooth curves in the cartilage. Our proposed otoplasty model is based on modifications of an existing hearing aid model which is readily available in our clinic. The modified ear moulds allow residents to practise on ear cartilage moulding techniques before operating on patients.

## TECHNIQUE

Prominauris, the most common malformation of the external ear, is a combination of defects affecting mainly the antihelix and the concha. Otoplasty is a rewarding surgery that requires skill and judgment in handling the interaction between auricular skin, cartilage and fascia. There is usually little time for the trainee to be taken through a clinical case as most otoplasty are performed under local anaesthesia. In addition, there are more than 200 different techniques described since the first otoplasty technique described by Ely<sub>1</sub> in 1881, making it difficult to perfect the various techniques. We hereby propose a simple, realistic and cost-effective training model based on modifications of a silicon ear mould provided by hearing aid company (Siemens) to allow trainee surgeons to practice their techniques.

The ear mould is normally available for the audiologists to demonstrate wearing hearing aids on the hearing impaired patients. We have modified the ear mould to approximate the deformity of a bat ear and subsequently mounted the ear model on a Plasticine® block. The main pathologic characteristic of the prominent ear deformity are (1) absent anti-helical fold and (2) a conchoscaphal angle of more than 90 degrees<sub>2</sub>. In order to replicate the absent anti-helical fold, the original anti-helical fold on the model is shaved off to emulate the effaced anti-helix. This facilitates the use of horizontal mattress sutures (conchoscaphal) to re-create the anti-helical fold. The ear model also allows the practice of

the Stentrom's technique of scoring the anterior surface to weaken the cartilage over the proposed site of anti-helix crest<sub>3,4</sub>.

In order to simulate the correction of the concho-scapoid angle, excess silicon is shaved off from the mould's posterior surface to increase the concho-scapoid angle to more than 60 degrees. In addition, the plasticine block is wrapped with a defibrillator pad to replicate the fascia/periosteum of mastoid process. This allows the use of 3/0 prolene sutures to anchor the posterior conchal wall to the mastoid prominence, thus reducing the conchal projection<sub>5</sub>.


The use of ear model designed for hearing aid demonstration has numerous advantages compared with existing otoplasty models. The ear models are usually complimentary from hearing aid companies for demonstration purposes to patients. In addition, the silicon ear models approximates the consistency of the ear cartilage, hence allowing different cartilage modifications techniques to be practiced on. Finally, the ear model is an exact replica of the ear as compared with other proposed animal models such as pig ears. As most otoplasty are performed under local anaesthesia, the use of ear replica allows the trainee to be familiar auricular anatomy prior to surgery. This is advantageous as this minimises teaching intra-operatively and hence allaying anxiety of the patient that he is being operated on by a novice.

The main disadvantage of the ear replica as compared with the use of animal models by Rohrich<sub>6</sub> is however, the lack of a soft tissue envelope, which allows the practice of dissecting the auricular skin flap.

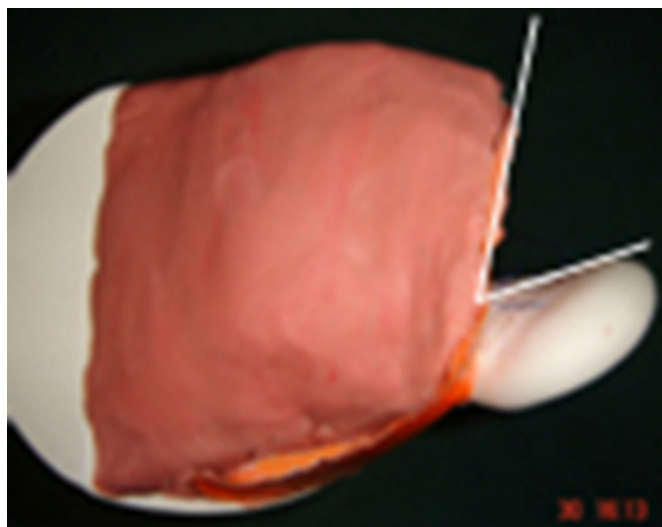
**Figure 1**



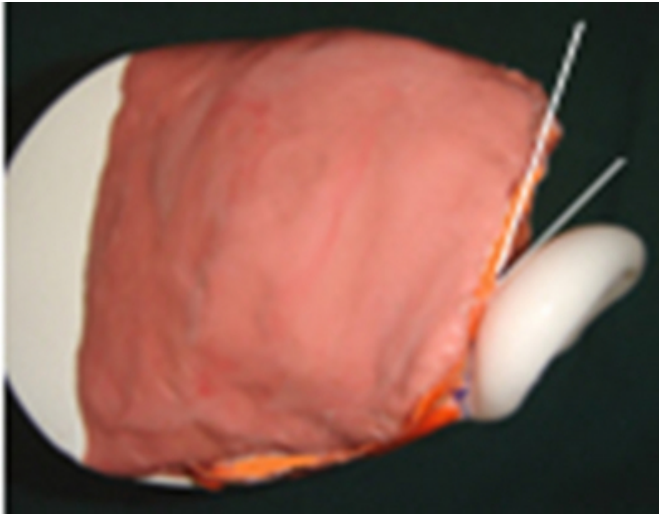
**Figure 2**



**Figure 3**



**Figure 4**



In conclusion, we proposed an otoplasty model based on modifications of silicon replica of the ear for hearing aid demonstration. We believe that this model is useful for trainee to practice various otoplasty techniques prior to their first otoplasty.

## **CORRESPONDING AUTHOR**

Dr Larry Wu Address: Department of Otolaryngology Tan Tock Seng Hospital 11, Jalan Tan Tock Seng Singapore 308433 Telephone: +65-63577742 Fax: +65-63578676 Email: larrydr@gmail.com

## **References**

1. Rogers BO., Ely's 1881 operation for correction of protruding ears. A medical "first"., *Plast Reconstr Surg.*, 1968 Dec;42(6):584-6.
2. *Plastic Surgery*, Grabb and Smith's 1997 Chapter 36. pg 431 to 438
3. Stenstrom SJ, Heftner J. , The Stenstrom otoplasty., *Clin Plast Surg.* 1978 Jul;5(3):465-70.
4. Mustarde JC. Correction of prominent ears using buried mattress sutures. *Clin Plast Surg.*, 1978 Jul;5(3):459-64.
5. Yugueros P, Friedland JA. Otoplasty: the experience of 100 consecutive patients., *Plast Reconstr Surg.* 2001 Sep 15;108(4):1045-51; discussion 1052-3.
6. Rohrich RJ, Friedman RM, Liland DL., Comparison of otoplasty techniques in the rabbit model., *Ann Plast Surg.* 1995 Jan; 34(1):43-7.

**Author Information**

**L. H. C. Wu, MBBS, MRCS(Edin) MMED(Sing)**

Medical Officer, Department of Otolaryngology(ENT), Tan Tock Hospital

**Kenny Peter Pang, MBBS, MRCSEd, FRCSEd, MMed(ORL), FRCSi(OTO), FAMS(ORL), FAASM(USA)**

Consultant ENT Surgeon, Clinical Teacher, Department of Otolaryngology, Tan Tock Hospital

**Y. H. Ng, MBBS, MRCS(Edin)**

Medical Officer, Department of Otolaryngology(ENT), Tan Tock Hospital

**Samuel C.L. Yeak, MBBS, FRCSEd, FRCSGlasg, FAMS(ORL)**

Senior Consultant ENT Surgeon, Senior Clinical Lecturer, Department of Otolaryngology, Tan Tock Hospital