

# Mucosal reduction for correction of congenital maxillary double lip.

C Amine, O Aya, R Mohamed, O abdelatif, E Nouredine

## Citation

C Amine, O Aya, R Mohamed, O abdelatif, E Nouredine. *Mucosal reduction for correction of congenital maxillary double lip.* The Internet Journal of Plastic Surgery. 2008 Volume 6 Number 2.

## Abstract

Congenital double lip is rare and usually involves the upper lip. A part from a deformity that interferes with speech and mastication, operation may be indicated for cosmetic reasons. We report a case of 12 years old patient with double lip deformities who was operated in our department for cosmetic reasons. We used an elliptical excision of the mucosal excess. Satisfactory aesthetic results were achieved.

## INTRODUCTION

Congenital double lip is rare and generally involves the upper lip (1). A double vermilion with a transverse furrow between the two borders appears when the orbicularis oris muscle

contracts during a smile. The incidence of this anomaly is not known and it may be either isolated or in association with other congenital abnormalities. (2) Treatment is by excision of the excess mucosa and submucosal tissue. We present a case of congenital double lip with literature review.

## CASE REPORT

A 13-year-old boy was evaluated for excess maxillary labial mucosa with the resulting appearance of a maxillary double lip (Fig. 1). The deformities had been present since birth and became more prominent as he grew. No other congenital deformities were noted.

The appearance of the lip was due to folding of the mucosa as the lip was retracted when smiling (Fig. 2). The excess labial mucosa was localized to either side of the midline (Fig. 3), forming a sessile, hypertrophied mass that extended mediolaterally the distance between the midpoints of the maxillary lateral incisors.

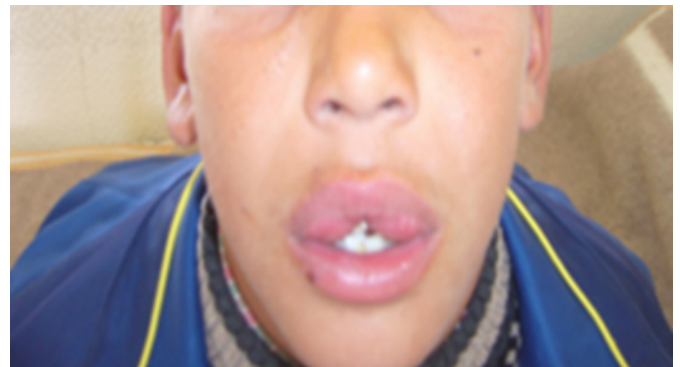We operated under general anaesthesia. The excess buccal mucosa was excised by two elliptical excisions, one on each half of the lip, and combined with a central Z-plasty to release the constricting band (Fig. 4). Closure was by running 4/0 polyglactin 910 (Vicryl) suture (Fig. 5). Postoperative recovery was uneventful apart from swelling

that resolved in about 10 days.

He was happy with the cosmetic results. After two years there were no signs of relapse or late complications.

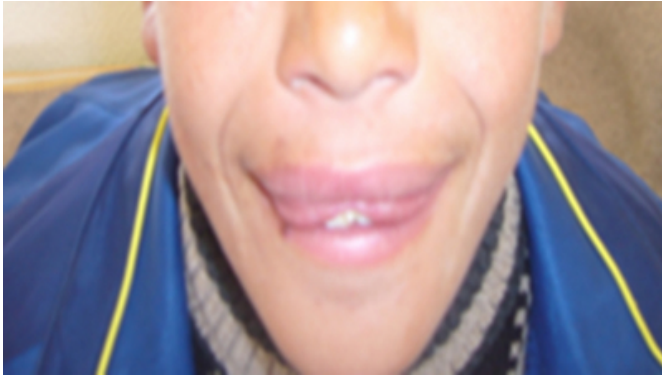
## Figure 1

Fig.1: The upper lip when the mouth is open; note the short central constriction and mucosal bulging on both sides



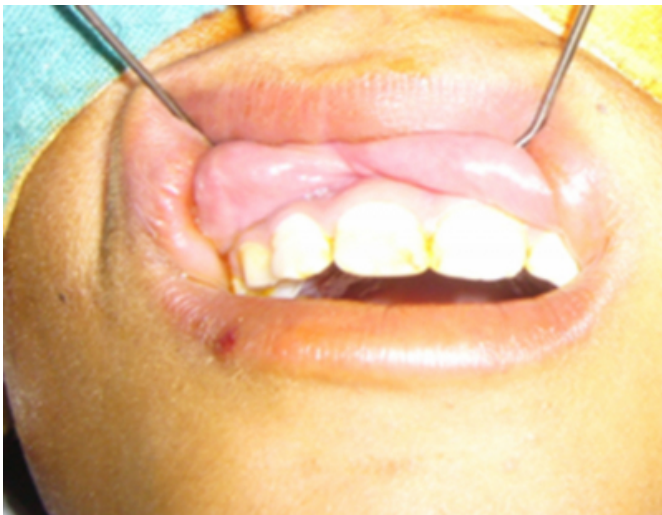**Figure 2**

Fig.2: Double lip deformity when the patient smiles



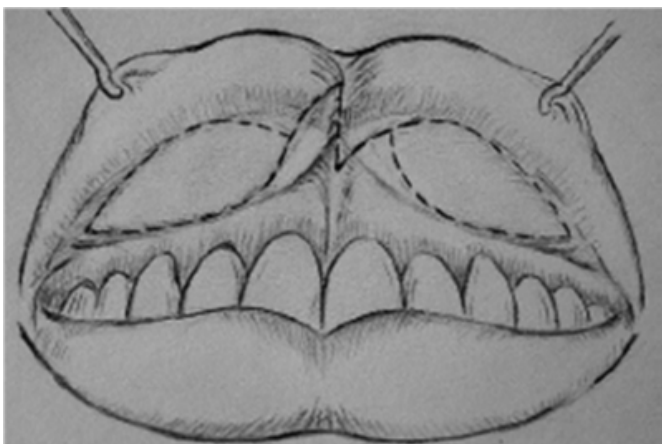**Figure 3**

Fig.3: The excess labial mucosa was localized to either side of the midline



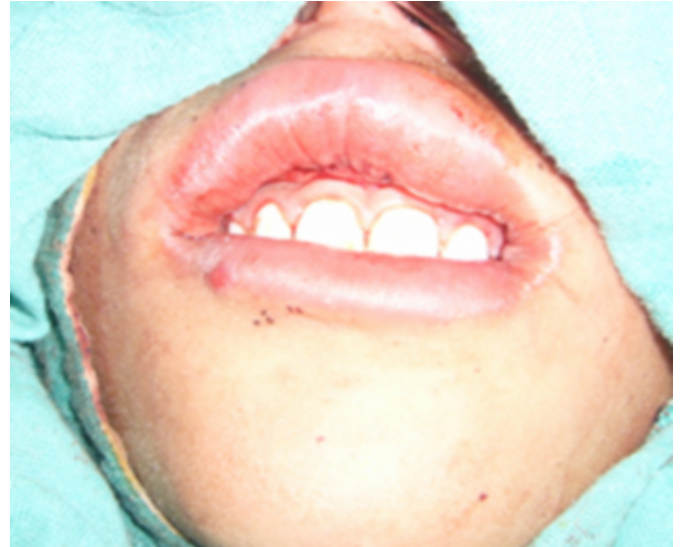**Figure 4**

Fig.4: Diagram of the Z-plasty with two elliptical excisions



**Figure 5**

Fig.5: Appearance of the lip at the end of operation



## **DISCUSSION**

Double lip (DL) may be either a congenital abnormality or an acquired deformity. The congenital form usually involves the upper lip, but it may also affect the lower lip. (3, 4)

It usually occurs as a redundant fold of tissue on the mucosal part of the lip. During the development of the mucosa, the upper lip consists of two transverse zones viz, an outer zone, which is smooth and similar to the skin called the pars glabrosa and the inner zone, which is villous and similar to the oral mucosa, termed as the pars villosa (5). The DL develops during the second or third intrauterine month as a result of the persistence of the horizontal sulcus between the pars glabrosa and the pars villosa. (5, 6) Acquired double lip deformity can occur after an injury, in association with Ascher syndrome, or as a result of habitual pulling of the mucosa through a diastema (1).

Differential diagnosis of double lip include hemangioma, lymphangioma, angioedema, cheilitis glandularis and cheilitis granulomatosis (6).

Various operations to correct a double lip have been described. Guerrero-Santos and Altamirano described the use of a W-plasty (7). Simple excision through an elliptical incision was advocated by Reddy and Kotewara (8). In patients with a short central constriction band as our case, the use of two elliptical incisions combined with a vertical Z-plasty result in a pleasing appearance of the upper lip with a natural-looking tubercle (9).

The postoperative swelling can need about 10 days to be

resolved (9). The cosmetic results are generally very good and make psychic satisfaction. The relapse and complications such as glandular hypertrophy or mucocele are extremely rare.

## **CONCLUSION**

Congenital double lip is a rare oral anomaly. Surgical treatment is indicated when the excess tissue interferes with mastication or speech or more often for esthetic reasons. The results are generally very good and complications are extremely rare

## **References**

1. Alkan A, Metin M. Maxillary double lip: report of two cases. *J Oral Sci* 2001;43:69–72.
2. Calnan J. Congenital double lip: a report of a case with note on embryology. *Br J Plast Surg* 1952;5:197–200.
3. Converse JM, Wood-Smith D, Macomber WB, Wang MKH. *Reconstructive plastic surgery*. 2nd ed. Philadelphia Saunders; 1977: 1543.
4. Reddy KA, Kotewara A. Congenital double lip: a review of seven cases. *Plast Reconstr Surg* 1989;84:420–3.
5. Kara IG, Kara CO. Ascher syndrome, *Otolaryngol Head Neck Surg*, 2001,124: 236-7.
6. Chidzonga MM, Mahomva L. Congenital double lower lip: Report of a case, *Int J Paediatr Dent* 2006, 16: 448-9.
7. Guerrero-Santos J, Altamirano JT. The use of W-plasty for the correction of double-lip deformity. *Plast Reconstr Surg* 1967;39:478–81.
8. Reddy KA, Kotewara A. Congenital double lip: a review of seven cases. *Plast Reconstr Surg* 1989;84:420–3.
9. Muhitdin Eski , Mustafa Nisanci , Alper Aktas , Mustafa Sengezer *British Journal of Oral and Maxillofacial Surgery* 2007,45: 68–70.

**Author Information**

**Cherkaoui Amine**

Senior resident, Department of Otolaryngology-Head and Neck and plastic Surgery Hassan II, University Hospital, Fès, Morocco.

**Oufkir Aya**

Assistant Professor, Department of Otolaryngology-Head and Neck and plastic Surgery Hassan II, University Hospital, Fès, Morocco.

**Ridal Mohamed**

Assistant Professor, Department of Otolaryngology-Head and Neck and plastic Surgery Hassan II, University Hospital, Fès, Morocco.

**Oudidi abdelatif**

Professor, Department of Otolaryngology-Head and Neck and plastic Surgery Hassan II, University Hospital, Fès, Morocco.

**El alami Nouredine**

Professor, Department of Otolaryngology-Head and Neck and plastic Surgery Hassan II, University Hospital, Fès, Morocco