

Congenital Idiopathic Chylothorax In A Jamaican Neonate: Management Challenges

O Aworanti

Citation

O Aworanti. *Congenital Idiopathic Chylothorax In A Jamaican Neonate: Management Challenges*. The Internet Journal of Pediatrics and Neonatology. 2008 Volume 10 Number 1.

Abstract

Congenital idiopathic chylothorax is the accumulation of chylous fluid in the pleural space. Typically occurs in the late third trimester and possible explanations are malformation and leakage from the thoracic duct. We report an index case in a Jamaican neonate diagnosed with polyhydramnios and bilateral pleural effusions by routine sonography at 34 weeks gestational age. Antenatal diagnostic work up done aimed to exclude hydrops fetalis and its numerous aetiologies. We highlight our limitations. At birth elective mechanical ventilation was essential and bilateral thoracostomy tubes placed were both diagnostic and therapeutic. The infant received a specialized diet exclusively for 8 weeks and regular feeds were tolerated at 8 weeks. The rarity of this condition, diagnostic limitations such as ready availability of karyotyping, limited facilities for antenatal intervention may present surmountable management challenges.

INTRODUCTION

Chylothorax is the presence of chyle in the pleural space due to leakage from the thoracic duct or one of its main tributaries.¹ It may be idiopathic or acquired.

Acquired causes are due to malignant aetiologies or occurring after trauma usually from thoracic operations.¹ The congenital form is usually of unknown aetiology but may be due to thoracic duct malformation associated with dysmorphic syndromes¹²³⁴.

Pisek reported the first case of congenital chylothorax in 1917².

The incidence in Jamaica is unknown. The incidence world wide is 1 per 15000 and the male female ratio is 2:1³.

The management may be surgical or conservative. In 80% of cases chylous effusions resolved with dietary modifications and continuous chest tube drainage within 4-6 weeks³⁶.

We report an index case in a Jamaican neonate highlighting those challenges faced in the antenatal period and subsequent postnatal management.

CASE REPORT

A 42 year old gravida 8 para 9 + 0 rhesus positive mother was referred to the pediatric Surgery unit at Cornwall Regional Hospital at 35 weeks gestational age for non

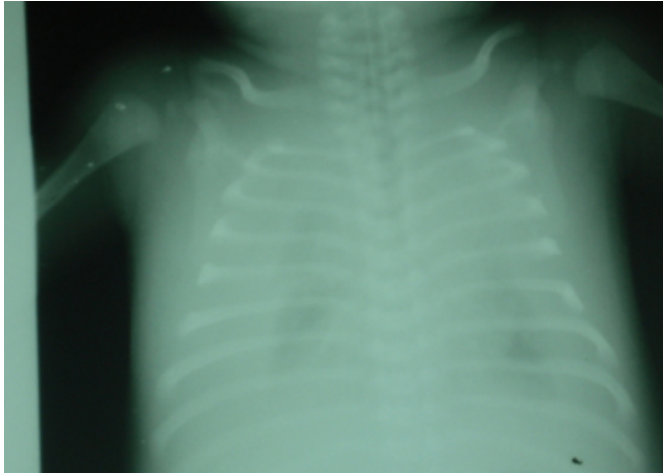
immune hydrops. She presented at 34 weeks gestation age (GA) for routine antenatal follow up and was found to have a symphysio-fundal height of 37cm. Her booking parameters were normal and 20 week abdominal ultrasonography was normal. A repeat abdominal ultrasonography revealed polyhydramnios and bilateral pleural effusions in the fetus.

Amniocentesis done revealed normal levels of bilirubin. The mother received 6mg dexamethasone intramuscularly twice daily for 2 days. Fetal monitoring was done using biophysical profiles and daily kick charts.

At 37 weeks GA a 3.6 kg O +ve male neonate with no dysmorphic features was born via elective lower segment cesarean section. APGARS at 1 and 5 minutes were 4 and 5 and mechanical ventilatory support was commenced. Chest radiography showed massive bilateral pleural effusion (figure 1).

Figure 1

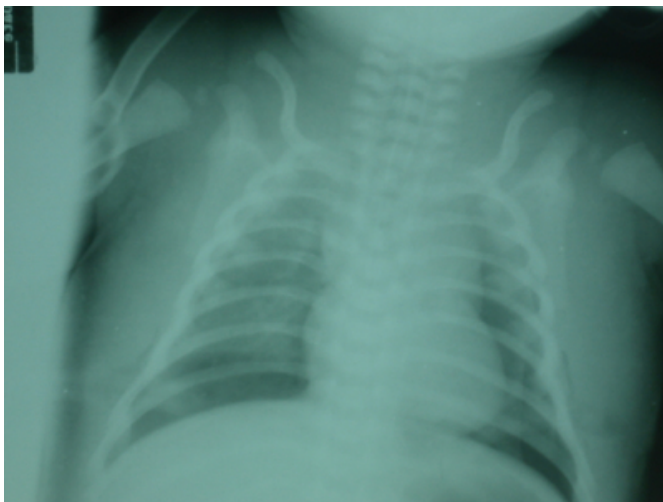
Figure 1



Bibasilar thoracostomy tubes were placed and each drained 200mls serous fluid initially. Ventilator settings improved and repeat chest radiography showed adequate lung expansion . (Figure 2).

Figure 2

Figure 2



Abdominal ultrasonography showed mild hepatomegaly and minimal ascitis. Cranial ultrasonography and cardiac echocardiography were normal. Initial diagnoses of non-immune hydrops fetalis possibly due to an infective cause and pulmonary hypoplasia were made.

Hemoglobin concentration, white cell count and platelet levels were normal and the direct coombs test was negative. Serum biochemistry and liver function tests were normal (total protein 43g/l, albumin 29g/l). TORCH screen was negative and VDRL was non-reactive.

The neonate received a therapeutic course of broad spectrum

antibiotics and chest physiotherapy was instituted.

The day 1 pleural fluid chemistry showed a triglyceride level of 1 mmol/l, specific gravity of 1010 , red cell count of 2620/mm³ and white cell count of 1620/mm³ with > 90 % lymphocytes. Pleural fluid total protein was 38g/l , albumin 25g/l, LDH 148 IU/l, glucose 4.6 mmol/l and gram stain and cultures were negative. Daily bilateral chest tube drainage averaged 100mls from each side.

With improved ventilator settings feeding was commenced on day 3 via naso- gastric tube and on day 4 the pleural fluid turned milky in appearance. A repeat pleural fluid analysis showed a triglyceride level > 4.18mmol/l and specific gravity of 1015 now diagnostic for congenital idiopathic chylothorax. Medium chain triglyceride feeds were tolerated and intravenous albumin given as required.

Ventilator support was discontinued on day 11 after gradual weaning and prompted by self endotracheal extubation by the patient. Left pleural effusion resolved on day 14 and right on day 21. Patient went home on strictly medium chain triglyceride feeds on day 30.

He was readmitted at 2 months and introduced to regular infant formula. Patient was monitored for clinico-radiological evidence of recurrent chylothorax. Chest radiographs were normal and feeds were tolerated well.

Patient is now a year old and has no respiratory symptoms. However he has global developmental delays which are currently being investigated.

DISCUSSION

Congenital idiopathic chylothorax is the commonest cause of isolated pleural effusion in newborns ³⁶⁷. Occasionally congenital chylothorax coexists with polyhydramnios and fluid in other fetal compartments ³. With fluid in other compartments the diagnosis of hydrops fetalis must be excluded.

The incidence in Jamaica is unknown and there is no previous report of this condition from Jamaica. The worldwide incidence is 1: 15000 births ³. With increasing antenatal diagnoses by ultrasonography this incidence may rise in years to come.

The definitive aetiology is debatable but suggested aetiologies include:

Congenital malformation in thoracic lymphatics ³⁴,

lymphangiomatosis₃ and lymphatic dysplasia associated with dysmorphic syndromes such as Noonan syndrome, Turners syndrome and Down's syndrome₃₅.

From our literature review most cases of congenital idiopathic chylothorax manifest in the late third trimester and the neonates are usually symptomatic at birth. Occasionally symptoms begin in the first week of life₃. The condition commonly presents as a large for date mother and a third trimester ultrasonography confirming fetal pleural effusion.

Determining the cause of hydrothoraces antenatally is often a diagnostic dilemma. Hydrops fetalis, the most common differential, is the abnormal accumulation of fluid in 2 or more fetal compartments such as ascites, pleural effusion, pericardial effusion, and skin edema₉. It may be due to immune causes like rhesus blood group isoimmunization of the fetus and less commonly ABO, Kell, Duffy blood group incompatibility. Non immune causes include haematological (non immune haemolytic disorders, disorders of red cell production and fetal haemorrhage), cardiac (structural and non structural anomalies), infectious (TORCHES), inborn errors of metabolism (glycogen storage disease, lysosomal storage disease, hypothyroidism and hyperthyroidism), genetic syndromes (Noonan syndrome, myotonic dystrophy), chromosomal syndromes (trisomies 10;13;15;21, Turner's syndrome).

Diagnostic workup in a neonate presenting with chylothorax would be maternal, fetal, and neonatal. The aim is to exclude other causes of hydrothoraces.

Maternal infection screening and blood group determination should be available from the time of booking. Further antibody screens and syphilis serology is done.

Amniocentesis is done to

Measure bilirubin levels as was done in the case described above. This excludes haemolytic causes of hydrops and is a sensitive predictor to the severity of fetal anaemia in cases of isoimmunization.

Karyotyping which was not readily available at our institution should also be done to diagnose associated chromosomal anomalies.

Amniotic fluid enzyme assays and measurement of specific metabolites. Due to the rarity of inborn errors of metabolism in this population obtaining these assays proved also to be a

challenge.

Cordocentesis if done is indicated for serological tests for specific infections, haemoglobin levels, blood grouping, fetal transfusion and DNA analysis. In utero analyses of serous effusion fluids (pleural, pericardial, or ascitic) have been of surprisingly little value. Lymphocyte counts considered characteristic of congenital chylothorax when found in the newborn infant have been observed in pleural effusions from fetuses with CMV disease₉.

Facilities for measurements of intrapleural pressures and pleuroamniotic shunting are at infancy at our institution, however monitoring of this fetus by daily biophysical profiles, and regular fetal heart rate and kick charts monitoring proved sufficient in this case.

The diagnosis of chylothorax is confirmed postnatally by laboratory investigations specifically pleural fluid assays. Pleural fluid containing >1.1 mmol/l triglycerides (with oral fat intake) and has a total cell count of > 1000 cells/μL, with a lymphocyte fraction > 80%, a specific gravity of >1.012 and elevated protein and albumin levels is diagnostic₃₄₁₀.

Neonatal imaging such as echocardiography, abdominal and cranial ultrasonography is done to exclude other causes including hydrops fetalis. Chest radiography confirms pleural fluid.

Despite the inexhaustible possibilities and limited screening tools we concluded based on the data gathered and clinical progress that the case presented above was an idiopathic chylothorax with no associated anomalies.

The management may be commenced either antenatally or postnatally.

Antenatal management is by thoracocenteses or pleuro-amniotic shunting. The aims of antenatal management is to

Reduce the complication of pulmonary hypoplasia.

Prevent the development of hydrops fetalis which may result from raised intrathoracic pressures causing reduced caval vein flow to the heart₁₁.

Reduce the need for post natal mechanical ventilation.

The indication for pleuro-amniotic shunting is ultrasonographic signs of elevated thoracic pressures (mediastinal shift and / or inversion of the diaphragm) corroborated with direct measurement of thoracic pressure(

pressures at or above 39mmHg are abnormal) ¹¹ .

Successful outcome of shunting procedures in idiopathic chylothorax approach 80-100% with failures due to blockage or incorrect placement of shunts ¹¹. However with associated hydrops fetalis failure rates range between 40- 50 % ^{11,12}.

Postnatal management is either conservative or surgical.

Conservative management is by mechanical ventilation, continuous thoracostomy tube drainage or repeated thoracentesis, dietary modification with medium chain triglyceride diet or total parenteral nutrition and management of any underlying disease ^{34,5678}.

Fat provides about half of the energy source (calories) in human breast milk, mostly as long-chain fatty acid triglycerides. Medium chain triglycerides (obtained largely from coconut oil) contain 6-12 carbon fatty acids. They are absorbed directly into the portal circulation and transported to the liver for rapid oxidation and are more accessible by preterm infants with immature digestive systems. On the other hand long chain triglycerides have fatty acids of > 12 carbon atoms, are transported via chylomicrons into the lymphatic system and are important in the development of the retina, visual acuity and cell membranes in the brain ¹³¹⁴.

The use of medium chain triglycerides which bypass the lymphatic system cuts down leakage from abnormal lymphatics. Commercially available formulas include Pregestimil Lipil ® and ProViMin ®.

The use of continuous infusion of somatostatin has been shown to be therapeutic ¹⁵.

Successful chemical pleurodesis with different agents including povidone-iodine has been reported ⁶.

Surgical interventions to be considered 4-6 weeks post failure of conservative management include thoracoscopic pleurodesis, pleuro-peritoneal shunting and ligation of thoracic duct via thoracoscopy or thoracotomy ³⁴⁶.

Complications include malnutrition, thrombosis, nosocomial infections due to lymphopenia, hypoproteinemia and immunoglobulin deficits and complications due to non-surgical and surgical interventions.

The prognosis is good. The perinatal mortality rate in Jamaica is unknown. Probably 15-30% worldwide and increases significantly with prematurity, lung hypoplasia and associated hydrops fetalis ³⁶ .

CONCLUSION

There are several interventions available in the management of congenital idiopathic chylothorax. Proper antenatal care and screening, veracious diagnosis and timely intervention are essential to a good outcome.

In our setting the rarity of this condition, diagnostic limitations such as non availability of karyotyping, limited facilities for measurement of intrapleural pressures and shortages of specialized infant formulas required may present surmountable management challenges.

ACKNOWLEDGEMENTS

I wish to thank Dr Garfield Badal (DM Pediatric surgery) and Dr Christopher Valentine(DM General surgery) for their guidance in preparing this paper.

References

1. Hillerdal G. Chylothorax and pseudochylothorax. *Eur Respir J*. May 1997; 10(5):1157-62.
2. Pisek GR. Report of a case of Chylothorax. *Arch Pediatr* 1917; 34: 929.
3. Koksall N, Demir S, Okan M, Gebitekin C, Senkaya I. Congenital Chylothorax. *Turk J Med Sci* 2000; 30: 307-309.
4. Vera B, Sergio F, Rene B, Chylothorax in children, guidelines for diagnosis and management. *American College of Chest Physicians* 1999; 116: 682-687.
5. Rajniti P, Kuldeep S, Rupa S. Bilateral Congenital Chylothorax with Noonan Syndrome . *Indian Pediatrics* 2002; 39:975-976.
6. Brissaud O, Desfrere L, Mohsen R, Fayon M, Demarquez J L . Congenital Idiopathic Chylothorax in neonates: chemical pleurodesis with povidone-iodine (Betadine). *Archives of Disease in Childhood Fetal and Neonatal* Edition 2003; 88:F531.
7. Al-Tawil K, Ahmed G, Al-Hathal M . Congenital chylothorax. *Am J Perinatol* 2000; 17:121-6.
8. Van Straaten HL, Gerards LJ, Krediet TG . Chylothorax in the neonatal period. *Eur J Pediatr* 1993; 152: 2-5.
9. Ashraf H Hamdan ,George Cassady . Hydrops Fetalis. <http://www.emedicine.com/ped/topic1042.htm>.
10. Chandra K, Randall D. C. Neonatal Pleural Effusion. *Archives of Pathology and Laboratory Medicine* 2005 ; 130:22-23.
11. Masami Y, Alvaro I, Jorge C, Luis A. C., Enrique P, Yves V. Intrathoracic Pressure in Congenital Chylothorax: Keystone for the Rationale of Thoracoamniotic Shunting? *Fetal Diagnosis and Therapy* 2007;22:169-171.
12. Picone O, Benachi A, Mandelbrot L, Ruano R, Dumez Y, Dommergues M. Thoracoamniotic Shunting for Fetal Pleural Effusions With Hydrops. *American Journal of Obstetrics and Gynaecology* 2004; 191(6):2047-50
13. Klenoff-Brumberg HL, Genen LH. High versus low medium chain triglyceride content of formula for promoting short term growth of preterm infants. http://www.nichd.nih.gov/COCHRANE/KlenoffBrumberg/KLENOFF_BRUMBERG.HTM.
14. Marie-Pierre St-Onge ,Peter J. H. Jones. Physiological Effects of Medium-Chain Triglycerides: Potential Agents in the Prevention of Obesity, *The American Society for Nutritional Sciences Journal of Nutrition* 2002; 132:329-332.

15. Buettiker V, Hug MI, Burger R, Baenziger O.
Somatostatin: a new therapeutic option for the treatment of

chylothorax. Intensive Care Med 2001 jun;27(6):1083-6.

Author Information

Olugbenga Michael Aworanti, MBBS

Junior Resident, Department of Surgery, Subsection of Pediatric Surgery, Cornwall Regional Hospital