

Profunda femoris injury following dynamic screw fixation of intertrochanteric hip fracture

P Mukherjee, V Ladwa, M Hockings

Citation

P Mukherjee, V Ladwa, M Hockings. *Profunda femoris injury following dynamic screw fixation of intertrochanteric hip fracture*. The Internet Journal of Orthopedic Surgery. 2007 Volume 9 Number 1.

Abstract

Dynamic hip screw fixation (DHS) is one of the most common operations carried for neck of femur fracture. Iatrogenic arterial injuries secondary to the procedure is very rare, and are usually secondary to the drill, tap, screw, traction, and retractors^{1, 2, 3}. The most commonly reported vascular complication is a false aneurysm of the profunda femoris artery^{1, 5}. We share our experience of managing iatrogenic injury to the profunda femoris artery following DHS fixation of an inter-trochanteric femoral neck fracture.

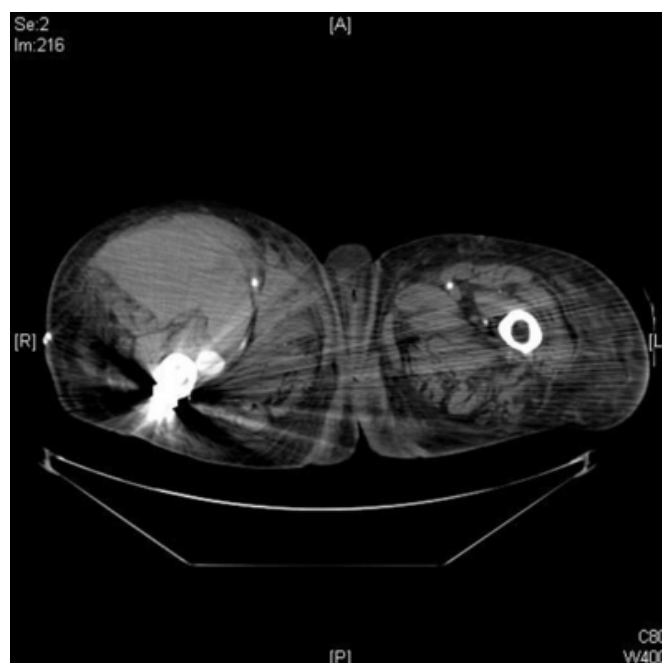
CASE REPORT

A fit 80 years old woman was admitted with a closed intertrochanteric femoral neck fracture. On admission, she was cardio-vascularly stable, her injured leg was short and externally rotated, distal pulses were present and equal in both legs and capillary refill was within normal limits. Haematological and serological examination of the blood did not reveal any abnormality. She was taken to operating theatre on day three of admission. On table, a gentle traction, internal rotation was applied to reduce the fracture to an acceptable position, and she underwent a four hole 135 degree DHS fixation. Post-operatively she did not have any complaints, although a swelling of thigh on the operated side was noticed, which was initially thought to be secondary to the surgery. She needed post-operative blood transfusion as her haemoglobin level was low (8.1 gm/l). During her immediate post-operative period, she maintained her blood pressure around 95-105/55-65 mm of Hg. On third post-operative day, she became more hypotensive (65-85/40-50 mm of Hg), her thigh swelling, which was mainly on the antero-medial aspect, was noted to have increased considerably, she complained of pain in her thigh, her haemoglobin level dropped for which she received repeated blood transfusion, and also she developed signs of acute renal failure. The distal pulses were equal on both the legs, the capillary refill on the operated legs was within normal limits, and she had early signs of compartment syndrome. At this time, we decided to investigate the thigh swelling further, and an urgent CT angiogram was requested following consultation with the vascular surgeon. The CT

angiogram revealed an active bleeding site at the level of the third screw of the DHS, and a massive haematoma in the thigh (Fig. 1).

Figure 1

Figure 1



An emergency exploration by the vascular surgical team revealed a circular laceration on the lateral aspect of the profunda femoris artery, for which the vessel was completely tied off, and the haematoma was evacuated. The screw tip was not protruding into the arterial defect, so it was concluded that the arterial injury was secondary to the drill

or the tap of the DHS. Following the surgery, the patient was admitted to the intensive care unit for observation for two days and then was transferred back to the ward. Henceforth she made an un-eventful recovery, and was discharged to a peripheral hospital for rehabilitation. She was admitted a few weeks later with a similar swelling at the operated thigh. Ultrasound scan showed the swelling to be a liquefied haematoma, and no action was taken.

Since then she made an uneventful recovery.

DISCUSSION

Dynamic hip screw fixation is one of the most commonly performed hip operations. Although vascular injuries secondary to DHS are exceedingly rare but are well known entities. A few case reports have described this injury secondary to excessive traction, fracture clamp, drill bit, screw tap, and displaced fracture fragment^{1,2,3}. This injury can be seen with both short IM nail and DHS fixation for the intertrochanteric hip fracture¹. A high degree of suspicion is needed to diagnose this complication.

Post-operative thigh swelling is very common but it is usually confined to the lateral aspect of the thigh. If a patient develops cardio-vascular instability post-operatively and an excessive swelling on the antero-medial aspect of the operative thigh is noted, an injury to profunda femoris artery should be suspected and investigated appropriately. An early consultation with the vascular surgeon, and CT angiogram

should be arranged.

The profunda femoris artery comes in closed contact with the medial shaft of femur when the leg is in internal rotation and adduction to aid fracture reduction⁴.

Injury to the profunda femoris artery can be avoided by gentle traction manoeuvres, cessation of drilling as soon as the far cortex is breached, using hand tap as opposed to power tap, especially when the leg is adducted and internally rotated.

CORRESPONDENCE TO

Mr. Pavel Mukherjee MRCS Senior SHO Department of Trauma and Orthopaedics Torbay Hospital Torquay Devon UK TQ2 7AA Email: pavelmukherjee@gmail.com

References

1. Karanikas I, Lazarides M, Arvanitis D, Papayanopoulos G, Exarchou E, Dayantas J. Iatrogenic arterial trauma associated with hip fracture surgery. *Acta Chir Belg.* 1993 Nov-Dec; 93(6):284-6.
2. Keel JD, Eyres KS. Vascular injury by an intertrochanteric fracture fragment. *Injury.* 1993; 24:350 -2.
3. Bansal R, Laing PW. Iatrogenic blunt arterial injury during a hip fracture surgery. *Acta Orthop Belg.* 2006 Jan; 72(1):96-9.
4. Yang KH, Yoon CS, Park HW, Won JH, Park SJ. Position of the superficial femoral artery in closed hip nailing. *Arch Orthop Trauma Surg.* 2004; 124:169 -72.
5. Manner M, Rösch B, Roy K. Vascular injuries complicating osteosynthesis in proximal femur fractures. *Unfallchirurg.* 1999 Mar; 102(3):227-31

Author Information

Pavel Mukherjee, MRCS

Department of Trauma and Orthopaedics, Torbay Hospital

Vraj G. Ladwa, FRCS

Department of Trauma and Orthopaedics, Torbay Hospital

Michael Hockings, FRCS (Orth)

Department of Trauma and Orthopaedics, Torbay Hospital