

Negative Pressure Hemoptysis Due To Airway Obstruction On Emergence From General Anesthesia For Arthroscopy

I Omar, M Syam, M Takroui

Citation

I Omar, M Syam, M Takroui. *Negative Pressure Hemoptysis Due To Airway Obstruction On Emergence From General Anesthesia For Arthroscopy*. The Internet Journal of Anesthesiology. 2007 Volume 17 Number 2.

Abstract

This is a case of negative pressure hemoptysis in a 27 years old healthy man, who was scheduled for Arthroscopy under General Anesthesia due to suspecting lateral meniscus ligament tear. After recovery of the muscle power as monitored by nerve stimulator the patient bites on the endotracheal tube and starts to struggle trying to take breathe against the bitten tube, leading to negative pressure pulmonary edema. The remarkable features were secretions with blood; hemoptysis this disappeared within few hours. The patient was breathing spontaneously through Venturi's oxygen mask system. Diuretics and lungs physiotherapy helped in controlling patient's complication. This case was the first noticed in our department. The review of anesthesia literature elicited the current view regarding capillary stress due to negative pressure generated during airway obstruction on emergence from anesthesia.

INTRODUCTION

Many reports described Negative-Pressure Pulmonary Edema (NPPE) in many clinical situations. It develops soon after relief of acute obstruction of the upper airway, expansion of collapsed lung. It is commonly happen after laryngospasm during induction or emergence from anesthesia. [2,4]

Markedly negative intra-pleural pressures during airway occlusion cause increased venous return and increased left ventricular after-load. The increased hydrostatic pressure gradient in the pulmonary capillaries leads to transudation of fluid into the alveoli. Hypoxemia and a hypoxia-induced hyperadrenergic state further promote edema formation. [5,6]

Some reports indicated that NPPE may rarely fall into the category of diffuse alveolar hemorrhage (DAH) through damage of the pulmonary capillaries by mechanical disruption of the alveolar-capillary membrane, resulting in diffuse alveolar injury. [7]

More usually, pulmonary edema is manifest, with fulfillment of the clinical, physiologic and radiographic criteria for acute lung injury (ALI) / ARDS. [7,8,9,10,11]

Frank severe hemorrhages were reported after upper airway obstruction in a fit muscular patient who bitten his artificial airway.

The first report documented both bronchoscopic and computed tomography (CT) findings consistent with alveolar hemorrhage and capillary failure in this situation. [12]

The current paper reviews the literature with the report of first observed case at KFMB of negative pressure hemoptysis in healthy man subjected to general anesthesia for arthroscopy.

CASE REPORT

A 27 y. old man was admitted for arthroscopy due to suspecting of lateral meniscus ligament tear. The patient had no history of any medical illness, was exposed to general anesthesia before but without any complications. Physical examination was un-remarkable. Anesthesia was induced with propofol 180 mg and fentanyl 100 mg and endotracheal tube placement was facilitated by cistracrium 10 mg, ventilation and intubation was easy. Anesthesia was maintained with Isoflurane 1.5%, nitrous oxide and oxygen, Morphine administered to total of 8 mg i.v. in incriminated doses.

Tourniquet was used on a pressure of 400 mm Hg for 75 minutes; the time of the procedure. At the end of the procedure the patient was given neostigmine and atropine for reversal of the muscle relaxant.

After recovery of the muscle power as monitored by nerve

stimulator the patient bites on the endotracheal tube and start to struggle trying to take breathe against the obstructed tube.

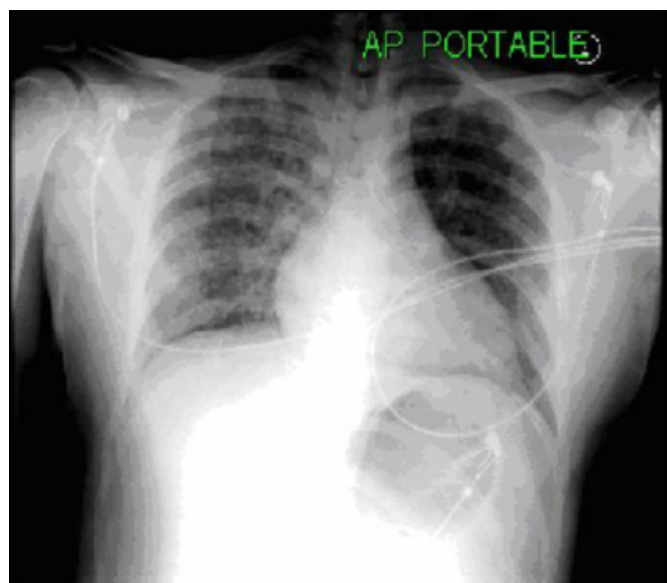
During that time the patient started to develop hemoptysis pink, blood stained frothy secretions inside the tube. Suctioning those secretions was performed, encouraging the patient to open his mouth, anesthesiologist succeed in extubate him, supporting him with O₂ mask, some manual IPP ventilation.

Transferring the patient to recovery room fully conscious, with O₂ mask, full monitor,

Sp O₂ dropped to 89% auscultation of chest revealed scattered wheezes; chest X-ray was done and revealed pulmonary patchy opacity mainly on the right side consistent with pulmonary edema. Therapy constituted nebulization with salbutamol 5 mg, lasix 120 mg, Hydrocortisone 100 mg. was given, cardiac and pulmonary consultations were done. The patient start to improve after supportive treatment, Sp O₂ reached 97% before discharging the patient from recovery room. It was noticed that cough, pinkish sputum was stopped. ECG done was normal. Patient care was transferred to pulmonologist's care that followed him in the ward till his discharge from the hospital.

Figure 1

Figure 1: The chest X-ray of the patient reported in the post anesthesia care unit (PACU) showing muscular shadows and shadows on the lung fields especially on the right lung.



DISCUSSION

Many reports of pulmonary edema secondary to acute upper airway obstruction after tracheal extubation have been

published. [1,2,3,4,5,6,7,8,9,10,11,12] it was termed as Negative-pressure pulmonary edema (NPPE), which occurs soon after the relief of acute obstruction of the upper airway. It was reported to commonly happen after laryngospasm on emergence from anesthesia. At the extubation of the trachea (0.1%) mostly caused by laryngospasm. [14,15] more understanding of pathophysiology occurred as time progressed.

The present case involved a healthy young man occurred after the patient has bitten on the endotracheal tube on emergence of anesthesia. The hypoxemia, the respiratory distress the pulmonary edema which appeared as hemoptysis confirmed the diagnosis,

The explanation can be the result of marked negative intra-pleural pressures during bitten tube occlusion cause increased venous return and increased left ventricular after-load. The increased hydrostatic pressure gradient in the pulmonary capillaries leading to transudation of fluid into the alveoli. Hypoxemia and a hypoxia-induced hyperadrenergic state further promote edema formation. Some reports indicated that NPPE may rarely fall into the category of diffuse alveolar hemorrhage (DAH) through damage of the pulmonary capillaries by mechanical disruption of the alveolar-capillary membrane, resulting in diffuse alveolar injury. More usually, pulmonary edema is manifest, with fulfillment of the clinical, physiologic, and radiographic criteria for acute lung injury (ALI) / ARDS. [7]

Upper airway obstruction from glottis closure leads to marked inspiratory efforts, which generate very negative intrathoracic pressure. This may cause pulmonary edema. [5,11,12,13,14,15,16,17,18,19,20,21,22,23,24]

During episodes of upper airway obstruction, inspiratory efforts against a closed glottis may result in markedly negative pleural pressures (>-100 cm H₂O), which tend to increase left ventricular preload and afterload. In addition, altered pulmonary vascular resistance by hypoxia and increased adrenergic state may result in right ventricle dilation, interventricular septum shift to the left and left ventricular diastolic dysfunction. These changes associated with increased left heart loading conditions (which both enhance microvascular intramural hydrostatic pressure), together with negative pleural pressure transmission to lung interstitium. [20] and, rarely, hemoptysis (which decreases extramural hydrostatic pressure), may result in a marked increase in transmural pressure, fluid filtration into the lung

(Starling equation), and the development of pulmonary edema. [19,20,21] and capillary failure [22,23]

This was confirmed by animal model study [20]

Very few reports on hemoptysis and alveolar hemorrhage in the setting of negative pressure pulmonary [15,20,21,23]. This strongly suggests, on bronchoscopy, that large intrathoracic negative pressure swings may also cause capillary failure in humans [22]. It is manifested as diffuse punctuate hemorrhages throughout the tracheobronchial tree suggesting that the systemic bronchial circulation may also be affected.

The radiographic findings associated with postextubation pulmonary edema have been reviewed [15]

CT scan sections displayed a striking preferential central and nondependent distribution of ground-glass attenuation (edema/hemorrhage) that parallels the pleural and interstitial pressure gradients. Both pressures tend to be more negative in the central and nondependent regions than in the dependent and peripheral lung regions, respectively, and those regional pressure differences tend to increase with inflation and inspiratory effort [20]. As a result, the interstitial and, therefore, perivascular pressures tend to decrease the most in the central and nondependent regions, and the transmural vascular pressure changes and capillary stress should be maximal in those regions. This could explain the striking distribution of lung edema and suggests that extramural pressure changes are instrumental in the development of pulmonary edema and capillary failure. If confirmed by other reports, this distribution of edema may be of diagnostic value. Usually, however, the diagnosis is not difficult, especially if rib retraction with poor air movement, laryngospasm, stridor, or all three are recognized.

In conclusion, negative pressure pulmonary edema. Unlike with other forms of pulmonary edema, should be recognized as one of the conditions that may manifest as alveolar hemorrhage likely caused by capillary failure [12,22]

CORRESPONDENCE TO

Ihab Omar MD, MS, Ph D Anesthesia Consultant Anesthetist,
Department of Anesthesia King Fahad Medical City –
Riyadh, Saudi Arabia Phone: (+966)1-2889999 Ext. 1389
Ihab117@yahoo.com

References

1. Takroui M, Baaj J. Bilateral negative airway pressure pulmonary edema (NPPE)-a case report. *Middle East J Anesthesiol.* 2005 Oct;18(3):631-8.
2. A. A. El-Dawlatly, K. M. Abdullah & A. Al-Dohayan: Unilateral Pulmonary Edema Following Surgical Repair Of Diaphragmatic Hernia: A Case Report: *The Internet Journal of Anesthesiology.* 2003; Volume 6, Number 2.
3. Abdelazeem Eldawlatly, Khalid Alkattan, Waseem Hajjar & Mohamed Mahdy: Difficult Placement Of Univent Tube In A Patient With Undiagnosed Tracheal Bronchus Anomaly: A Case Report And Review Of Literature: *The Internet Journal of Anesthesiology.* 2007; Volume 13, Number 1.
4. Elvin Kesimci, Bilge Aslan, Tülin Gümüş, Orhan Kanbak: Management Of Unpredicted Postoperative Negative Pressure Pulmonary Edema: A Report Of Two Cases. *The Internet Journal of Anesthesiology.* 2007. Volume 12 Number 1.
5. Sulek CR, Kirby RR: The recurring problem of negative-pressure pulmonary edema. *Curr Rev Clin Anesth* 1998;18:241-52
6. Lang SA, Duncan PG, Shephard DA, Ha HC: Pulmonary oedema associated with airway obstruction. *Can J Anaesth* 1990;37:210-8
7. Ackland G.L., Michael G. Mythen M. H. Negative Pressure Pulmonary Edema as an Unsuspected Imitator of Acute Lung Injury/ARDS. *Chest.* 2005;127:1867-1868.
8. Kollef, MH, Pluss, J Noncardiogenic pulmonary edema following upper airway obstruction. *Medicine* 1991;70,91-98
9. Palvin, DJ, Nersley, ML, Cheney, FW Increased pulmonary vascular permeability as a cause of re-expansion pulmonary oedema. *Am Rev Respir Dis* 1981;124,422-427
10. Schwartz, D, Maroo, A, Malhotra, A Negative pressure pulmonary haemorrhage. *Chest* 1999;115,1194-1197
11. Takroui M, Thallaj A, Al Jasser M. Comment on: Immediate pulmonary edema following carotid endarterectomy. *Ann Saudi Med.* 2001 ; 21 (1-2):75-6.
12. Liaudet L., Aubert J. D., Schnyder P., Schaller M. D. Negative Pressure Post-Tracheal Extubation Alveolar Hemorrhage. *Anesth. Analg.* 2001;92:273-275
13. Deepika K, Kenaan CA, Barrocas AM, et al. Negative pressure pulmonary edema after acute upper airway obstruction. *J Clin Anesth* 1997; 9: 403-8.
14. Holmes JR, Hensinger RN, Wojtys EW. Postoperative pulmonary edema in young, athletic adults. *Am J Sports Med* 1991; 19: 365-71.
15. Cascade PN, Alexander GD, Mackie DS. Negative-pressure pulmonary edema after endotracheal intubation. *Radiology* 1993; 186: 671-5.
16. Sulek CR, Kirby RR: The recurring problem of negative-pressure pulmonary edema. *Curr Rev Clin Anesth* 1998;18:241-52
17. Kollef, MH, Pluss, J Noncardiogenic pulmonary edema following upper airway obstruction. *Medicine* 1991;70,91-98.
18. Palvin, DJ, Nersley, ML, Cheney, FW Increased pulmonary vascular permeability as a cause of re-expansion pulmonary oedema. *Am Rev Respir Dis* 1981;124,422-427.
19. Willms D, Shure D. Pulmonary edema due to upper airway obstruction in adults. *Chest* 1988; 94: 1090-2
20. Lai-Fook SJ, Rodarte JR. Pleural pressure distribution and its relationship to lung volume and interstitial pressure. *J Appl Physiol* 1991; 70: 967-78.
21. Koch SM, Abramson DC, Ford M, et al. Bronchoscopic

findings in post-obstructive pulmonary oedema. Can J Anaesth 1996; 43: 73-6.

22. West JB, Mathieu-Costello O. Stress failure of pulmonary capillaries: role in lung and heart disease. Lancet 1992; 340: 762-7

23. Bhavani-Shankar K, Hart NS, Mushlin PS. Negative

pressure induced airway and pulmonary injury. Can J Anaesth 1997; 44: 78-81.

24. Tute AS, Wilkins PA, Gleed RD, et al. Negative pressure pulmonary edema as a post-anesthetic complication associated with upper airway obstruction in a horse. Vet Surg 1996; 25: 519-23.

Author Information

Ihab Omar, MD MS Ph D Anesthesia

Consultant Anesthetist, Department of Anesthesia, King Fahad Medical City

Moustafa Musa Syam, MB, ChB, MS (Anesth.), CJBA

Assistant Consultant Anesthetist, Department of Anesthesia, King Fahad Medical City

Mohamad S.M. Takrouri, MB, Ch B, FRCA (I)

Consultant Anesthetist, Department of Anesthesia, King Fahad Medical City