

Emergency Pulmonary Embolectomy in a Community Hospital: A Choice of Institutional Preference?

F Vandy, G Fromm, P Guentert, W Halloran, M Walsh, C Arnold, A Newbold, M Donnino

Citation

F Vandy, G Fromm, P Guentert, W Halloran, M Walsh, C Arnold, A Newbold, M Donnino. *Emergency Pulmonary Embolectomy in a Community Hospital: A Choice of Institutional Preference?*. The Internet Journal of Emergency Medicine. 2008 Volume 5 Number 2.

Abstract

Major pulmonary embolism (MPE), defined as a large central PE with hemodynamic instability, has been shown to carry a crude mortality rate of 17.4-28%.¹² Despite this high mortality rate, the treatment of major PE has not been well-standardized and remains controversial. Surgical embolectomy, once viewed as a procedure of last effort, has recently become incorporated into the pulmonary embolism algorithm of some tertiary medical centers.³⁴⁵⁶ However, this procedure, to our knowledge, has not yet been reported in a community hospital. We present a successful case of pulmonary embolectomy for a major pulmonary embolism performed at a community hospital, review of the literature, and propose an algorithm for the treatment of a major pulmonary embolism.

Work was done at Memorial Hospital, South Bend, IN.

CASE

A 51-year-old white male presented to the emergency department complaining of shortness of breath. The patient recounted a two-week history of cramp-like pain in his left calf that resolved two days just prior to the onset of his dyspnea. Vital signs were: blood pressure 70/40, pulse 156, respiratory rate 44, and temperature 97.4. Physical exam revealed the patient to be mottled with diminished breath sounds bilaterally. A loud right ventricular S4 gallop was heard. Arterial blood gasses revealed Ph 7.38, PCO₂ 32, PO₂ 40, HCO₃ 20 on 100 % FIO₂. A D-dimer was 12.5. A CT scan of the chest revealed large central pulmonary emboli in the right main and left main pulmonary arteries (Figure 1). Echocardiogram was significant for a dilated hypokinetic right ventricle as well as severe tricuspid regurgitation with severe pulmonary hypertension. A diagnosis of massive pulmonary emboli was made and patient was given intrapulmonary artery t-PA as well as systemic heparin. Soon thereafter, the patient decompensated and mechanical ventilation and pressor support was necessary. Cardiovascular surgery was consulted and the decision was made to proceed with surgical pulmonary embolectomy (Trendelenburg procedure). After cardiopulmonary bypass and cardioplegia, clots were

removed from the bilateral proximal pulmonary arteries with subsequent removal of debris by Fogarty catheter (Figure 2). Following successful surgical embolectomy the patient had pericardial tamponade on postoperative day one. Exploration of the mediastinum with evacuation of the clot was performed. The remainder of his hospitalization was uncomplicated. The patient was discharged on postoperative day 10 and made an uneventful recovery.

Figure 1

Figure 1: Chest CT.

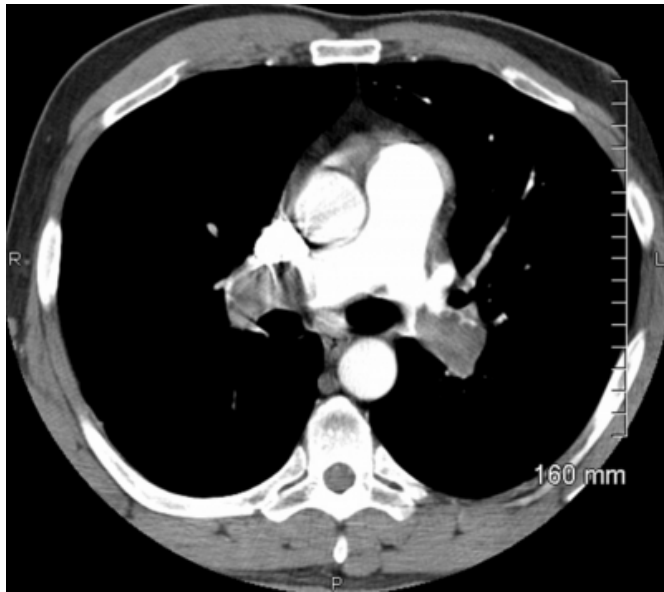
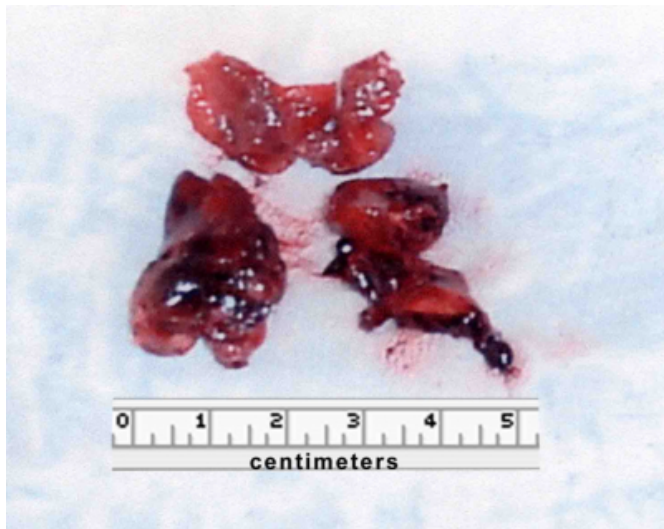
Figure 2

Figure 2: Central clots following removal by Fogarty catheter.



DISCUSSION

Surgical embolectomy, first described by Trendelenburg in 1908, has been historically regarded as a treatment of last resort, often only indicated for patients in cardiopulmonary arrest, those with contraindications of anticoagulation or thrombolytics, or those in whom aggressive medical therapy has failed.⁷ Minimally invasive catheter embolectomy has been shown to be 80% effective but carries a risk of dispersing emboli further into the pulmonary vasculature, as commercially available catheters have been shown to fragment the embolus rather than extract it.⁵ However,

recent combined clot fragmentation and aspiration has shown promise.⁸

The historical reservation of surgical embolectomy as a last resort has largely contributed to the high mortality rates and poor outcomes associated with this procedure.⁷ Prior studies have reported high mortality rates when surgical embolectomy was performed on patients already in cardiopulmonary arrest or when surgery was delayed until aggressive medical therapy had failed to relieve clot burden.⁴ The most recent data, pooled from 46 world-wide reported case series on patients operated on for pulmonary embolism from 1961-2006, reveals a marked improvement in mortality to 20% from 1985-2005. Mortality for those who had cardiac arrest prior to pulmonary embolectomy was 59% compared to 29% in patients who did not have pre-operative cardiac arrest.⁹

Although surgical embolectomy has shown potential, the choice to use it has thus far been governed on an individual basis, relying heavily on institutional preference. The choice of whether to use systemic thrombolysis, Catheter Directed Intervention (CDI) with or without local thrombolysis, or surgical embolectomy, is a matter of local institutional expertise.⁶ There has been little direct comparison of thrombolytics, CDI, and surgical embolectomy. Others have noted that the precise indications for embolectomy will probably never be based on a randomized clinical trial.¹⁰

A recent study of 40 patients who had failed initial thrombolysis describes 14 patients with surgical embolectomy and 26 with repeat thrombolysis. Successful therapy occurred with 79% of embolectomy patients and 31% of those treated with repeat thrombolysis.¹¹ A case series that directly compared mortality between thrombolytics and surgical embolectomy for massive PE favored surgery. Specifically, Gulba et al reported a mortality rate of 23% in patients undergoing surgical embolectomy as compared to 33% in patients who received thrombolytics.¹²

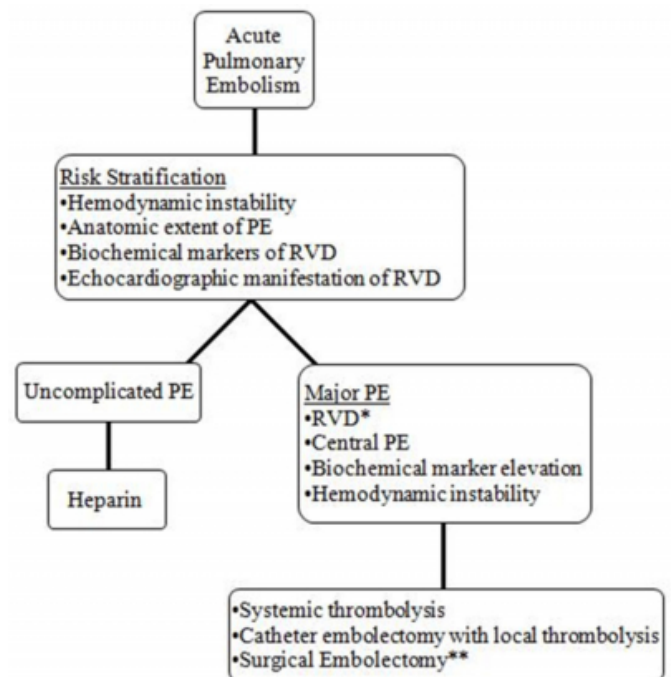
The incorporation of surgical embolectomy into the algorithm for PE, although not traditional, has given promising results. One particular group at Brigham and Women's Hospital at Harvard Medical School in Boston, Massachusetts has expanded its criteria for surgical embolectomy to include hemodynamically stable patients with submassive PE as defined by right ventricular dysfunction on echocardiography in hemodynamically stable patients.^{6,10} Centers that have adopted this practice have

reported favorable results.⁴⁵ However, the definition of submassive and massive pulmonary embolism has not been standardized. Comparison of results is made difficult by the concomitant use of submassive and massive as anatomic or physiologic indicators of clot burden. The traditional anatomic definition of massive PE is >50% occlusion of pulmonary vasculature or the occlusion of 2 or more lobar arteries.¹³ However, many authors combine the anatomic and physiologic definition of massive to describe the combination of a >50% clot burden with shock or moderate to severe right ventricular dysfunction (RVD) by echocardiographic criteria. Furthermore, submassive has also been described as large central pulmonary emboli in patients who are hemodynamically stable but who have RVD.⁵ Therefore, the standard clinical definitions of massive and submassive PE are described by the following: a massive PE is a large central clot with hypotension and signs of RVD, and a submassive PE is a large central clot with normal blood pressure and signs of RVD.⁶ Thus, there is some overlap regarding the definition of massive and submassive pulmonary emboli. Further adding to the confusion is the use of the term “major” pulmonary embolism to describe an embolism of any size associated with hemodynamic instability.¹³ These overlapping definitions of “massive,” “submassive,” and “major” pulmonary embolism, make comparison of thrombolysis and pulmonary embolectomy problematic, and the development of an algorithm for the management of PE difficult. We propose a simple algorithm based on a number of clinical, laboratory and echocardiographic parameters for the treatment of pulmonary embolism (Figure 3).

The reports of surgical pulmonary embolectomy have emphasized tertiary academic medical centers, as noted by Aklog and Goldhaber.¹⁰ We have demonstrated that surgical pulmonary embolectomy can be preformed successfully in a community hospital setting. Thus, well-prepared and capable community hospitals should consider incorporating surgical embolectomy into their algorithm for pulmonary embolism.

Figure 3

Figure 3: Algorithm for evaluation and treatment of pulmonary embolism.



* Echocardiographic Criteria for Moderate to Severe RVD: Diastolic diameter RV > 30mm, RV diastolic diameter/ LV diastolic diameter ratio > 1, paradoxical septal movement, hypokinesia RV free wall, loss of inspiratory collapse of IVC. ** Indications for embolectomy may include patients not in shock with RVD who are at specialty hospitals equipped to provide 24 hour surgical pulmonary embolectomy, and those patients who have failed thrombolysis or who are in shock with RVD and have contraindications for thrombolysis.

References

1. Goldhaber SZ, Visani L, De Rosa M. Acute pulmonary embolism: clinical outcomes in the International Cooperative Pulmonary Embolism Registry (ICOPER). *Lancet*. 1999;353:1386-9.
2. Goldhaber SZ. Pulmonary embolism. *Lancet*. 2004;363:1295-305.
3. Konstantinides S. Acute Pulmonary Embolism. *New Engl J Med*. 2008;359:2804-281.
4. Dauphine C, Omari B. Pulmonary embolectomy for acute massive pulmonary embolism. *Ann Thorac Surg*. 2005;79:1240-4.
5. Yalamanchili K, Fleisher AG, Lehrman SG, Axelrod HI, et al. Open pulmonary embolectomy for treatment of major pulmonary embolism. *Ann Thorac Surg*. 2004;77:819-23.
6. Leacche M, Unic D, Goldhaber SZ, Rawn JD, et al. Modern surgical treatment of

massive pulmonary embolism: Results in 47 consecutive patients after rapid

diagnosis and aggressive surgical approach. *J Thorac Cardiovasc Surg.* 2005;129:1018-23.

7. Meyer G, Tamisier D, Sors H, Stern M, et al. Pulmonary embolectomy: a 20-year

experience at one center. *Ann Thorac Surg.* 1991;51:232-6.

8. Eid-Lidt G, Gaspar J, Sandoval J, Damas de los Santos F, et al. Combined clot

fragmentation and aspiration in patients with acute pulmonary embolism. *Chest.*

2008;134:54-60.

9. Stein PD, Alnas M, Beemath A, Patel NR. Outcome of pulmonary embolectomy.

Am J Cardiol. 2007;99:421-423.

10. Aklog L, Williams CS, Byrne JG, Goldhaber SZ. Acute pulmonary embolectomy:

a contemporary approach. *Circulation.* 2002;105:1416-19.

11. Meneveau N, Seronde MF, Blonde MC, et al.

Management of unsuccessful thrombolysis in acute massive pulmonary embolism. *Chest.* 2006;129:1043-50.

12. Gulba DC, Schmid C, Borst H, Lichtlen P, et al. Medical compared with surgical treatment for massive pulmonary embolism. *Lancet.* 1994;343:576-77.

13. Wood KE. Major pulmonary embolism. *Chest.* 2002;121:877-905.

Author Information

Frank Vandy, MD

Department of Surgery, University of Michigan

Gary Fromm, MD

Department of Critical Care Medicine, Memorial Hospital

Paul Guentert, MD

Department of Critical Care Medicine, Memorial Hospital

Walter Halloran, MD

Department of Surgery, Memorial Hospital

Mark Walsh, MD

Department of Emergency Medicine, Memorial Hospital

Clifford Arnold, BA

Department of Emergency Medicine, Memorial Hospital

Anne Newbold, BA

University of New England College of Osteopathic Medicine

Michael Donnino, MD

Departments of Emergency Medicine and Critical Care Medicine, Beth Israel Deaconess Hospital