

Colonic Obstruction Due To Localized Giant Pseudopolyposis Complicating Ulcerative Colitis

P Christos, F Konstantinos, B Kanelina, P Afrodite, A Stilianos, G Hatzitheoharis

Citation

P Christos, F Konstantinos, B Kanelina, P Afrodite, A Stilianos, G Hatzitheoharis. *Colonic Obstruction Due To Localized Giant Pseudopolyposis Complicating Ulcerative Colitis*. The Internet Journal of Surgery. 2005 Volume 8 Number 2.

Abstract

Localized giant pseudopolyposis is an interesting but extremely rare feature of pseudopolyposis complicating ulcerative colitis or Crohn's disease. The lesion represents a localized exuberant collection of pseudopolyps giving rise to a large discrete intraluminal colonic mass, which may simulate neoplasms such as villous adenoma or polypoid cancer.

Our case concerns a 50 year old man, with a 10 year history of pancolonic ulcerative colitis under medical treatment, who presented with symptoms of subacute large bowel obstruction. At colonoscopy a large polypoid lesion was found in the distal transverse colon, causing almost complete luminal obstruction. In abdominal CT scan an obstructive thickening of the distal transverse colon, just before the splenic flexure, was seen, with the question of malignancy. The patient went on surgery and a total colectomy with ileorectal anastomosis was performed. The giant polypoid mass was located in the distal transverse colon and extended circumferentially in a distance of 15cm, causing almost complete luminal obstruction. Its macroscopic features were highly suspicious of malignancy. The microscopic examination revealed multiple pseudopolyps on a background of active ulcerative colitis changes, confirming the diagnosis of localized giant pseudopolyposis. The patient's postoperative recovery was uneventful.

INTRODUCTION

Localized giant pseudopolyposis is an interesting but extremely rare feature of pseudopolyposis complicating ulcerative colitis or Crohn's disease. The lesion represents a localized exuberant collection of pseudopolyps giving rise to a large discrete intraluminal colonic mass, which may simulate neoplasms such as villous adenoma or polypoid cancer.

Its diagnosis should be suspected whenever a villous-like or multinodular polypoid mass develops in a patient with known colitis, or when such an intraluminal mass is seen in association with radiological or endoscopic changes of diffuse or segmental inflammatory disease elsewhere in the colon.

CASE REPORT

A 50 year old man, with a 10 year history of pancolonic ulcerative colitis under medical treatment, presented with symptoms of subacute large bowel obstruction. At colonoscopy a large polypoid lesion was observed in the distal transverse colon, causing almost complete luminal

obstruction. Mucosal biopsies demonstrated chronic ulcerative colitis changes and multiple hyperplastic pseudopolyps with active inflammation findings. In abdominal CT scan an obstructive thickening of the distal transverse colon, just before the splenic flexure, was seen, with the question of malignancy.

During the time of diagnostic investigation, the patient established complete obstruction and was operated on. Intraoperatively a large neoplastic mass was found to be the cause of obstruction and total colectomy with ileorectal anastomosis was performed. The giant polypoid mass was located in the distal transverse colon and extended circumferentially in a distance of 15cm, causing almost complete luminal obstruction (Figure 1, 2). Its macroscopic features were highly suspicious of malignancy. Two more solitary polypoid lesions were found in the surgical specimen (Figure 1: A, B). The first one (A), with greater diameter of 0,5cm, was located in a distance of 6cm and, the second one (B), sized 2,5x0,4cm, in a distance of 46cm from ileocecal valve. The sigmoid colon did not appear significant macroscopic changes.

Figure 1

Figure 1: Surgical Specimen: The giant polypoid mass located in the distal transverse colon, causing almost complete luminal obstruction. Solitary polypoid lesion (A), with greater diameter 0,5cm, in a distance of 6cm from ileocecal valve. Solitary polypoid lesion (B), sized 2,5x0,4cm, in a distance of 46cm from ileocecal valve

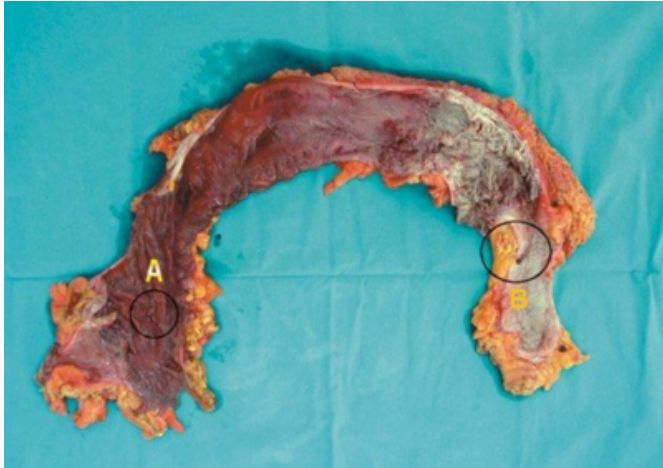
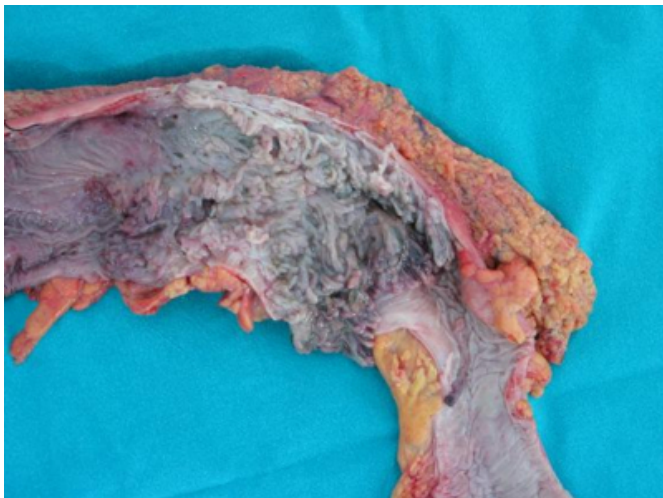


Figure 2

Figure 2: Surgical Specimen: The giant polypoid mass



The microscopic examination confirmed the diagnosis of localized giant pseudopolyposis revealing multiple pseudopolyps on a background of active ulcerative colitis changes, with cryptitis, cryptic abscesses and ulcers and, pyogenic serositis with intense fibroblastic stroma reaction (Figure 3, 4).

Figure 3

Figure 3: Microscopy: Excessive active ulcerative colitis changes with cryptitis, cryptic abscesses and ulcers (H-E X200)

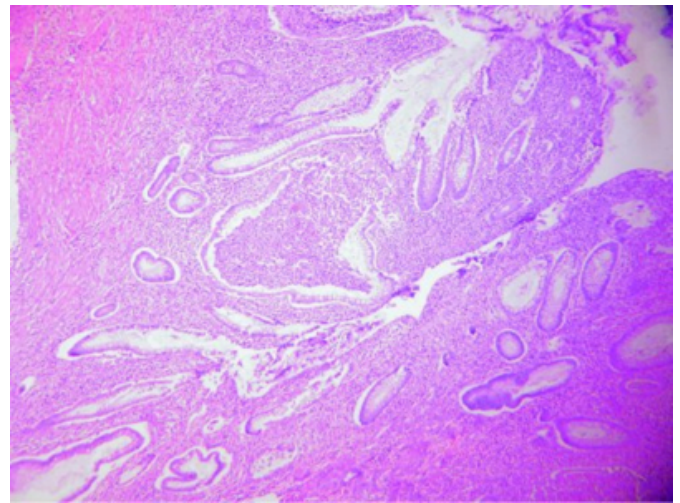
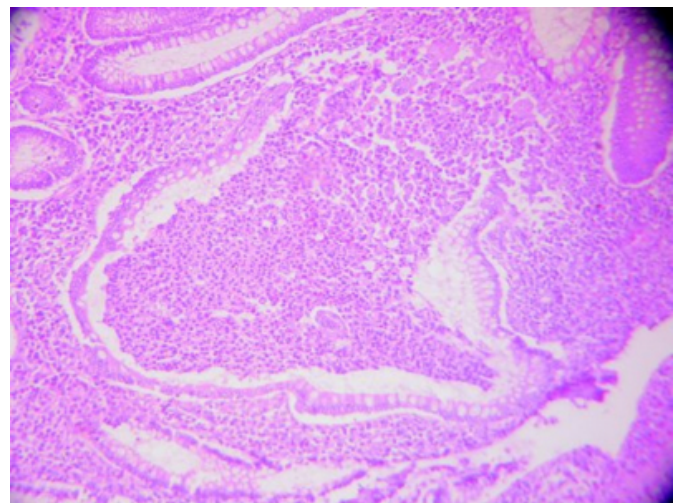


Figure 4

Figure 4: Microscopy: Multiple pseudopolyps with dense inflammatory monocyte infiltrations of mucosa extended to submucosa and partly to muscularis propria, and intense regenerative activity of lining glandular epithelium (H-E X400)



The pseudopolyps presented dense inflammatory monocyte infiltrations of mucosa extended to submucosa and partly to muscularis propria, as well as intense regenerative activity of lining glandular epithelium. The solitary polypoid lesions were found to be a villous adenoma with mild dysplasia the first (A) and, a pseudopolyp the second (B). Multiple sections from sigmoid colon demonstrated some small pseudopolyps and, disturbance of glandular architecture and cell synthesis with mucosal swelling. The patient's postoperative recovery was uneventful.

DISCUSSION

Pseudopolyposis is probably the most common local complication of ulcerative colitis¹. The reported incidence varies from 12.5% to 74%, depending on the diagnostic criteria employed and patients groups studied^{1, 2}.

Pseudopolyps represent polypoid edematous mucosal tags, regenerative mucosal islands between areas of ulceration or heaped-up granulation tissue covered by glandular epithelium (Dukes, 1954). They may be seen in the active or quiescent phase of the disease and can be diffuse or local in distribution. There is a direct relation between severity and extension of the disease and the incidence of pseudopolyposis, although the outcome of severe attacks of ulcerative colitis in the presence of pseudopolyps has been found to be more favourable². The majority of evidence supports the concept that pseudopolyposis per se is not a precancerous change and the discovery of pseudopolyps in itself does not require any specific treatment^{1, 2}.

Although pseudopolyps are the commonest sequelae of ulcerative colitis, the occurrence of localized exuberant collections of pseudopolyps, giving rise to large intraluminal masses, is a rare finding during the course of the disease³. The term 'Localized giant pseudopolyposis' has been applied to describe this phenomenon.

Localized giant pseudopolyposis may occur at any site in the colon, but only 1 case has been recorded in the rectum^{3,4,5,6,7}. The lesion is composed of numerous free and interconnecting villous or frond-like mucosal excrescences, is usually circumferential and may be as much as 12-15cm in length.

There are no specific clinical symptoms or physical findings. Localized giant pseudopolyposis may be associated with a wide variety of symptoms such as diarrhea, rectal bleeding, abdominal pain, fever, anemia and weight loss. Most of these symptoms are probably the result of the inflammatory bowel disease rather than symptoms related per se to the localized exuberant mass of pseudopolyps³. The lesion is sometimes an incidental finding of routine radiological or endoscopic follow-up in patients with long-standing colitis³. A palpable intraabdominal mass may be found on physical examination in some cases³. Large bowel obstruction, as in our patient, is a very unusual type of clinical presentation⁴.

Localized giant pseudopolyposis on barium enema examination typically appears as a large mass projecting into the lumen of the colon with numerous frond-like

excrescences, although in some patients the mass has a more discrete villonodular, polypoid configuration^{3, 6}. Motility of fronds may be appreciated on fluoroscopic examination³.

Apart from large fecal masses, the major conditions which may simulate localized giant pseudopolyposis are polypoid neoplasms such as polypoid cancer, villous adenoma and lymphoma.

Localized giant pseudopolyposis complicating ulcerative colitis can be difficultly differentiated from large bowel polypoid cancer on the basis of preoperative radiological and endoscopic, or even intraoperative findings, although cancer complicating ulcerative colitis usually presents as a constricting anaplastic infiltrative or ulcerative lesion and rarely as an intraluminal polypoid mass³. However, since polypoid cancer may occur as a complication of chronic inflammatory disease of the colon, it must always be seriously considered in the differential diagnosis of localized giant pseudopolyposis.

In some cases, as in ours, the differentiation between these two lesions cannot be made with any confidence and, extended surgical resection is mandatory, since meticulous histological examination of the resected specimen is probably the only way to exclude the possibility of malignancy and confirm the diagnosis³.

Although villous adenoma is not a recognised complication of ulcerative colitis, the radiological and endoscopic appearances of localized giant pseudopolyposis and villous adenoma may be very similar, especially when the latter exhibits prominent frond-like excrescences^{3, 6}. This type of appearance, however, is generally restricted to rectal villous adenomas and, as it is known, only 1 case of localized giant pseudopolyposis has been reported in the rectum. In the remainder of the colon, villous adenomas tend to have a more polypoid or lobulated appearance and rarely involve the entire circumference of the bowel wall.

Colonic lymphoma or lymphosarcoma may rarely present as an intraluminal polypoid mass and should be included in the differential diagnosis^{3, 6}.

Histopathological findings of localized giant pseudopolyposis are essentially those of inflammatory pseudopolyps, consisting of bands of epithelial-lined fibrovascular tissue which project and are limited to the mucosa.

The lining epithelium contains normal or hyperplastic glands

without evidence of neoplastic transformation. A mild to moderate degree of associated nonspecific acute and chronic inflammatory cell infiltration is usually present in the lamina propria and submucosa^{3,8}.

CORRESPONDENCE TO

Christos A. Papanikolaou 28 Socratus Str. 55134 Kalamaria, Thessaloniki tel – fax : 2310433906 e-mail : ascl@ippokratis.gr

References

1. De Dombal FT, Watts J, Watkinson G, Goligher JC. Local complications of ulcerative colitis: Stricture, pseudopolypoidosis and carcinoma of colon and rectum. Br Med J 1966; 5501: 1442-1447
2. Jalan KN, Sircus W, Walker RJ, McManus JP. Pseudopolypoidosis in ulcerative colitis. Lancet 1969; 2: 555-559
3. Joffe N. Localized giant pseudopolypoidosis secondary to ulcerative or granulomatous colitis. Clinical Radiology 1977; 28: 609-616
4. Keating JW, Mindell HJ. Localized giant pseudopolypoidosis in ulcerative colitis. Am Roentgenol 1976; 120: 1178-1180
5. Wills JS, Han SS. Localized giant pseudopolypoidosis complicating granulomatous ileocolitis. Radiology 1977; 122: 320
6. Foster DR. Localized giant pseudopolypoidosis in ulcerative colitis. Postgrad Med J 1982; 58: 708-710
7. Hurstone DP. Large bowel obstruction secondary to localized rectal giant pseudopolypoidosis complicating ulcerative colitis: First reported case. Endoscopy 2002; 34: 1025
8. Hinrichs HR, Goldman H. Localized giant pseudopolyps of the colon. JAMA 1968; 205: 248-249

Author Information

Papanikolaou Christos, M.D., Ph.D.

1st Surgical Unit, Hippokratio General Hospital

Fortounis Konstantinos, M.D.

1st Surgical Unit, Hippokratio General Hospital

Biba Kanelina, M.D.

1st Surgical Unit, Hippokratio General Hospital

Pantzaki Afrodite, M.D.

Department of Pathology, Hippokratio General Hospital

Ainalis Stilianos, M.D.

1st Surgical Unit, Hippokratio General Hospital

G. Hatzitheoharis, M.D., Ph.D.

Ass. Professor, Director of 1st Surgical Unit, 1st Surgical Unit, Hippokratio General Hospital