

# The Orthopaedic Enigma: A Simplified Classification

D Iyer

## Citation

D Iyer. *The Orthopaedic Enigma: A Simplified Classification*. The Internet Journal of Orthopedic Surgery. 2005 Volume 3 Number 2.

## Abstract

"The beginning of the end", "The unsolved fracture"- two statements constantly used to describe the most common, yet the most disturbing fracture in the human body -- THE FRACTURE NECK OF FEMUR!

This fracture commonly occurs in the elderly, with an increased incidence in women, following a mechanical fall. It is one of the commonest scenarios encountered by junior doctors in training, which is very easily diagnosed clinically by an externally rotated and shortened lower limb on the affected side. It requires immediate attention, as a delay just adds on to an increase in morbidity.

The aim of treatment is to get the patient back to that state of mobility which they had prior to the injury. Surgical stabilisation of the fracture along with early mobilisation leads to a decrease in morbidity.

This article mainly aims at simplifying the various classifications of this fracture, making it easy for junior doctors to aid in its aggressive treatment as early as possible to prevent morbidity.

## FRACTURE NECK OF FEMUR

The femoral neck, as mentioned before is the commonest site of fractures in the elderly. It is therefore very important for us to know how to identify, diagnose and classify them, to decide on the treatment plan. Ever since man discovered this fracture, there have been many classifications put forward. For a classification system to be useful, it must be fairly simple and easily applied.

## ANATOMICAL FACTORS

The structure of the head and neck of femur is developed for the transmission of body weight efficiently, with minimum bone mass, by appropriate distribution of the bony trabeculae in the neck. The tension trabeculae and the compression trabeculae along with the strong calcar femorale on the medial cortex of the neck of femur, form an efficient system to withstand load bearing and torsion, under normal stresses of locomotion and weight bearing.

## THE FIBROUS CAPSULE

The fibrous capsule, is the most important structure, which determines the type of fracture and its outcome.

The capsule is strong and dense, and is attached above to the acetabular margin 5 – 6 mm beyond its labrum, in front to

the outer labral aspect and near the acetabular notch, to the transverse acetabular ligament and the adjacent rim of the obturator foramen. It surrounds the femoral neck and is attached anteriorly to the intertrochanteric line, superiorly to the base of the femoral neck, posteriorly c.1cm above the intertrochanteric crest, and inferiorly to the femoral neck near the lesser trochanter. The capsule is thicker anterosuperiorly, where maximal stress occurs, particularly in standing, posteroinferiorly it is thin and loosely attached.

It is based on this capsular attachment that fractures of the neck of femur are classified as:

- INTRACAPSULAR: That is within the capsular attachment.
- EXTRACAPSULAR: That is outside the attachment of the capsule

## INTRACAPSULAR FRACTURE NECK OF FEMUR

These are classified as:

- Subcapital : That is below the head of femur.
- Trans cervical: That is through the neck of the

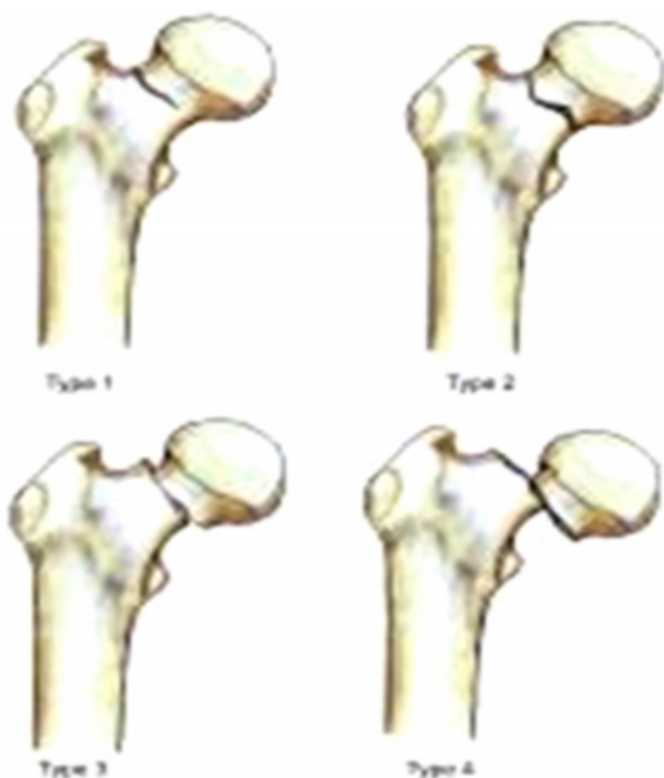
femur.

- Basal.

“GARDEN'S CLASSIFICATION”, is a well known and accepted classification to comment on the stability and displacement of intracapsular fractures.

- GRADE 1: Incomplete impacted fracture in valgus malalignment. ( Generally stable )
- GRADE 2: Complete but undisplaced fracture.
- GRADE 3: Incompletely displaced fracture in varus malalignment.
- GRADE 4: Completely displaced fracture with no engagement of 2 fragments.

**Figure 1**



This completes a simplified classification pattern for intracapsular fractures, which is widely accepted.

### WHAT IS THE IMPORTANCE OF THESE CLASSIFICATIONS?

Intracapsular fractures are notorious for their high incidence of non union. This occurs due to the disruption of blood supply to the femoral head, which leads to Avascular

necrosis and finally non union.

The femoral head obtains its blood supply from 3 sources:

1. Intramedullary vessels in the femoral neck,
2. Ascending cervical branches of the medial and lateral circumflex anastomosis, which run within the capsular retinaculum before entering the bone at the edge of the femoral head, and
3. The vessels of the ligamentum teres.

The intramedullary supply is always interrupted by the fracture, the retinacular vessels, also may be kinked or torn if the fracture is displaced. In elderly people, the remaining supply in the ligamentum teres is at best fairly meagre and, in 20% of cases, non existent. Hence the high incidence of Avascular necrosis in displaced intracapsular femoral fractures.

Intracapsular fractures will unite well if anatomically reduced and internally fixed within 6 hours of the fracture.

These fractures are known for their tardy union because:

1. By tearing the capsular vessels the injury deprives the head of its main blood supply.
2. Intra – articular bone has only a flimsy periosteum and no contact with soft tissues which could promote callus formation, and
3. Synovial fluid prevents clotting of the fracture haematoma.

### EXTRACAPSULAR FRACTURE NECK OF FEMUR

These fractures occur below the attachment of the fibrous capsule.

2 types have been commonly described:

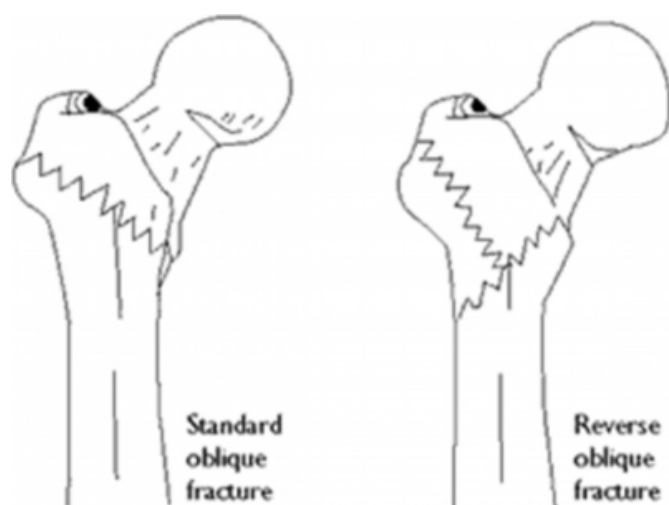
- INTERTROCHANTERIC: That is through both the Trochanters.
- SUBTROCHANTERIC: That is below the trochanters.

### INTERTROCHANTERIC FRACTURES

“ EVAN'S CLASSIFICATION”, is the most accepted classification for intertrochanteric fractures.

- TYPE 1: Undisplaced 2 part fracture.
- TYPE 2 : Displaced 2 part fracture.
- TYPE 3 : Displaced 3 part fracture with posterolateral comminution.
- TYPE 4 : Displaced 3 part fracture with large posteromedial comminuted fragment.
- TYPE 5 : Displaced 4 part fracture, with comminution involving both trochanters.

**Figure 2**



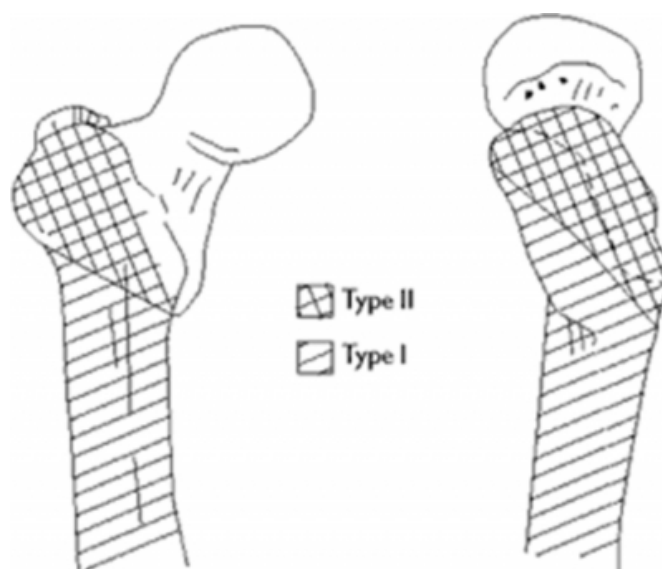
Simplified Evans' classification of intertrochanteric fractures: standard oblique fracture (stable) and reverse oblique fracture (unstable).

## SUBTROCHANTERIC FRACTURES

“RUSSEL TAYLOR CLASSIFICATION”, of Subtrochanteric fractures is most commonly followed.

- I A : Fracture extension with any degree of comminution from below the level of the lesser trochanter to the isthmus with no extension into the piriformis fossa.
- I B : Fracture extension involving the lesser trochanter to the isthmus with no extension into the piriformis fossa.
- II A : Fracture extension into the piriformis fossa. Stable medial construct.
- II B : Fracture extension into the piriformis fossa in the lesser trochanteric area with no stability of the medial femoral cortex.

**Figure 3**



Russell-Taylor classification of subtrochanteric fractures. Type I fractures do not extend into the piriformis fossa, and thus, intramedullary nailing can be beneficial. Type II fractures extend proximally into the greater trochanter and involve the piriformis fossa; this involvement complicates closed intramedullary nailing techniques.

## WHAT IS THE IMPORTANCE OF THESE CLASSIFICATIONS?

- They unite well in comparison to Intracapsular fractures.
- Extracapsular fractures are almost always treated by early internal fixation. If not reduced adequately, will result in Malunion.

## ACKNOWLEDGEMENTS

I wish to thank my Father, Mr. Krishna Mohan Iyer, Consultant Orthopaedic Surgeon, for his invaluable help and guidance, and also Mr. Nicholas Garlick, Consultant Orthopaedic Surgeon, for his immense encouragement and assistance.

## References

- r-0. GRAY'S ANATOMY: 39th edition, 1440 – 1441, Section 8, Chapter 111.
- r-1. SKELETAL TRAUMA ( Vol 2 ): Brown, Jupiter, Levine, Trafton, 1390 – 1492.
- r-2. APLEY'S SYSTEM OF ORTHOPAEDICS AND FRACTURES: 8th edition, Louis Solomon, David J. Warwick, Selvadurai Nayagam, Section 3, 684 – 685.
- r-3. [http://www.e-radiography.net/radpath/f/femur%20fracture/nECK\\_of\\_femur.htm](http://www.e-radiography.net/radpath/f/femur%20fracture/nECK_of_femur.htm) ( Accessed on the 14, November, 2005)
- r-4. <http://www.emedicine.com/radio/topic342.htm>, by

Gerald A. Malanga, MD and Jennifer Solomon, MD(  
Accessed on the 14, November, 2005)  
r-5. <http://www.orthoassociates.com/hipfx.htm>, by Paul J  
Evans, PA-C, Brian J McGrory, MD.( Accessed on 14,

November, 2005)  
r-6. <http://www.orthoassociates.com/hipfx.htm#stcl>, by Paul  
J Evans, PA-C, Brian J McGrory, MD.( Accessed on 14,  
November, 2005)

**Author Information**

**Deepa Iyer, Honorary SHO**

Dept Of Orthopaedics, Royal Free Hospital