

Paraosteal Osteosarcoma of Mandible: A Case Report

A Narwal, A Hooda, R Sen, V Singh, A Gupta, S Bala, D Sethi

Citation

A Narwal, A Hooda, R Sen, V Singh, A Gupta, S Bala, D Sethi. *Paraosteal Osteosarcoma of Mandible: A Case Report*. The Internet Journal of Otorhinolaryngology. 2010 Volume 13 Number 1.

Abstract

Osteosarcoma is the true malignant neoplasm of bone in which the malignant osteoblasts differentiate from the sarcomatous stroma and produce tumorous osteoid, tumorous bone and sometimes even tumorous cartilage. An uncommon separate class of osteosarcomas termed juxtacortical osteosarcoma, which includes intermediate grade periosteal and low-grade paraosteal variants represents less than 4% of all osteosarcomas and 1 % of all bone tumours. Juxtacortical osteosarcoma (incidence of 0.07 per 100,000 populations) occurs much less commonly than central medullary osteosarcoma. They have less aggressive biological behaviour as compared to the conventional type. So it is important to recognize these subtypes of osteosarcomas to plan treatment appropriately and avoid overtreatment. Juxtacortical osteosarcoma of the jaws appears to have a slightly more favourable prognosis than in long bones, although a larger series of cases needs to be evaluated before a definitive conclusion concerning the behaviour of juxtacortical osteosarcoma of the jaws can be made.

INTRODUCTION

Sarcomas of the head and neck region are rare tumours, accounting for only 1% of all head and neck malignancies.¹ Although osteogenic sarcomas represent the most common non-hematopoietic primary malignant bone tumour with an overall incidence of 1:100,000 per year,² osteosarcomas of the head and neck region represent only 6% to 10% of all osteosarcomas.^{3,4} Classic osteosarcomas, also termed central osteosarcoma, are still one of the most common sarcomas of the head and neck region.^{5,6} Osteosarcomas of the jaws, when compared with long bones, tend to develop in older patients. Osteosarcomas are more frequent in the mandible than in the maxilla (49% vs 37%, respectively) and are usually of high grade.⁷

Mandibular osteosarcomas arise more frequently in the posterior body and horizontal ramus, whereas, maxillary tumours are discovered more commonly in the alveolar ridge, sinus floor, and palate.⁶

Osteosarcoma is characterized by atypical cells that produce osteoid matrix protein (matrix protein produced by bone cells).³ Zarbo RJ et al have classified osteosarcomas by their site of origin into (a) the conventional type, arising within the medullary cavity; (b) extra skeletal osteosarcomas, arising rarely in soft tissue and (c) juxtacortical tumours (paraosteal & periosteal), arising from the periosteal surface

We present a case of juxtacortical variant - paraosteal osteosarcoma of the mandible along with a review of the relevant literature.

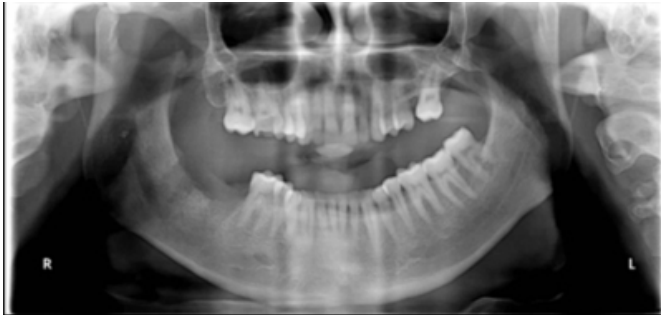CASE REPORT

A 28-year-old man presented to the Government Dental College, Rohtak, complaining of a recurrent non painful diffuse soft tissue enlargement in the right lower jaw since 20 days. The patient also had a previous dental history of three months back of firm growth at the same site i.e. on the right lower alveolar ridge which was excised along with extraction of right lower second and third molar in the same region six months back. His history also revealed that the onset of the previous mass was gradual which increased in size and became painful. He went to the private practitioner who excised the growth as well as extracted the lower second and third molars present along the growth. On further interrogation he told that he has lost his previous dental records. The patient was otherwise healthy, taking no medications except occasional analgesics, and claimed only occasional alcohol use and no tobacco use.

An OPG was advised which showed a thickened soft tissue shadow with healing sockets of 47 and 48 in the right mandibular molar region (Fig .1).

Figure 1

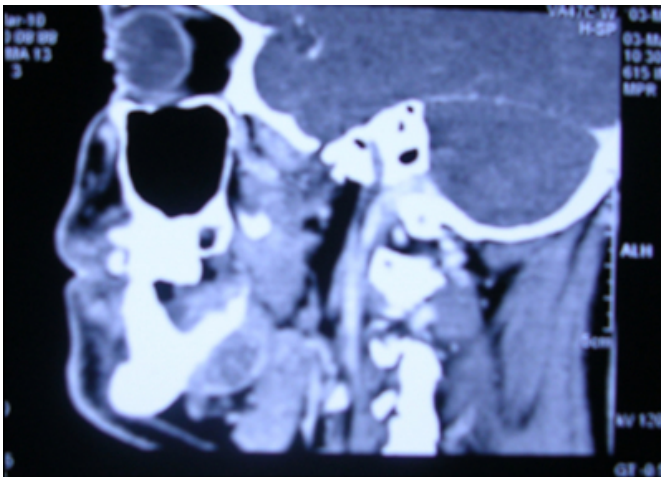
Fig : 1 – Thickened soft tissue shadow with healing sockets of 47 and 48



CT was performed, with 2.5 mm axial, non-contrasted bone, and standard algorithm images, with reconstructions in both the sagittal and coronal planes. The growth appeared well circumscribed without a hard tissue component or destructive element. There were no surrounding aggressive changes to suggest inflammation or osseous invasion seen on the CT (Fig.2). There was also not a suggestion of continuity with the medullary cavity. The radiographic appearance suggested a soft tissue growth in 47,48 region with no bony invasion.

Figure 2

Fig: 2 – No continuity with overlying periosteum as well as medullary cavity



This endophytic growth was resected from the right mandibular alveolus. On surgical exploration it was revealed that the bony mass was superficial to the cortical bone and beneath the mucosa of the mandibular alveolus. There were no areas in which the bony mass penetrated into medullary bone of the mandible. On histopathological examination, tumour mass was composed of well-developed bone trabeculae of varying thickness in a moderately to lightly

cellular stroma. In some areas, the tumor formed a nearly solid bony mass. Lacunae within the tumor bone were moderately numerous, and osteoblasts lined many of the trabeculae. The inter-trabecular stromal cells were spindle and rounded. Cellular atypia varied from slight to focally moderate. Well-formed bony trabeculae were interspersed between malignant mesenchymal cells. Fine lacelike osteoid tissues were present among pleomorphic and hyperchromatic tumour cells. Foci of cartilaginous tissue were also present (Fig.3 a&b). All the histologic features were suggestive of a low grade osteosarcoma.

Figure 3

Fig:3(a) – Numerous pleomorphic cells with deeply staining nuclei, arranged in disorderly fashion

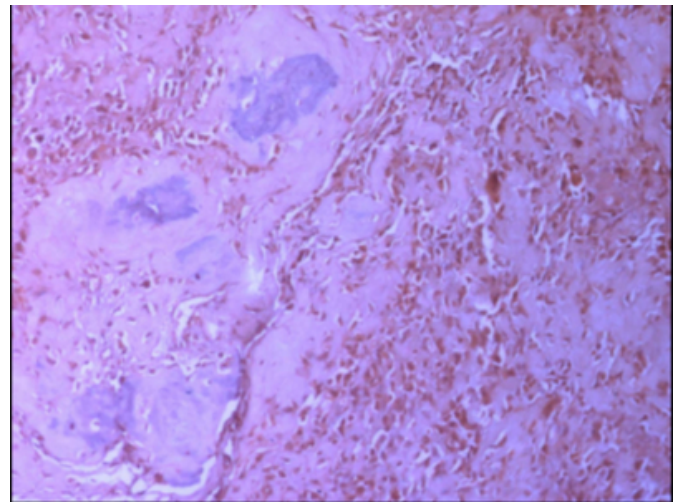
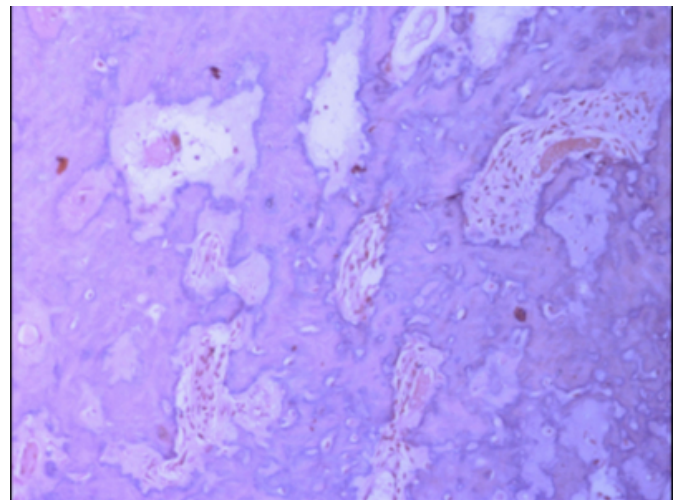


Figure 4

Fig: 3(b) New tumour osteoid and bone formation mostly in irregular pattern and at places in solid sheets are evident



DISCUSSION & REVIEW OF LITERATURE

Geschickter and Copeland provided the first description of a paraosteal osteoma in 1950. They described lesions that occurred primarily in the long bones of young or middle-aged adults. These tumors were thought to begin as ossifying fibrous tissue of the periosteum with a tendency toward malignant differentiation resembling sclerosing osteogenic sarcoma. The first report of a paraosteal osteosarcoma in a craniofacial site was reported in 1961.⁹ In 1970, Roca et al reported 2 cases of paraosteal osteogenic sarcoma, 1 of the mandible and another involving the maxilla.⁸

Paraosteal osteosarcoma occurs over a wide age range and peaks at about 39 years. The tumour most commonly involves the distal femoral metaphysis and tends to be large and slow growing. It is more common in females than in males (3:2) when long bones are affected. However, in jaw bones, it is more common in males

Histologically, the paraosteal osteosarcoma is well differentiated and is characterized by a spindle cell stroma with minimal cellular atypia and rare mitotic figures separating irregular trabeculae of bone. The periphery is less ossified than the base; it may have a lobulated cartilaginous cap or may be irregular because of linear extensions into soft tissue. It has a tendency to overgrow the base of origin and lesions are composed of intermixed bone, fibrous, and cartilaginous tissue involving the periosteum. The bland histologic appearance may lead to misdiagnosis as osteoma, osteochondroma, heterotopic ossification, or myositis ossificans.¹²

Radio-graphically, the paraosteal osteosarcoma is characteristically radio dense and homogeneous, more at the base than at the periphery.¹² The lesion appears as a lobulated nodule attached to cortical bone by means of a short pedicle.¹⁴ There is no radiographic continuity with the underlying marrow cavity.¹² The thin periosteal radiolucency, about 1-3 mm in width ("string sign") which separates the tumour from the sub-adjacent cortex, is quite characteristic but is present only in about 30% of the cases.⁹ New periosteal bone formation is absent.

In the present case, clinically no exophytic growth was evident except diffuse soft tissue enlargement in the right lower jaw. The radiographic appearance of the lesion showed no continuity with the medullary cavity as well as with the overlying periosteum. The histopathologic picture of the excised tissue from the same site showed numerous pleomorphic cells with deeply staining nuclei, arranged in

disorderly fashion. New tumour osteoid and bone formation mostly in irregular pattern and at places in solid sheets are evident. Since the presence of tumour osteoid, pleomorphic osteoblasts and absence of continuity with medullary cavity as well as with periosteum – a diagnosis of juxtacortical variant of osteosarcoma i.e. paraosteal osteosarcoma was made.

The paraosteal osteosarcoma is generally regarded as a low-grade neoplasm that is locally aggressive and may recur if incompletely excised. It is considered to have minimal metastatic potential. Local control is more limited in the maxilla than in the mandible and thus mandibular osteosarcomas overall have better prognoses than those of the maxilla. In the present case the patient had developed the lesion again within the time period of three months as his previous dental history revealed similar type of mass at the same site which was excised by the private practitioner. Due to lack of records it was not established that earlier excised lesion was also osteosarcoma. We assume that earlier the lesion was not excised completely and since the paraosteal osteosarcoma is locally aggressive, it had recurred at the same site. Now the lesion was excised completely and patient did not show any recurrence on regular follow up of last six months.

Therefore, a diagnosis of juxtacortical osteosarcoma requires complete synthesis of clinical, radiological, histopathological features of the tumour.¹¹

Treatment of osteosarcoma has undergone a distinct change over the past few decades. Before 1970s, surgery was considered the only treatment option for osteosarcoma. Role of chemotherapy was controversial, but Jaffe, Rosen and others documented improved results with post-operative chemotherapy. Now, chemotherapy, following wide excision is the recommended treatment protocol for recurrent cases and those exhibiting highly malignant features on histopathological examination.⁹

CONCLUSION

Paraosteal osteosarcomas of the mandible or maxilla are rare, low-grade variants of osteosarcoma. Paraosteal osteosarcomas of the craniofacial area behave similar to the long bone counterparts with slow growth as a low-grade malignancy that do not tend to metastasize but can recur after local excision. Although these lesions are low-grade malignancies with minimal potential to metastasize, they can recur with simple local excision. The clinical features combined with the radiologic characteristics presented are

diagnostically helpful. Definitive diagnosis comes from histopathology, and wide local resection should be employed as the optimal treatment.

References

1. Weber RS, Benjamin RS, Peters LJ, Ro JY, Achon O, Goepfert H. Soft tissue sarcomas of the head and neck in adolescents and adults. *Am J Surg* 1986;152:386–392.
2. Sturgis EM, Potter BO. Sarcomas of the head and neck region. *Curr Opin Oncol* 2003;15:239–252.
3. Caron AS, Hajdu SI, Strong EW. Osteogenic sarcoma of the facial and cranial bones. A review of forty-three cases. *Am J Surg* 1971;122:719–725.
4. Garrington GE, Scofield HH, Cornyn J, Hooker SP. Osteosarcoma of the jaws. Analysis of 56 cases. *Cancer* 1967;20:377–391.
5. Bielack SS, Kempf-Bielack B, Delling G, et al. Prognostic factors in high-grade osteosarcoma of the extremities or
6. Zarbo RJ, Carlson ER (2003): Malignancies of the jaws. In Regezi JA, Sciubba JJ, Jordan RCK (Eds.), *Oral pathology: clinical pathologic correlations*, (4th ed.), Saunders, St. Louis, Missouri. Pages: 321-328
7. Waldron CA (2002): Bone pathology. In Neville BW, Damm DD, Allen CM, Bouquot JE (Eds.), *Oral & maxillofacial pathology*, (2nd ed.), Saunders, Philadelphia. Pages: 574-578
8. Geschickter CF, Copeland MM. Parosteal osteoma of bone: a new entity. *Ann Surg* 1951;133:790–807.
9. Zarbo RJ, Regezi JA, Baker SR : Periosteal osteogenic sarcoma of the mandible, *Oral Surg* 1984, 57:643-647
10. SR Balwani, JV Tupkari, SR Barpande : Paraosteal sarcoma of mandible *J Oral Maxillofac Pathol* 2006;10:10-4
11. Minic AJ (1995): Periosteal osteosarcoma of the mandible, *Int J Oral Maxillofac Surg*, 24:226-228.
12. Shah N, Gupta YK, Safaya R (2000): Juxtacortical osteogenic sarcoma of mandible: a case report, *Ind J Dent Res*, 11: 59-64.

Author Information

Anjali Narwal, M D S

Assistant Professor, Dept. of Oral Pathology, Government Dental College

Anita Hooda, M D S

Associate Professor, Dept. of Oral Anatomy, Government Dental College

Rajeev Sen, M.D

Sr Prof & Head, Dept. of General Pathology, Post Graduate Institute of Medical Sciences

Virender Singh, M D S

Prof & Head, Dept. of Oral Surgery, Government Dental College

Ambika Gupta, M.D.S

Assistant Professor, Dept. of Oral Medicine & Radiology, Government Dental College

Shashi Bala, M.D.S

Prof. & Head, Dept of Dental Material, Government Dental College

Divya Sethi

P.G Student, Dept. of General Pathology, Post Graduate Institute of Medical Sciences