

# Cerebral Venous Thrombosis in Adults: A Clinical Study of 64 Iranian Cases

A Pashapoor, M Arami, A Valaee

## Citation

A Pashapoor, M Arami, A Valaee. *Cerebral Venous Thrombosis in Adults: A Clinical Study of 64 Iranian Cases*. The Internet Journal of Neurology. 2006 Volume 7 Number 1.

## Abstract

**Background and Purpose:** Our study purpose was to determine the clinical characteristics and etiologies of cerebral venous thrombosis in Iran.

**Methods:** We reviewed the records of all patients admitted with a documented diagnosis of cerebral venous sinus thrombosis from 2003 through 2006 in two major hospitals of Tabriz University of Medical Sciences were reviewed.

**Results:** sixty-four patients (9 men, 55 women) aged 16 to 80 years were identified. The relative frequency against arterial strokes was 1:26.31. Seventeen cases (27%) had a clinical picture of pseudotumor cerebri. Twenty-eight women (51% of female cases) had history of oral contraceptive pills (OCP) use. Nine cases were in postpartum period (16% of females). Other causes included surgical recovery period, antiphospholipid antibodies in 7, protein S deficiency in 4, systemic lupus erythematosus in 2, infections in 2, antithrombin III deficiency in 5.

**Conclusions:** In Iran, adult cerebral venous thrombosis is not uncommon. Recent onset oral contraceptive use is the single most common etiology. Infection is no longer an important cause, whereas postpartum and post surgery cases are common. Patients with a clinical diagnosis of pseudotumor cerebri syndrome should undergo brain MRI and MRV before definite diagnosis and treatment.

## INTRODUCTION

Thrombosis of the venous channels in the brain is an uncommon cause of cerebral infarction relative to arterial disease but is an important consideration because of its potential morbidity.

The symptoms and signs of cerebral venous thrombosis (CVT) are nonspecific so it may be difficult to diagnose clinically. Headache, papilledema, vomiting, seizures, and focal neurological deficits could be its presenting manifestations. (1, 2)

Newer imaging procedures have led to easier recognition of venous sinus thrombosis, offering the opportunity for early therapeutic measures. Venous thrombosis also may be associated with other medical complications that require therapeutic intervention.

In the third world, hypercoagulable states around the puerperium as well as infectious diseases are believed to be

the major causes (3, 4), but in western countries these are less significant. (5) In this article, 64 cases of CVT are reported from an Asian developing country. These were encountered over a 4-year period in the one of great northwest province of Iran. In this paper, we discuss the etiologies, clinical features and diagnosis of CVST.

## MATERIALS AND METHODS

The records of all patients with CVT seen in two large hospitals from 2003 through 2006 were reviewed. Both hospitals are the main university hospitals of the province which had neurology departments and residency educational programs. Eastern Azerbaijan has a total area of 47 821 km<sup>2</sup> and had a population of 3,588,156 at the time of the study.

The diagnosis of CVT was based on a partial or complete absence of filling of at least one dural sinus using MRI and MRV imaging. Our hospitals admit adult patients and those with 15 years of age or more were included in this study.

Neurological examination was done for all patients including ophthalmoscopy by expert neurologists. A detailed past medical history obtained for each case. All medications that were used by patients introduced to questionnaires.

The following investigations were performed in all cases: complete blood count, erythrocyte sedimentation rate, basic blood biochemistry, prothrombin time (PT), activated partial thromboplastin time (PTT), VDRL test, urinalysis, brain CT scan and cerebral MRI and MRV. Other ancillary investigations were levels of antithrombin III, protein C, protein S, and antiphospholipid antibodies.

We reviewed prescribed treatment regimens and the outcome of treatments including mortality rate.

## RESULTS

**Clinical characteristics:** There were 9 men and 55 women (85.9%) with a mean age of 43.8 years (range, 16 to 80 years). Forty-five patients (70%) presented with symptoms and signs of increased intracranial pressure but this was the sole manifestation in 17 patients (27%).

The cardinal manifestations of the 64 patients are presented in Table 1.

### Figure 1

Table 1: Symptoms and signs of CVT cases

Symptoms/Signs	no (%)
Headache	62 (96.9%)
Papilledema	45 (70.3%)
Focal neurological deficits	42 (65.6%)
Seizures	25 (39%)
Cranial nerves palsies	17 (26.6%)
Meningeal signs	8 (12.5%)
Stupor/coma	2 (3.12%)

Headaches types were as following: 34 tension type (53.1%), 15 migraine (23.4%), 8 (12.5%) mixed headache and 5 (7.8%) had chronic daily headache. Papilledema in 11 patients (17.2%) was sever (grade 3 or 4, malignant papilledema). Blurred vision was complaint of 22 cases (34.4%) and in one case it resulted to blindness.

Focal neurological deficits were found in this order: hemiparesis 29 (45.3%), hemisensory loss 12 (18.75%), language disorders 8 (12.5%), cerebellar signs 3 (4.7%). Cranial nerve involvement was seen in 16 patients (25%) and they were as: sixth nerve involvement in 10 (15.6%), seventh nerve in 6 (9.37%). Twenty-five patients (39%) +presented with seizures (focal in 7 cases and generalized in 18 patients). The mode of onset of symptoms was also highly variable. It was acute and like intracerebral or

sabarachnoid hemorrhage (<48 hours) in 8 patients (12.5%), in 26 patients (40.6%) it had a subacute course (<1 month), and in the remaining 30 patients (46.9%) the disease course was progressive over many months with exacerbation of symptoms especially visual complaints.

**Neuroimaging findings:** Brain CT was normal in 29 patients (45.3%). Hemorrhagic infarction was observed in 15 patients (23.4%), and cortical hypodensities were seen in 20 others (31.25%). The delta sign was observed in 5 patients (7.8%) only. Brain MRI and MRV was abnormal in all cases. The most common abnormality in the veins and sinus was a hyperintense image seen on proton-density sequences. Fifty (78%) had partial or complete occlusions of the superior sagittal sinus. Table 2 shows the involved sinuses respectively.

### Figure 2

Table 2: The occluded sinuses according MRI and MRV studies

Only Superior Sagittal Sinus	15 (23.4%)
Superior Sagittal Sinus and other sinuses	35 (54.7%)
Only Lateral Sinus occlusion	7 (10.9%)
Lateral Sinus and Straight Sinus	6 (9.4%)

**Etiology:** The etiologies varied also and are shown in Table 3.

In 23 of 28 cases, low dose estrogen (LD) pills had been used. Infectious processes were not common and infective mastoiditis and otitis was found in 2 cases. In overall, 12.5% of cases had a coagulation disorder in hematology studies and the most common coagulopathy was antithrombin III deficiency. Infective causes and collagen vascular disorders are not common. (Figure 1)

### Figure 3

Table 3: Causes of cerebral sinus thrombosis

Recent Oral Contraceptive Pill (OCP) Use	28 (50.9% of Females)
Postpartum period	9 (14%)
Antiphospholipid Syndrome	7 (10.9%)
Coagulopathis	8 (12.5%)
Antithrombin III deficiency	5 (7.8%)
Protein C deficiency	2 (3.1%)
Protein S deficiency	1 (1.56%)
Infections	2 (3.1%)
Systemic Lupus Erythematosus (SLE)	2 (3.1%)
Unknown	8 (12.5%)

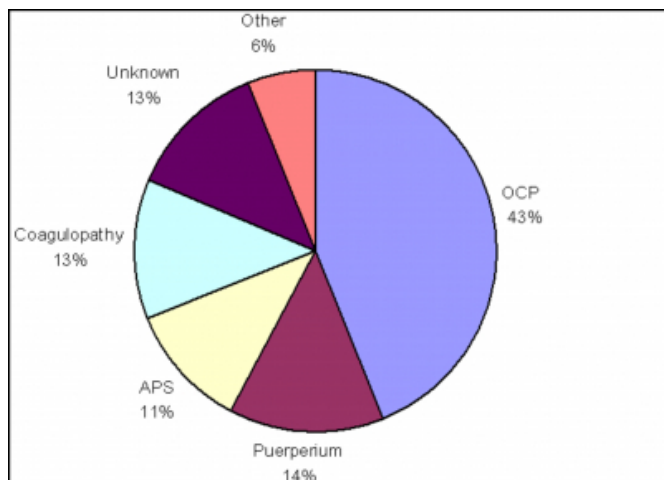
**Treatment:** Three patients (4.7%) were treated by repeated lumbar puncture. Steroids were used in 32 patients (50%). Fifty-five patients (85.9%) were treated with heparin because their condition was worsening.

**Outcome:** Forty-two patients (65.2%) recovered completely,

17 (26.6%) improved but had residual deficits and 5 died (7.8%). The cause of death in 3 cases was increased intracranial pressure and cerebral herniation and in other two patients it was due to ICU complications and aspiration pneumonia in background of severe venous infarction and resulting cerebral hemorrhage.

**Figure 4**

Figure 1: Etiologic factors in CVT in Iranian cases



## DISCUSSION

The true incidence of CVT in Iran and most regions of the world is still unknown. Kalbag and Woolf indicated that CVT was the principal cause of death in 1 per 2 million persons per year in England and Wales between 1953 and 1961.<sup>(5)</sup>

Our 64 patients were observed during 4 years in two main hospitals of district. In view of the general population, the incidence was probably less than 1 per 100 000 population per year. In each of the hospitals, about 500 arterial strokes were observed over a year so the overall ratio of CVT to arterial strokes was 1:26.3.

Headache, the most frequent and often the earliest symptom, was encountered in 62 patients (96.8%) of our cases. It was present in 75% of the 110 cases reported by Ameri and Bousser<sup>(6)</sup> and in 41% to 74% in other McLean series.<sup>(7)</sup> Isolated intracranial hypertension with headache and papilledema mimicking idiopathic intracranial hypertension was encountered in 17 patients (27%) of our cases. It was reported in 40% of cases in a series from Saudi Arabia.<sup>(8)</sup>

About 86% of our patients were females so we think this disorder is an important cause of morbidity and mortality in female population. According to the etiologic factors which determined we concluded that hormonal changes (from

external or internal sources) had a strong pathophysiologic role. We found that oral contraceptive pills use in the recent weeks was the most common event in medical histories.

In our study, cases of CVT due to infectious causes were rare and found only in 2 patients. It was the cause in 16% and 17% of the cases reported by Bousser et al<sup>(9)</sup> and Shell and Rathe, respectively.<sup>(9)</sup>

It is believed that puerperium underlie the development of CVT mainly in third-world countries. Puerperal CVT, for example, was reported to be responsible for 25% of maternal deaths in India and to complicate 4.5 of 1000 obstetrical admissions.<sup>(4)</sup> Nine cases (16%) of our patients were in puerperium period and this finding shows that regardless successful Iranian natality control programs in recent decade, however the pregnancy rate in our country is high.

Routine screening for protein S, protein C, antithrombin III deficiencies, and antiphospholipid antibodies is very important when CVT has no apparent cause. These coagulopathies may have been implicated in many earlier reported cases of idiopathic CVT. We could not found a definite cause for 8 patients (12.5%). In many reports about 20% to 30% of the CVT cases had no clear etiology.<sup>(1, 8)</sup>

In conclusion, CVT is not uncommon in Iran; infectious causes are no more common in adults. In contrast to some literatures the collagen vascular diseases are not common causes but the estrogen containing contraceptive pills are most common cause. Twenty seven percent of our patients were initially diagnosed with pseudotumor cerebri so brain MRI and MRV should be performed as part of the diagnostic workup in all patients presenting with pseudotumor cerebri. Assessment of coagulation factors such as protein C, protein S, antithrombin III, and antiphospholipid antibodies should also become a routine investigation in every patient who has CVT without apparent cause.

## References

1. Bousser MG, Barnett HJM. Cerebral venous thrombosis. In: Barnett HJM, Mohr JP, Stein BM, Yatsu FM. Stroke Pathophysiology, Diagnosis and Management. 2nd ed. New York, NY: Churchill Livingstone Inc; 1992.
2. Bousser MG, Chiras J, Sauron B, Castaigne P. Cerebral venous thrombosis: a review of 38 cases. Stroke. 1985;16:199-213.
3. Southwick FS, Richardson EP Jr, Swartz MN. Septic thrombosis of the dural venous sinuses. Medicine (Baltimore). 1986;65:82-106.
4. Srinivasan K. Ischemic cerebrovascular disease in the young: two common causes in India. Stroke. 1984;15:733-735.
5. Kalbag RM, Woolf AL. Cerebral Venous Thrombosis,

Vol 1. London, England: University Press; 1967.

6. Ameri A, Bousser MG. Cerebral venous thrombosis. *Neurol Clin.* 1992;10:87-111.

7. McLean B. Dural sinus thrombosis. *Br J Hosp Med.* 1991;45:226-231.

8. Abdulkader Daif, Adnan Awada, Saad Al-Rajeh, Mohammed Abduljabbar et al. Cerebral Venous Thrombosis in Adults, A Study of 40 Cases From Saudi Arabia. *Stroke.* 1995;26:1193-1195

9. Shell CL, Rathe RJ. Superior sagittal sinus thrombosis still a killer. *West J Med.* 1988;149:304-307.

**Author Information**

**A. Pashapoor**

Neurology Department, Imam Hospital, Milad Hospital Tabriz University of Medical Sciences

**M.A. Arami**

Neurology Department, Imam Hospital, Milad Hospital Tabriz University of Medical Sciences

**A. Valaee**

Neurology Department, Imam Hospital, Milad Hospital Tabriz University of Medical Sciences