

Anterior Chamber Implantation Cyst: A Rare Case

V Sharma, S Shrivastav, S Vaidya

Citation

V Sharma, S Shrivastav, S Vaidya. *Anterior Chamber Implantation Cyst: A Rare Case*. The Internet Journal of Ophthalmology and Visual Science. 2006 Volume 5 Number 1.

Abstract

Cysts within the globe of the eye are rare; they can be in the anterior or posterior chamber. Epithelial implantation of the cyst may occasionally result from a perforating injury, following an incised wound, or accidental perforating wound with retained foreign-body. A case of anterior chamber implantation cyst, which developed as a complication of perforating injury, is described. It was removed surgically followed by no recurrence.

INTRODUCTION

The development of cysts within eye after perforating injury is a relatively rare event, the ultimate consequences of which are usually serious. Due to virility of regeneration of corneal epithelium, if the edges of wound are not apposed, cells swarm inwards to cloth the wound entirely, proliferate along the inner aspects of cornea, fill up and block anterior chamber and creep along the anterior surface of the iris. Such epithelium growth cysts are uncommon. Only 28 cases (0.06%) were found in 45,500 consecutive perforating wounds (accidental or surgical) ¹. Anterior chamber implantation cysts have been reported as rare cases after penetrating keratoplasty², cataract surgery³, or perforation of cornea⁴.

CASE

A 43 year-old male, villager, blacksmith, residing in the village of Kandle, Badnawar, presented with a history of gradually progressive diminution of vision in the right eye since 6-8 months. There was watering, mild pain in the eye along with recurrent redness of the eye since 1 year. There was history of injury by nail while on job as blacksmith, 3^{1/2} years back. The local physician treated him. No relevant significant detail of past treatment was available, except, that vision was normal after 1-2 months of injury.

ON EXAMINATION

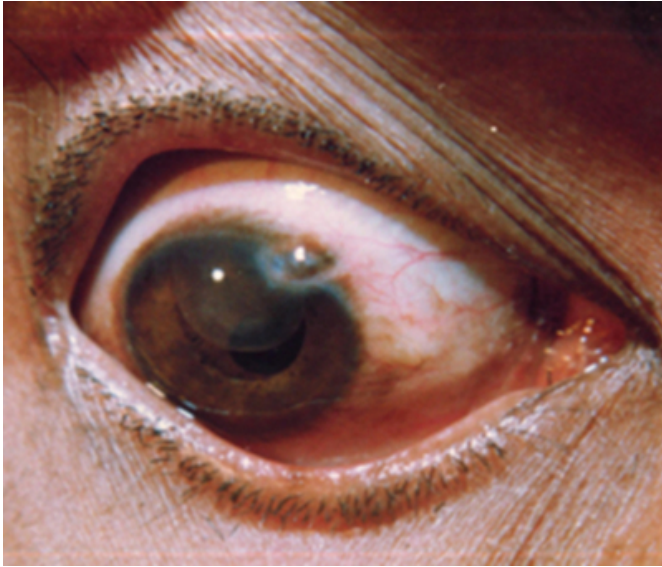
Visual acuity (V.A.): Right Eye - 3/60 Left Eye - 6/9

Intraocular pressure (Schiotz): Right Eye 19.4 mm of Hg.
Left Eye 17.3 mm of Hg.

The left eye was essentially normal. In the right eye there was a scar mark with localized raised area (a bleb) at limbus from 12 to 2 o'clock position. Iris pigment was visible in the bleb. There was no conjunctival congestion. In the anterior chamber 5 mm diameter cystic, a translucent swelling was present, attached from 10 to 2 clock position to the limbus but free on the lower side. The cyst was casting a shadow on the iris. The iris was normal in pattern. The pupil was slightly dilated, pear shaped, pointing towards the scar at 1 o'clock position. The iris was incarcerated in the scar. The lens was normal. On slit lamp examination, the translucent cyst was attached to the scar, the cornea was normal, the iris was pulled up in the wound, and the pupil was pear shaped, reacting to light. On Gonioscopy, there was obliteration of the angle in the upper part by the cyst; the rest of the angle was normal. Ultra-sonography was done, there was no foreign body detected in the scar or in the cyst or elsewhere.

Figure 1

Figure 1: Anterior chamber implantation cyst



Surgical removal of the cyst was done under local anaesthesia. A fornix base conjunctival flap was made, From 10 to 2 o'clock ab-externo corneal section was made by 11 no. scalpel blade. The cyst collapsed as the section was made; the cyst wall was removed in-toto by capsular forceps. The wound was freshened, all the tissues presents in the wound were removed and incarcerated iris was abscised. After air injection wound was closed by 8-0 mersilk, interrupted sutures. Histopathology of the tissue showed that the cyst was composed of stratified, non-keratinized squamous epithelium attached to loose fibrovascular tissue including island of melanin – containing epithelial cells. This was interpreted as epithelial implantation cyst of the anterior chamber of corneal origin attached to iris tissue. Postoperatively systemic & local antibiotics, anti-inflammatory, topical cortico-steroids and mydriatics were given. Sutures were removed after 1 month. Corrected vision was 6/9. Follow-up was done for 2 years. No recurrence occurred.

DISCUSSION

Within the globe of the eye cysts are rare; they can be in the anterior or posterior chamber. Epithelial implantation cysts may occasionally result from a perforating injury, following an incised wound or accidental perforating wound with retained foreign-body- steel instruments or glass, it may

occur even with a lead pencil₁. The wall of the cyst may remain continuous with the surface epithelium along the track of the wound. The implantation cyst thus formed are of two types: PEARL CYST: appears as solid greyish white round or oval with a pearly luster, usually situated in iris stroma or in the angle of anterior chamber. SEROUS CYST, which are more common as compared to pearl cyst. They may arise within few weeks or many years after injury₁. Three stages are common:

1. Symptom free with no visual disturbances
2. Irritative period due to iridocyclitis.
3. Raised tension leads to absolute glaucoma.

Sympathetic ophthalmitis may occur in the other eye₁. Occasionally intra ocular cysts cease to grow and may remain unchanged for an indefinite period of time. They may become smaller and disappear. The cyst is usually treated with Nd: YAG laser₅ or laser_{6, 7}. But the cyst has a tendency to reform that requires multiple treatment sessions or eventually surgical removal_{5, 7}.

Fortunately in our case no complication occurred and also no recurrence was detected even after 2 years, possibly because total removal of cyst was done.

References

1. Duke-Elder SS, MacFaul PA. System of Ophthalmology, London: Henry Kimpton Publishers; 1972 (Vol XIV Part 1). P327-332, 411-412.
2. Avni I, Cahane M, Blumenthal M, Naveh N. Transformation of corneal epithelial cyst into anterior chamber implantation cyst and scleral cyst: a rare occurrence. J. Pediatr Ophthalmol Strabismus 1989; 26(6): 303-6.
3. Narain L, Sinha AK. Implantation cyst in A.C. after ataract surgery. Indian J Ophthalmol. 1983; 31 Suppl: 884-5.
4. Ibechukwu BI, Ikerionwu SE, al-Faran MF. Intraocular implantation dermoid cyst of the iris: case report. East Afr Med J. 1996 Mar; 73(3): 210-1.
5. Cahane M, Rosner M, Avni I, Chen V, Blumenthal M. Nd: YAG laser treatment of anterior chamber implantation cysts. Metab Pediatr Syst Ophthalmol. 1988; 11(1-2): 47-48.
6. Sugar J, Jampol LM, Goldberg MF. Argon laser destruction of anterior chamber implantation cyst. Ophthalmology. 1985 Feb; 92(2): 306-7.
7. Sugar J, Jampol LM, Goldberg MF. Argon laser destruction of anterior chamber implantation cysts. Ophthalmology. 1984 Sep; 91(9): 1040-4.

Author Information

Virendra Kumar Sharma, M.S.

Associate Professor, Department Of Ophthalmology, R.D.Gardi Medical College & Ujjain Charitable Trust Hospital
Budhwariya

Saurabh Shrivastav, M.S.

Assistant Professor, Department Of Ophthalmology, R.D.Gardi Medical College & Ujjain Charitable Trust Hospital
Budhwariya

Sudhakar Vaidya, D.L.O. D.N.B.

Associate Professor, Department of E.N.T., R.D.Gardi Medical College & Ujjain Charitable Trust Hospital Budhwariya