

Cardiac Tamponade Secondary To Suppurative Pericarditis. A Case Report And Review Of The Literature

C Reising, M Jadali, N Paradise

Citation

C Reising, M Jadali, N Paradise. *Cardiac Tamponade Secondary To Suppurative Pericarditis. A Case Report And Review Of The Literature*. The Internet Journal of Anesthesiology. 2000 Volume 5 Number 2.

Abstract

Abstract

Suppurative pericarditis is an uncommon cause of cardiac tamponade with a high mortality rate. It often develops in the presence of a coexistent local or systemic infection. Early diagnosis of purulent pericarditis is essential to survival. Liberal use of echocardiography and pericardial fluid analysis of pericardial effusions in the presence of coexistent infections to rule out purulent pericarditis is important for early diagnosis. Combined pericardial drainage and broad-spectrum antibiotics are the mainstays of therapy for this disease. We present a case of a 29 year-old male patient with clinical and ultrasonographic evidence of cardiac tamponade secondary to suppurative pericarditis.

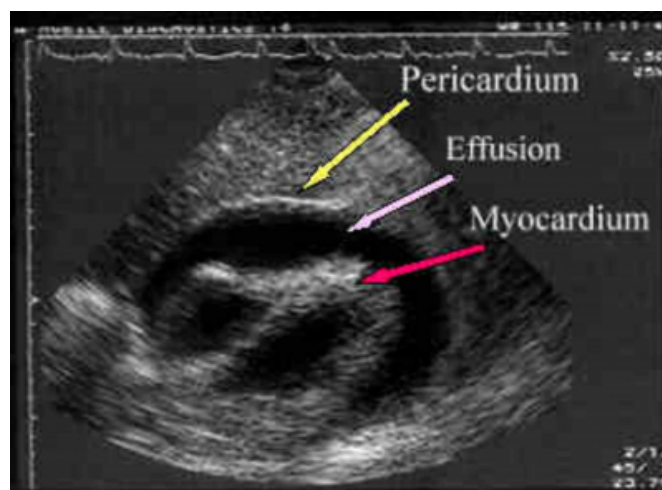
CASE

A 29-year-old male was admitted to the hospital for shortness of breath, fever leukocytosis and chest x-ray demonstrating a right middle lobe infiltrate and an enlarged cardiac silhouette. He was initially treated with intravenous fluid hydration and erythromycin. Mycoplasma titers and cold agglutinin tests were positive, and an echocardiogram showed a moderate sized pericardial effusion. The diagnosis of mycoplasma pneumonia with associated pericardial effusion was established and treatment was continued with intravenous erythromycin, non-steroidal anti-inflammatories (NSAIDs) and prednisone. After significant clinical improvement in his shortness of breath, resolution of his fevers and a follow up echocardiogram demonstrating a stable, moderate sized pericardial effusion he was discharged from the hospital on oral antibiotics, NSAIDs, prednisone and scheduled follow appointments for one week.

Four days following his discharge this patient returned to the emergency room with complaints of shortness of breath and chest pain. On examination the patient was diaphoretic and pale, with jugular venous distention, distant heart tones, tachypnea, tachycardia and hypotension. A rapid transthoracic ultrasound of the chest was performed revealing a massive pericardial effusion with pan-cycle right atrial collapse.

Figure 1

Figure 1. Transthoracic echocardiogram with doppler demonstrating massive pericardial effusion



The patient was emergently intubated, intravenous access was obtained, and pericardiocentesis with catheter drainage was performed under fluoroscopic guidance. Approximately five hundred milliliters of purulent fluid were aspirated from the pericardial space. The patient's tachycardia and hypotension resolved immediately. A pre-pericardiocentesis arterial blood gas revealed a profound metabolic acidosis. pH 6.96, pCO₂ 45, pO₂ 48, base deficit 18.9. Initial WBC was 75 k/ul (71% neutrophils; 12% bands). Serum chemistries were significant for potassium of 7.2 mmol/L,

BUN 84 mg/dl, and creatinine 4.6 mg/dl. The patient was aggressively resuscitated with isotonic saline, intravenous insulin, dextrose, calcium, bicarbonate, and broad-spectrum antibiotics. Gram stain of the pericardial fluid revealed predominantly leukocytes with many gram-positive cocci in chains. The final microbiology culture of the pericardial fluid isolated streptococcus intermedius. After a brief period of stabilization the patient developed disseminated intravascular coagulopathy and multiorgan system failure. His condition progressed to a refractory shock-state and circulatory collapse.

DISCUSSION

The diagnosis of purulent pericarditis requires a high index of suspicion and is difficult to make because the presence of coexistent local or systemic infection can mask the clinical manifestations of the disease. If untreated, purulent pericarditis rapidly evolves into suppurative pericarditis with pericardial tamponade and death (1). Even with adequate treatment, purulent pericarditis has a mortality rate between 40 and 75% (2,5). This high mortality is probably due to delayed diagnosis and the significant comorbid disease of these critically ill patients.

The microbiology and epidemiology of purulent pericarditis have changed dramatically in the last thirty years (2). In the past staphylococcus aureus, hemophilus influenzae, and pneumococcus were the predominant organisms isolated from the pericardium, often as extension from a local infection, such as pneumonia, empyema or endocarditis (3). Currently, gram-negative enteric bacteria account for more than one third of cases and fungal isolates, including candida and aspergilosis, are increasingly more common (2,4). Although the incidence of purulent pericarditis is decreasing, the spectrum of patients is no longer isolated to pediatric and young adult patients (5). Immunocompromised, critically ill, and chronic renal failure patients make up a significant percentage of the patients with this disease. These changes in incidence, epidemiology and microbiology are likely the result of improved antibiotics and an increasing population who are immunosuppressed secondary to HIV, transplantation, hemodialysis and cytotoxic chemotherapeutic drugs (5).

The treatment of purulent pericarditis is based on definitive surgical drainage, appropriate intravenous antibiotic coverage, and adequate resuscitation (6,7). As with any

closed space infection, surgical drainage is essential and can be accomplished by pericardiocentesis, with or without catheter drainage or open surgical drainage. A subxyphoid window provides wide drainage with the additional benefit of subsequent digital exploration of the pericardial space to break down adhesions and loculations of infected fluid collections. Because of the increased incidence of gram-negative enteric and anaerobic bacteria causing purulent pericarditis, broad-spectrum intravenous antibiotics covering gram positive, gram negative, and anaerobic bacteria must be used (6). In addition, anti-fungal coverage may be necessary if clinically indicated until all culture results are obtained.

CONCLUSION

This case illustrates the importance of aggressive evaluation of pericardial effusions in the presence of an adjacent focus of infection. A high index of suspicion, liberal use of echocardiography and diagnostic pericardiocentesis, and rapid surgical drainage combined with broad-spectrum antibiotic coverage are the mainstays of treatment for this disease.

AUTHOR CORRESPONDENCE

Chris A. Reising MD
2015 Center Street
West Des Moines, IA 50265.
Home Ph: 515-327-0796
Work Ph: 515-241-4078
E-mail address: creising@netzero.net

References

1. Milind M, Mandakolathur R, Hemant M, et al. Rapid evolution of cardiac tamponade due to bacterial pericarditis in two patients with HIV-1 infection. Chest. 101: 1461-1463, 1992.
2. Rudin R, Moellering R. Clinical, microbiologic and therapeutic aspects of purulent pericarditis. Am J Med. 59: 68-78, 1975.
3. Feldman W. Bacterial etiology and mortality of purulent pericarditis in pediatric patients. Am J Dis Child. 133: 641-644, 1979.
4. Parsons R, Argoud G, Palmer D. Mixed bacterial infection of the pericardium. Southern Medical Journal. 76(8): 1046-1048, 1983.
5. Klacsmann P, Bulkley B, Hutchins G. The changed spectrum of purulent pericarditis. Am J Med. 63: 666-673, 1977.
6. Dupuis C, Gronnier P, Kachaner J. Bacterial Pericarditis in infancy and childhood. Am J Card. 74: 807-809, 1994.
7. Okoroma E, Perry L, Scott L. Acute bacterial pericarditis in children: Report of 25 cases. Am Heart J. 90(6): 709-713, 1975.

Author Information

Christopher A Reising, MD

Cheif Surgery Resident, Department of Surgery, Iowa Methodist Medical Center

M. Jadali, MD, FACS

Associate Director of Surgery, Surgery, Iowa Methodist Medical Center; Broadlawns Medical Center

Norman Paradise, Ph.D.

Research Director, Medical Education; Research, Iowa Methodist Medical Center