

Acetaminophen poisoning: Case Report

C Kavalci, G Kavalci, E Sezenler

Citation

C Kavalci, G Kavalci, E Sezenler. *Acetaminophen poisoning: Case Report*. The Internet Journal of Toxicology. 2008 Volume 6 Number 2.

Abstract

Acetaminophen is probably the most widely used drug in the world. This report aims to review a case of acetaminophen poisoning and management. A 16-year-old female presented to the emergency department with acute intoxication. She ingested a total amount of 3.5 gram (g) of Amoxicilin and 8 g of Acetaminophen for suicidal attempt. Urine acetaminophen levels were measured using with Triage tox drug screen test and N-acetylcysteine (NAC) was given intravenously following a treatment protocol due to high toxic acetaminophen levels (>7.5 g). During observation there was no clinical finding or laboratory abnormality. So she was discharged at 30 hours after admission. The patient was called for control one week later and control liver functions were normal.

BACKGROUND

Acetaminophen (paracetamol, N-acetyl-p-aminophenol) is an effective, mild analgesic, antipyretic agent and probably the most widely used drug in the world because is inexpensive and sold without prescription. The most important complication of a major overdose of acetaminophen is acute centrilobular hepatic necrosis, but only a small minority of patients is at risk. Some 25 years ago before effective antidotal therapy became generally available, less than 10% of patients referred to the hospital with acetaminophen poisoning developed severe liver damage (defined as maximum plasma alanine or aspartate aminotransferase exceeding 1,000 IU/L), and 1% to 3% developed fulminant hepatic failure (1). Analgesics were found most commonly the first or second cause of intoxication in various reports (2,3,4,5,6,7,8,9). In this presentation we aimed to review a case of acetaminophen intoxication due to suicide.

CASE

A 16-year-old female presented to the emergency department with intoxication. She previously ingested a total amount of 3.5gram (g) Amoxicilin and 8 g of Acetaminophen to commit suicide. One hour after ingestion she initially looked for medical assistance in a county hospital from where the patient was transferred to our hospital. At admission she was complaining of abdominal pain and nausea.

During physical examination her general condition was well,

blood pressure and pulse rate were 130/90 mmHg and 90 bpm respectively. An intravenous line was inserted to start the infusion of isotonic solutions at 1500 ml for 24h . Patients was monitored and evaluated every hour.

Blood was drawn for laboratory assessments. Her laboratory findings during admission and discharge are shown in Table-1. Gastric lavage was not indicated because four hours had passed after ingestion. One gram/ kilogram active charcoal was administered via nasogastric tube. Urine acetaminophen levels were measured using Triage tox drug screen test and N-acetylcysteine (NAC) was given to intravenous treatment protocol because seen in toxic levels (>7.5 g). During observation there was no clinical finding or laboratory abnormality. So she was discharged at 30 hours after admission. The patient was called for control one week later and control liver functions were normal. She was not evaluted later.

Figure 1

Table-1: Laboratory findings of patient in admission and discharge.

	Admission laboratory finding	Discharge laboratory finding
Glucose mg/dl	119	100
BUN mg/dl	21	15
Creatinine mg/dl	0,7	0,7
Total bilirubin mg/dl	0,7	0,8
Direct bilirubin mg/dl	0,3	0,3
Ast U/L	47	27
Alt U/L	14	10
Ldh U/L	478	515
Alkaline phosphatase U/L	180	144
PT sn	19,4	19,8
Inr	1,6	1,65
Wbc mm ³	5600	7800
pH	7,42	7,40
pO ₂	91,2	95
pCO ₂	36,7	36
SpO ₂ (%)	98	98
HCO ₃	23,5	20

DISCUSSION

Acetaminophen (paracetamol, N-acetyl-p-aminophenol) is probably the most widely used of all drugs in the world. Acetaminophen poisoning is frequently seen due to accidentally or suicide. A toxic exposure to acetaminophen is suggested when greater than 140 mg/kg is ingested in a single dose or when greater than 7.5 g is ingested within a 24-h period (10).

The clinical presentation of human acetaminophen toxicity can be approximately divided into four stages. During the first 24 h after exposure (stage 1), patients often have minimal signs and symptoms of toxicity. Some may have minor, nonspecific signs and symptoms such as anorexia, nausea, vomiting, pallor, and malaise. By days 2 to 3 (stage 2), clinical signs of hepatotoxicity that may be discerned in hepatotoxic patients include right upper quadrant abdominal pain and tenderness, and abnormal laboratory tests, such as elevated serum aspartate aminotransferase (AST), alanine aminotransferase (ALT), and bilirubin. Even without treatment, most of these patients will recover without sequelae. By days 3 to 4 (stage 3), however, the conditions of some patients will progress to fulminant hepatic failure. Characteristic findings include metabolic acidosis, coagulopathy, renal failure, encephalopathy, and recurrent

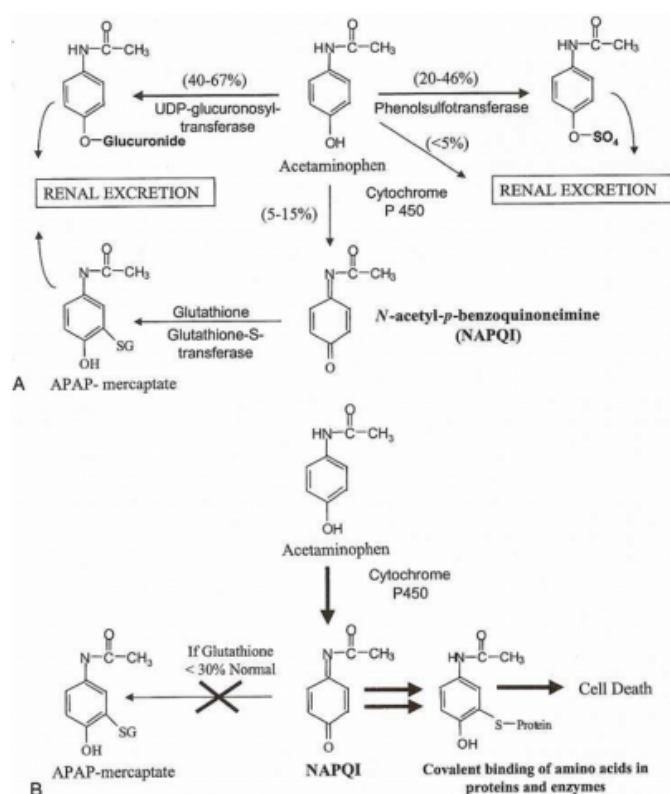
gastrointestinal (GI) symptoms. Those patients who survive the complications of fulminant hepatic failure will begin to recover over the next week (stage 4), with complete resolution of hepatic dysfunction in survivors (10). The plasma acetaminophen concentration provides a good diagnostic indicator, and treatment is successful in patients presenting early with an accurate history, particularly with regard to time of ingestion which is essential for interpreting acetaminophen concentration (3). If a plasma acetaminophen concentration is not measured, urine acetaminophen concentration can be measured. Urine levels of acetaminophen were approached in this patient with Triage Tox drug screen test, and acetylsistein treatment was started due to its high toxic levels of acetaminophen found.

With therapeutic dosing, 90% of N-acetyl-p-aminophenol (NAPAP) is conjugated with glucuronide or sulfate to form nontoxic metabolites (10). Approximately 5% of APAP is metabolized by the hepatic cytochrome p450 mixed-function oxidase enzyme to a toxic metabolite, N-acetyl-p-benzoquinoneimine (NAPQI). In normal dosing, NAPQI is rapidly detoxified by glutathione (GSH) to nontoxic metabolites (figure-1).

Treatment for acetaminophen toxicity consists of GI decontamination, timely use of the antidote, iv-acetylcysteine (NAC), and supportive care. In most of the cases of acetaminophen poisoning, adequate GI decontamination consists of the early administration of activated charcoal orally or through a nasogastric tube (10). Activated charcoal can be given within one hour of ingestion (3). Despite NAC is adsorbed by activated charcoal, there is no evidence that activated charcoal inhibits the clinical effectiveness of NAC (10). The mainstay for the prevention or treatment of acetaminophen induced liver toxicity is the administration of NAC. Although its mechanisms of action are not fully understood (3,10). NAC is thought to have two important beneficial effects. In early acetaminophen toxicity (less than 8 h after ingestion), NAC prevents toxicity by inhibiting the binding of the toxic metabolite NAPQI to hepatic proteins. NAC may do this by acting as a glutathione precursor or substitute, a sulfate precursor, or it may directly reduce NAPQI back to acetaminophen. In established acetaminophen toxicity, or greater than 24 h after acetaminophen ingestion, NAC diminishes hepatic necrosis by acting as an antioxidant, decreasing neutrophil infiltration, improving microcirculatory blood flow, or increasing tissue oxygen delivery and extraction

Figure 2

Figure-1: Acetaminophen metabolism (10)



Acetaminophen overdoses overwhelm conjugation pathways, resulting in increased use of the cytochrome p450 pathway and increased formation of NAPQI, increased depletion of GSH, and, ultimately, hepatic injury (11,12,13,14). Acetylcysteine acts as a precursor for the synthesis of glutathione and by enhancing the reduction of NAPQI to APAP. NAC used can be orally or intravenously.

The standard 72-hour oral NAC regimen is a loading dose of 140 mg/kg followed by maintenance doses 70 mg/kg every 4 h for 17 doses. The 20-hour IV NAC protocol is 150 mg/kg loading dose over 15 minutes, followed by an additional dose of 50 mg/kg over 4 hours and then 100 mg/kg over 16 hours for a total dose of 300 mg/kg (10,15,16). If treatment is initiated within 8 h of acetaminophen ingestion, NAC is nearly 100% effective in preventing the development of hepatotoxicity, as defined by an AST level of greater than 1000 U/L (10). The most commonly reported adverse effects of intravenous acetylcysteine are anaphylactoid reactions, including rash, pruritus, angioedema, bronchospasm, tachycardia, and hypotension (16). She was administered NAC according to intravenous treatment protocol and discharged at 30 hours after admission because to the

absence of clinical and laboratory signs of toxicity. The patient was called for control 1 week later and control liver functions are normal.

CONCLUSION

Acute acetaminophen poisoning is a straightforward problem. Acetaminophen is one of the agents frequently used for suicide. Activated charcoal seems the best choice to reduce absorption. NAC should be given to patients with overdose. Our patient treatment was successful with NAC.

References

- Prescott L. Oral or Intravenous N-Acetylcysteine for Acetaminophen Poisoning? doi:10.1016/j.annemergmed.2004.09.028
- Cemil Kavalci, Yunsur Çevik, Mehmet Özer, Polat Durukan, İbrahim İkizceli, Gülsüm Kavalci. Characteristics Of Poisoning Cases In Ankara, Turkey. The Internet Journal of Emergency Medicine 2009;5:Number 1.
- Volans G, Hartley V, McCrea S, Monaghan J. Non-opioid analgesic poisoning. Clin Med 2003;3:119-123
- Pekdemir M, Kavalci C, Durukan P, Yıldız M. Acil Servisimize Başvuran Zehirlenme Olgularının Değerlendirilmesi. Acil Tıp Dergisi 2002; 2: 36-40.
- Akbaba M, Nazlican E, Demirhindi H, Sütölük Z, Gököl Y. Etiological and demographical characteristics of acute adult poisoning in Adana, Turkey. Hum Exp Toxicol. 2007;26:401-6.
- Mert E, Bilgin NG. Demographical, aetiological and clinical characteristics of poisoning in Mersin, Turkey. Hum Exp Toxicol 2006; 25: 217-223
- Goksu S, Yildirim C, Kocoglu H, Tutak A, Oner U. Characteristics of acute adult poisoning in Gaziantep. J Toxicol Clin Toxicol 2002; 40: 833-7.
- Tufekci IB, Curgunlu A, Sirin F. Characteristics of acute adult poisoning cases admitted to a university hospital in Istanbul. Hum Exp Toxicol 2004; 23: 347-351.
- Seydaoglu G, Satar S, Alparslan N. Frequency and Mortality Risk Factors of Acute Adult Poisoning in Adana, Turkey, 1997-2002. Mt Sinai J of Med. 2005; 72: 393-401
- Hung O, Nelson LS. Acetaminophen. In Tintinalli JE, Kelen GD, Stapczynski JS, editors. Emergency Medicine: A Comprehensive Study Guide 6th ed. New York, NY: McGraw Hill; 2004. p. 1088- 1094.
- Thummel KE, Slattery JT, Ro H, Chien JY, Nelson SD, Lown KE, Watkins PB. Ethanol and production of the hepatotoxicmetabolite of acetaminophen in healthy adults. Clin Pharmacol Ther 2000;67(6):591-9.
- Rumack BH. Acetaminophen misconceptions. Hepatology 2004;40(1):10-5.
- Rumack BH. Acetaminophen hepatotoxicity: the first 35 years. J Toxicol Clin Toxicol 2002;40(1):3-20.
- Rowden AK, Norvell J, Eldridge DL, Kirk MA. Acetaminophen Poisoning. Clin Lab Med 2006;26: 49-65.
- Howland MA. Table of Antidotes in Depth. In: Flomenbaum NE, Goldfrank LR, Hoffman RS, Howland MA, Lewin NA, Nelson LS. Goldfrank's Toxicologic Emergency 8th ed. New York, McGraw-Hill; 2006. p.544-549.
- Heard KJ. Acetylcysteine for acetaminophen poisoning. N Engl J Med. 2008; 359:285-92.

Author Information

Cemil Kavalci, MD

Trakya University Faculty of Medicine, Emergency Department, Edirne/Turkey

Gülsüm Kavalci, MD

Trakya University Faculty of Medicine, Anesthesia Department, Edirne/Turkey

Eylem Sezenler, MD

Trakya University Faculty of Medicine, Emergency Department, Edirne/Turkey