

# Intramuscular Nodular Fasciitis in the Shoulder Probably Induced by Local Injections

T Chijiwa, T Tsuchihara, H Domoto, S Tsukazaki

## Citation

T Chijiwa, T Tsuchihara, H Domoto, S Tsukazaki. *Intramuscular Nodular Fasciitis in the Shoulder Probably Induced by Local Injections*. The Internet Journal of Plastic Surgery. 2006 Volume 3 Number 1.

## Abstract

We present herein a case of nodular fasciitis, intramuscular type, in the shoulder. A 44-year-old male complained of a hard mass in the anterior fibers of the deltoid muscle, where the lesion was isointense to skeletal muscle on T1-weighted and hyperintense to fat on T2\*-weighted MR images. This lesion, histologically and immunohistochemically confirmed as a nodular fasciitis of intramuscular type by an incisional biopsy, was excised in a simple procedure three months later. We hypothesized that repeated injections for bicipital tenosynovitis had triggered the occurrence of nodular fasciitis in this case.

## INTRODUCTION

Nodular fasciitis (NF) is a benign and quasi-neoplastic proliferation of fibroblasts that shows a rapid growth [1]. We describe a case of intramuscular NF that is rare when it occurs in the shoulder and that is probably induced by repeated local injections.

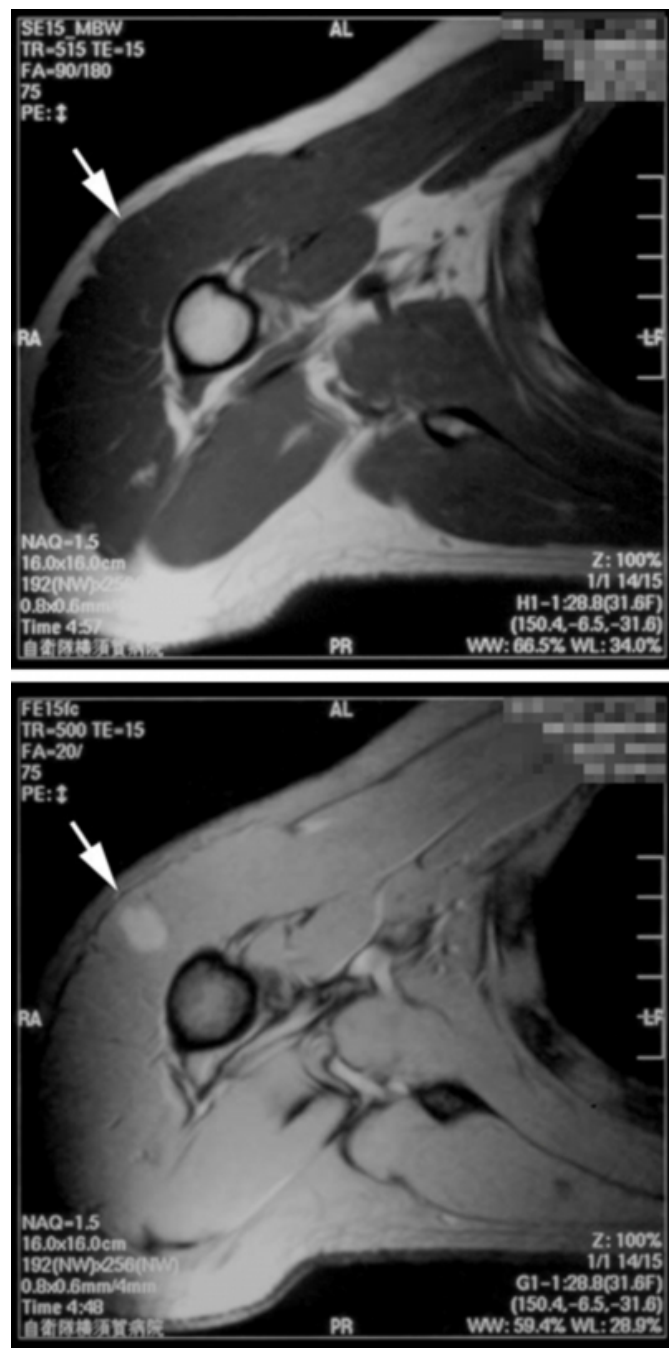
## CASE REPORT

A 44-year-old man complained of a severe painful mass in the right shoulder after having felt discomfort in the shoulder

for one month. For several months previously, this patient had been treated for bicipital tenosynovitis in that shoulder with rehabilitation and trigger point injection therapies using as corticosteroids, local anesthetics, and/or nonsteroidal anti-inflammatory drugs. The occurrence of the lesion or mass was exactly where those drugs had been injected. Magnetic resonance (MR) images disclosed a mass in the anterior fibers of the deltoid muscle that appeared to be isointense to skeletal muscle on T1-weighted and hyperintense to fat on T2\*-weighted MR images (Fig. 1AB).

**Figure 1**

Figure 1: MR images disclose an oval mass in the anterior fibers of deltoid muscle. It is isointense to skeletal muscle on T1-weighted (A) and hyperintense to fat on T2\*-weighted MR images (B). The internal intensity is uniform and the margin is unclear.



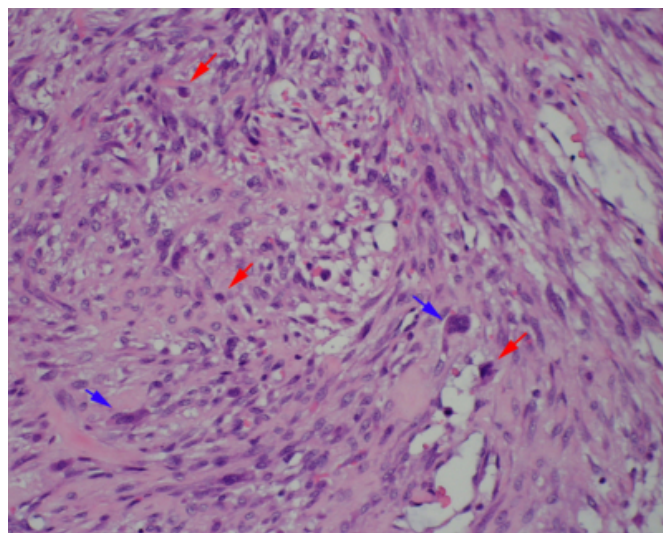
Ultrasonography showed a fusiform tumor which was of mixed echogenicity and 11mm across. Little vascular flow was seen inside the tumor. Preoperative routine laboratory data was unremarkable.

We performed an incisional biopsy under local anesthesia. Pathologically, this lesion was composed of spindle cells

with enlarged, vesicular, and uniform nuclei proliferating in short, irregular bundles and fascicles (Fig. 2).

**Figure 2**

Figure 2: Histological section, obtained from incisional biopsy, shows a random arrangement of spindle-shaped fibroblasts and an extravasation of red blood cells on a myxomatous background. Giant cells (blue arrows) or mitotic figures (red arrows) are also observed. (HE, x200)

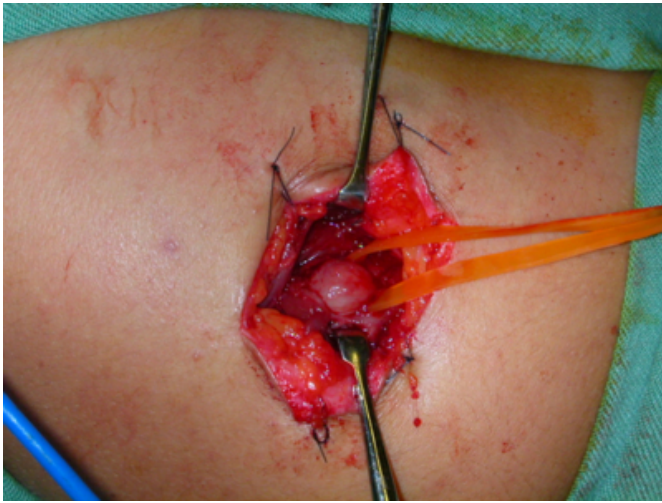


Mitotic figures, although not bizarre ones, were found in large numbers. The immunohistochemical analysis showed positive for -SMA and MIB-1 but negative for desmin, S-100, and p-53.

These findings were compatible with the diagnosis of NF of intramuscular type. In accordance with the patient's request, he was followed conservatively. Ultrasonic examinations were performed once a month, but no change in the echodensity and size of the tumor was seen. The patient, moreover, complained of continuous pain, and three months after the biopsy he finally underwent a total excision. The tumor was located in the anterior fibers of the deltoid muscle (Fig. 3).

### Figure 3

Figure 3: An operative finding is presented. The mass, which looks capsulated, is located inside the deltoid muscle. It is not easy to separate it from adhered muscle fibers.



It looked like it was capsulated but that its adhesion to muscle fibers was tight enough to prevent exfoliation of tumor. The tumor had a glossy, capsule-like surface and a solid inside of a light-yellow color. Compared with the previous findings, little histological alteration was observed. The final diagnosis of NF of the intramuscular type was made. The patient has been followed for over one year after the operation. Both the pain and the mass disappeared, and periodic ultrasonographs did not disclose a recurrence of the mass.

### DISCUSSION

Nodular fasciitis, also called pseudosarcomatous fasciitis, is a benign and quasineoplastic proliferation of fibroblast [1]. It is often difficult to differentiate from a sarcoma because of its rapid growth, rich cellularity, and mitotic activity. NF is considered to be a self-limiting, reactive process caused by local injury or else a localized inflammatory process [1]. The volar aspect of the forearm is the most common site, while its occurrence rate in the shoulder has been about 7% [2]. NF can be divided into three subtypes: a subcutaneous type, an intramuscular type, and a fascial type. The subcutaneous type is about four times more common than either the intramuscular or the fascial types [1]. Our case, the intramuscular type occurring in the shoulder, has been very rare.

Clinically, most patients with NF show a rapidly growing mass. In about a half of the cases, there is associated soreness, tenderness, or slight pain [1]. Various imaging studies cannot make any specific findings for NF except for

the locations [3]. Although MR images have generally given relatively distinct appearances of the lesion, they cannot help in differentiating NF from other soft tissue tumors. They are not sufficient to confirm such a diagnosis without a permanent histological section and/or immunohistochemical study. The progressive change of NF in MR appearances has been reported to be a sign that suggests a diagnosis of NF [4]. We performed periodic ultrasonography preoperatively to observe whether there might be an alternation in echodensity because progressive changes must be seen not only by MR but also by ultrasonography, which would also provide a cost advantage. However, the expected findings could not be observed in this case.

Most cases of NF have been effectively treated by local excision, while some lesions have been reported to subside conservatively [1, 5]. A recurrence happens in under 2% of all cases, usually soon after excision [1]. In the analysis of recurrent cases of primary diagnosed NF by Bernstein and Lattes, all of them were misdiagnosed and some malignant neoplasms were included [2]. Therefore, postoperative follow-up must be carefully performed. With our case the lesion was observed conservatively after biopsy because the patient had expected a spontaneous regression. However, the lesion did not regress. Histological findings on a surgical specimen disclosed mitotic figures in as large numbers as those in the initial biopsy.

There is little doubt that NF is triggered by a local inflammation, but the causes of this disease could be identified only in a few cases. Continuous stimulations from a splint [6] and a rifle butt [7] have been shown in published articles to cause NF. It has also been reported that a single injury from a laceration of the sole [8] and an epidural injection in the lumbar spine [9] might induce it. Thus not only continuous stimulation but also a single incident can trigger NF.

With our case the patient had suffered from a condition in his shoulder and had undergone repeated analgesic injections. One possible cause of NF in his case was that it was an extension of chronic bicipital tenosynovitis. Another possibility was that it was caused by repeated local injections inserted into the anterior shoulder where the NF grew afterwards. We believe that the latter is a more likely explanation because the lesion was located in the deltoid muscle, which was penetrated by needles, not in the bicipital muscle. Of the cases of NF we have found, two were reported to be iatrogenic [6, 9]. We have hypothesized that

direct injuries from needles and injections might contribute to the development of NF. It is unlikely that the drug effects contributed to it because injection of corticosteroids has been reported to resolve NF [5].

We presented a unique case of NF in its onset and development. NF possibly can occur iatrogenically. This should be kept in mind by surgeons in dealing with subcutaneous neoplasms.

## **References**

1. Enzinger, F. M., Weis, S. W.: Soft tissue tumors. 2nd ed. St Louis: Mosby Co; 1988. P102-12
2. Bernstein, K. E., Lattes, R.: Nodular (pseudosarcomatous) fasciitis; a nonrecurrent lesion; clinicopathologic study of 134 cases. *Cancer* 49: 1668-78, 1982. PMID: 6279273
3. Meyer, C. A., Kransdorf, M. J., Jelinek, J. S., et al: MR and CT appearance of nodular fasciitis. *J Comput Assist Tomogr* 15: 276-9, 1991. PMID: 2002108
4. Leung, L. Y., Shu, S. J., Chan, A. C., et al: Nodular fasciitis; MRI appearance and literature review. *Skeletal Radiol* 31: 9-13, 2002. PMID: 11807586
5. Graham, B. S., Barrett, T. L., Goltz, R. W.: Nodular fasciitis; response to intralesional corticosteroids. *J Am Acad Dermatol* 40: 490-2, 1999. PMID: 10071327
6. Kikuchi, I., Kuroki, Y.: Nodular fasciitis under a splint. *J Dermatol* 10: 89-91, 1983. PMID: 6345626
7. Dohler, J. R., Helbig, B.: Nodular fasciitis in sport shooting. *Z Orthop Ihre Grenzgeb* 123: 76-8, 1985. [in German] PMID: 3984473
8. Soule, E. H.: Proliferative (nodular) fasciitis. *Arch Pathol* 73: 437-44, 1962. PMID: 13915406
9. Wray, C. C., Macdonald, A. W.: Nodular fasciitis induced by epidural injection. *Postgrad Med J* 62: 881-3, 1986. PMID: 3809085

**Author Information**

**Tsuyoshi Chijiwa, M.D.**

Division of Dermatology and Plastic Surgery, Japan Self Defense Force Yokosuka Hospital

**Toyokazu Tsuchihara, M.D.**

Division of Orthopedic Surgery, Japan Self Defense Force Yokosuka Hospital

**Hideharu Domoto, M.D., Ph.D.**

Division of Laboratory Medicine, Japan Self Defense Force Yokosuka Hospital

**Satoshi Tsukazaki, M.D., Ph.D.**

Division of Orthopedic Surgery, Japan Self Defense Force Yokosuka Hospital