

Infantile Hyperplastic Gastric Polyps: A Rare Entity

S Sarji

Citation

S Sarji. *Infantile Hyperplastic Gastric Polyps: A Rare Entity*. The Internet Journal of Pediatrics and Neonatology. 2008 Volume 11 Number 1.

Abstract

Hyperplastic polyp of the stomach is generally a disease condition in adulthood, most cases in association with polyposis syndrome. Isolated infantile hyperplastic gastric polyp is an extremely rare condition and only a few cases are reported in the literature. Generally, gastric tumours are rare in children. When found, they are most often benign glandular, hyperplastic or pancreatic heterotopic polyps. The majority of gastric polyps arise from the antrum. The clinical presentations include symptoms of gastric outlet obstruction, haematemesis and hypergastrinaemia. We present another case of the rare benign infantile hyperplastic gastric polyps in a 6 month old boy, elegantly demonstrated by ultrasound and upper gastrointestinal contrast examination.

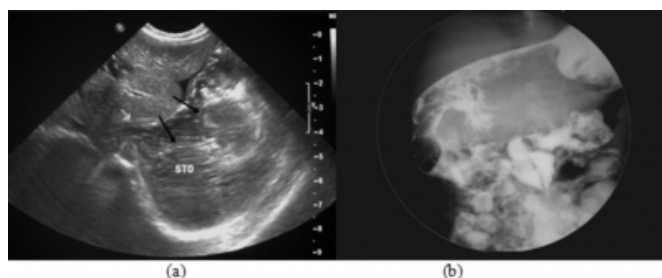
CASE REPORT

A 6-month-old boy presented with frequent episodes of regurgitation of feeds since birth. It was associated with vomiting which progressively increased in frequency. At the time of admission into our hospital, he presented with non-bilious projectile vomiting, with a frequency of more than 5 times per day and associated with one episode of haematemesis. On physical examination, the infant was pale and had a distended abdomen with visible peristaltic movement evident in the epigastric region. No mass was palpable per abdomen. A provisional diagnosis of hypertrophic pyloric stenosis was made at that time.

Blood investigation revealed a low haemoglobin level of 85 g/L, but the rest of full blood picture and biochemical results were within the normal range. Abdominal radiograph revealed a soft tissue density mass in the upper abdomen. Ultrasound examination showed a predominantly hypoechoic, lobulated gastric mass extending from the body to the antrum of the stomach (Figure 1a). An upper gastrointestinal contrast study using water soluble contrast revealed a grossly distended stomach with multiple large lobulated filling defects within it, representing gastric masses of uncertain nature (Figure 1b). There was flow of contrast into the duodenum and jejunum. There was no evidence of midgut rotation.

Figure 1

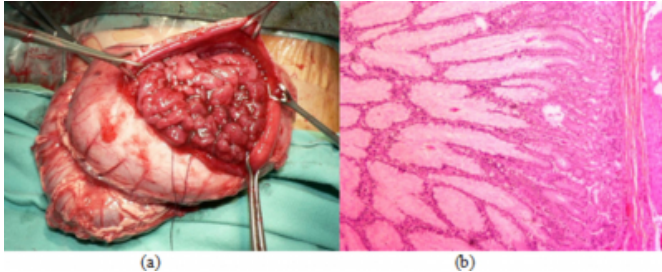
Figure 1 (a) Ultrasound showing lobulated masses (black arrows) in the body of the stomach (STO). The pylorus is indicated by the white arrow. (b) Contrast examination of the upper gastrointestinal tract showing filling defects in the body, antrum and pylorus of the stomach.



At laparotomy, there was a large polypoid gastric mass predominantly arising from the posterior wall of the body of stomach extending into the antrum and pyloric region (Figure 2a). Another polypoid mass was found in the pyloric region which acted as a ball-valve mechanism at the gastric outlet. A partial gastrectomy and gastroduodenectomy was performed. Histopathology of the gastric masses revealed hyperplastic villoglandular structures lined by tall mucin secreting columnar epithelium with basally located nuclei. The lamina propria contained smooth muscle fibres. There was no significant atypia or malignancy seen (Figure 2b). It was concluded that these were hyperplastic gastric polyps, with no dysplastic or neoplastic changes.

Figure 2

Figure 2 (a) Sectioned stomach wall during surgery showing large polypoid gastric tumours occupying the gastric cavity. (b) Histopathology of the tumour showing hyperplastic villoglandular structures lined by tall mucin secreting columnar epithelium with basally located nuclei in keeping with benign hyperplastic gastric polyps.



His postoperative recovery was uneventful. Feeding was initially given via a jejunostomy tube inserted during surgery with gradual increase in amount of feed. An upper gastrointestinal contrast study revealed no leakage from the anastomotic site. Oral feeding and breast feeding were subsequently commenced on day 11 post operation. He was well on discharge from the ward two weeks after surgery. On his most recent follow up visit in the paediatric surgery clinic he was thriving well, with satisfactory weight gain and tolerating feeds.

DISCUSSION

Apart from hypertrophic pyloric stenosis, other mass lesions in the stomach in the paediatric age group are rare. Gastric tumours include leiomyomas, leiomyoblastomas, leiomyosarcomas, lipomas, liposarcoma and neurofibromas. Adenomatous and hamartomatous polyps are usually associated with polyposis syndrome. Isolated infantile hyperplastic gastric polyp is an extremely rare condition and only a few cases are reported in the literature. When found, they are most often benign glandular, hyperplastic or pancreatic heterotopic polyps. Histologically, they are mucosal in origin and the hyperplastic and neoplastic forms are most common types [1]. This condition is sparsely reported in the literature. According to M. Stolte et al., hyperplastic polyp is a condition commonly affecting adults, particularly the elderly (average age 72 years old) [2].

The pathogenesis of sporadic gastric polyps in adults and children still remains uncertain. Abraham S. C. et al found that in adults with sporadic fundic gland polyps (FGPs) mutations of the β -catenin gene affecting the APC/ β -catenin pathway occurred and this may be involved in the pathogenesis of sporadic FGPs [3]. This mutated gene was

present in 91% of sporadic FGPs, which were also lacking in dysplastic morphology in histopathology examination [3]. Although there were limited cases in the paediatric age group, genetic sequencing is likely to be part of the investigation of this condition in the future.

Usually the polyps are small, less than 3cm in size [4]. Majority of gastric polyps arise from the antrum. The clinical presentations include haematemesis, hypergastrinaemia and gastric outlet obstruction largely related to their location and they may prolapse into the pylorus and the duodenum [4]. To our knowledge, there is no report of any case of hyperplastic polyp in infancy of such a large size with extensive involvement of the body, antrum and pylorus of the stomach as found in this case. Gastric polyps have been described in children receiving long term omeprazole therapy [5]. The differential diagnoses for gastric outlet obstruction in infants are infantile hyperplastic pyloric stenosis which usually presents earlier at 4 to 8 weeks of age and is the most common cause. Other considerations are duplication cysts, aberrant pancreatic tissue, antral web [6] and gastric tumours which commonly, are benign glandular, hyperplastic or pancreatic heterotopic polyps. It is important to be aware of these rarer causes of gastric outlet obstruction in infants. It has been reported that some of these infants had haematemesis and hypergastrinaemia together with the clinical presentation of gastric outlet obstruction. This was postulated to be related to isolation of the gastric mucosa from its usual acidic environment and exposed to an alkaline or neutral medium [1, 6]. Haematemesis in our patient can be explained by the presence of a polyp found in the pyloric region which acted as a ball-valve mechanism, causing obstruction to the gastric outlet. Exposure of the functional mucosa of this polyp in the alkaline media of the duodenum possibly resulted in continuous gastrin secretion and in turn hypergastrinaemia and erosion of the polyp leading to haematemesis [4].

Ultrasound appearance of a hyperplastic gastric polyp has been described as an echogenic polypoid mass arising from distal antral mucosa [6]. A similar condition, focal foveolar hyperplasia, may give appearance of a mass of similar echogenicity. In our case, the gastric polyps are enormous in size and multiple in number, appearing as masses of mixed echogenicity on ultrasound. Upper gastrointestinal contrast studies excluded hypertrophic pyloric stenosis and the presence of lobulated filling defects in the stomach was highly suggestive of tumour. Endoscopic and biopsy as well as removal of gastric polyps can be performed at the same

setting [4]. However, in infants it has not been described, due to difficulty or non-availability of a scope of appropriate size. In this case, endoscopic polypectomy was not possible due to the severe gastric outlet obstructive symptoms and extensive involvement demonstrated on imaging studies.

In conclusion, a rare case of infantile hyperplastic gastric polyp which was clinically diagnosed as hypertrophic pyloric stenosis is presented. Both ultrasound and upper gastrointestinal contrast study was useful in demonstrating intraluminal gastric masses. We highlight this rare condition to raise clinical awareness among paediatricians and radiologists to consider the possibility of gastric polyps as a cause of gastric outlet obstruction and vomiting in an infant.

References

1. Brooks G. S., Frost E. S., Wesselhoeft C. Prolapsed Hyperplastic Gastric Polyp causing Gastric Outlet Obstruction, Hypergastrinemia, and Hematemesis in an Infant. *Journal of Pediatric Surgery* 1992; 12: 1537-1538.
2. Stolte M., Sticht T., Eidt S., Ebert D., Finkenzeller G.. Frequency, Location and Age and Sex Distribution of various Types of Gastric Polyp. *Endoscopy* 1994; 26: 659-665.
3. Abraham S. C., Nobukawa B, Giardiello F. M., Hamilton S. R., Wu TT. Sporadic Fundic Gland Polyps. Common Gastric Polyps Arising through Activating Mutations in the β -Catenin Gene. *American Journal of Pathology* 2001; 158: 1005-1010.
4. Alper M., Akcan Y., Belenli O. Large pedunculated antral hyperplastic gastric polyp traversed the bulb causing outlet obstruction and iron deficiency anemia: endoscopic removal. *World J Gastroenterol* 2003; 9(3):633-634.
5. Pashankar D. S. and Israel D.M. Gastric Polyps and Nodules in Children Receiving Long-Term Omeprazole Therapy. *Journal of Pediatric Gastroenterology and Nutrition* 2002; 11(35):658-662.
6. Kim S., Chung C. J., Fordham L. A., Specter B. B. Coexisting hyperplastic antral polyp and hypertrophic pyloric stenosis. *Pediatr Radiol* 1997; 27: 912-914.
7. McAlister W. H., Katz M. E., Perlman J. M. and Tack E. D. Sonography of focal foveolar hyperplasia causing gastric obstruction in an infant. *Pediatr Radiol* 1988; 18: 79-81.

Author Information

Sazilah Ahmad Sarji

Department of Biomedical Imaging University of Malaya Medical Centre 59100 Kuala Lumpur, MALAYSIA