

Compressive Cervical Myelopathy Due To Sirsasana, A Yoga Posture: A Case Report

P Sethi, A Batra, N Sethi, J Torgovnick, E Tortolani

Citation

P Sethi, A Batra, N Sethi, J Torgovnick, E Tortolani. *Compressive Cervical Myelopathy Due To Sirsasana, A Yoga Posture: A Case Report*. The Internet Journal of Neurology. 2006 Volume 6 Number 1.

Abstract

Yoga is rapidly gaining popularity in the West as a form of exercise and mental relaxation. Yoga meaning "union" is an ancient Indian philosophy of life, practiced initially by the Sadhu's (holymen of India) that encourages the union of the mind, body and spirit. Recent research has shown that done under proper supervision, it improves muscle strength, coordination, flexibility, decreases blood pressure, slows the respiratory rate thus improving cardiovascular function. It also reduces stress and anxiety by promoting the release of endorphins, the body's natural pain-killers.

Like any other mode of exercise, complications and injuries can occur if yoga is not practiced under proper supervision. We report here a case of compressive cervical myelopathy as a result of "Sirsasana" (headstand), a common yoga posture.

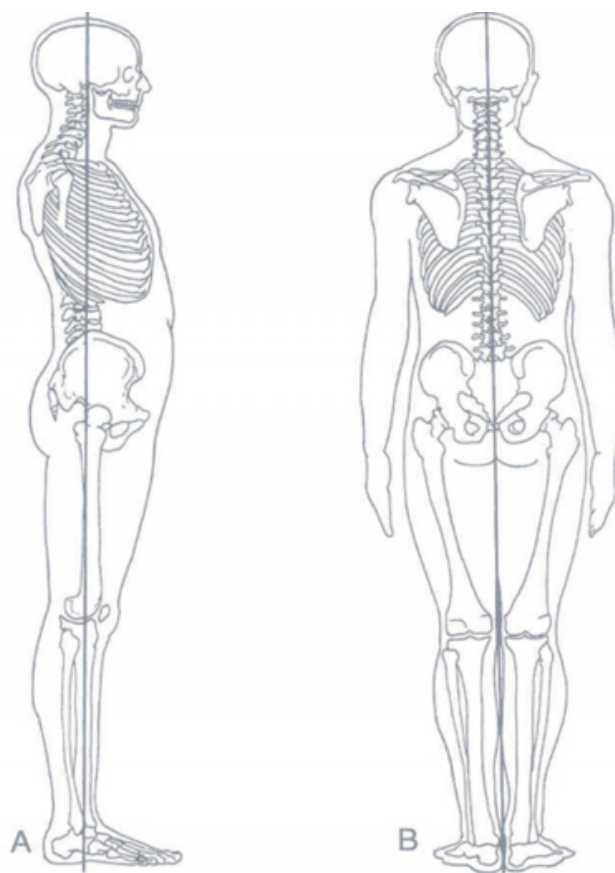
CASE REPORT

INTRODUCTION TO SPINAL BIOMECHANICS

The upright human posture is the result of a complex biomechanical interaction between the spinal column and the earth's gravitational forces. The spine is a dynamic organ of posture that serves three basic functions namely transmit the load (organisms weight), allow for movements (flexion, extension, rotation and lateral bending) and above all to protect the delicate spinal cord.

Figure 1

Figure 1: Showing plumb line in lateral & posterior aspects.



To maintain equilibrium in standing position with least energy expenditure, the articulated parts of spinal column

and lower limbs must be aligned with respect to the center of gravity. For postural alignment a “PLUMB LINE”₁ representing the gravity line passes through bodies of lumbar and most of the cervical vertebrae. The human spine is not straight; it has curves, which gives it flexibility and shock absorbing capacity. The curvature of vertebral column increases its resistance to axial compression forces. Biomechanically, the resistance of a curved column is directly proportional to square of the number of curves plus one ($n^2 + 1$). When applied to human spine, the curved spine has 10 times the stability of a straight spine ($3^2 + 1$ or $9 + 1 = 10$)₂. A 63-year old male presented with history of tingling & numbness in finger and toes for the last 5 months followed by weakness and stiffness in all the four limbs with frequency and urgency of urination for past one month. There was no history of trauma either to the neck or back. For the last 25 years, he had been doing sirsasana (headstand) daily. Examination revealed spastic quadriparesis with a sensory level at C4. X-ray cervical spine lateral view revealed anterolisthesis at C4-C5 with block vertebra at C5-C6. Magnetic resonance imaging (MRI) of the cervical spine showed cervical cord compression at C3-C4, C4-C5.

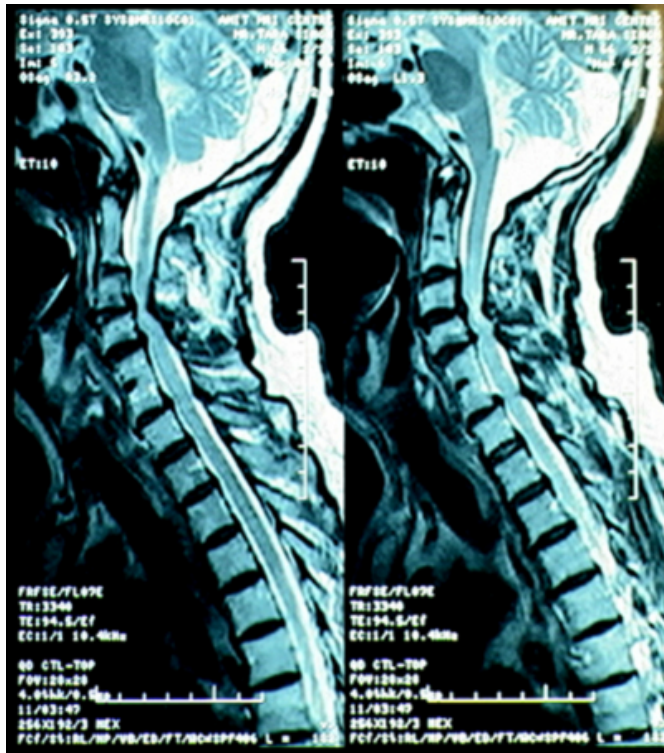
Figure 2

Figure 2: X-ray cervical spine lateral view in extreme flexion showing anterolisthesis at C4-C5 with C5&C6; block vertebra.

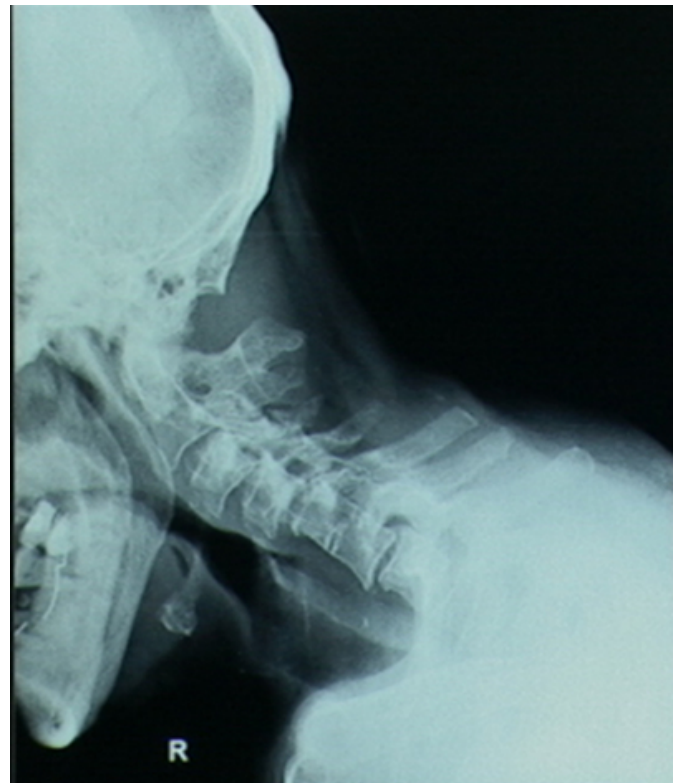

Figure 3

Figure 3: MRI cervical spine sagittal T2W image showing cervical cord compression at C3-C4, C4-C5.



DISCUSSION

Sirsasana is one of the most important yoga asanas, referred to as the “King” of all asanas. It is performed by kneeling down and resting the elbows firmly on the floor, interlocking the fingers together in front so as to form a triangular base with the forearms. Placing the very top of the head in between the interlocked hands and walking the feet slowly closer towards the chest, then lifting the toes off the floor while tucking the knees into the chest. Once balanced at this stage, the folded knees are raised up gradually. Once again balance is achieved and the feet are worked up straight. The key is to press the forearms down so that there is little weight on the head. This posture is initially held for a minute, working up to 5 minutes. Coming down is accomplished in the same manner as going up. Every step should be carefully performed to avoid injuries. In an erect posture the gravity line passes through the bodies of most of the cervical and lumbar vertebrae, which bear weight and allow for movements of the spinal column. So while

performing Sirsasana (head stand), it is possible that the load instead of passing through the bodies of the vertebrae, is transmitted through the weaker portions of vertebral column disturbing the normal spinal biomechanics. Normally the flexion/extension movement in cervical spine takes place at C5-C6. As this joint was fixed in our patient, possibly the movements were taking place at a higher joint. This predisposition and the disturbed mechanics due to Sirsasana predictably resulted in cervical listhesis and compressive myelopathy in our patient. Yoga must be performed with caution in certain situations like pregnancy and by people with physical disabilities. Some postures need to be avoided e.g. those with uncontrolled hypertension, should avoid upside-down postures (headstands and shoulder stands) as it may potentially increase the risk of stroke. Vertebral artery and basilar artery occlusions and dissections have been reported^{3, 4}, as have thoracic outlet syndrome and cervical reticuloses with inverted postures. Yoga may cause retinal hemorrhages and detachment in glaucoma patients⁵. People with disc problems should avoid back bending postures. Our case emphasizes that headstands can have potential risks and that proper supervision and care should be exercised prior to embarking on a yoga exercise schedule. Further more physicians and physiotherapists need to be aware of this potentially serious complication of a relatively innocuous exercise like Yoga.

CORRESPONDENCE TO

Nitin Sethi, MD Comprehensive Epilepsy Center Weill Cornell Medical Center New York, NY 10021 Email: sethinitinmd@hotmail.com

References

1. Kapandji IA: The physiology of joints, ed 2. London. Churchill Livingstone, 1974, vol 3, p 20.
2. David M. Panzer, Scot G. Fechtel, Meridel I. Gatterman. Postural Complex in Chiropractic Management of Spine Related Disorders. Williams & Wilkins, London, 1990, p 263.
3. Hanus, S.S., et al. Vertebral artery occlusion complicating yoga exercises. Arch Neurol, 1977, 34(9):574-575.
4. Fong, K.Y., R.T. Cheung, Y.L. Yu, C.W. Lai, and C.M. Chang. Basilar artery occlusion following yoga exercise: A case report. Clin Exp Neuro (Australia), 1993, 30:104-109
5. Editors of Yoga Journal. [On retinal detachment, glaucoma, and inversions]. Yoga Journal, Nov/Dec 2000, p.52.

Author Information

P. K. Sethi

Department Of Neurology, Sir GangaRam Hospital

A. Batra, M.D.

Department Of Neurology, Sir GangaRam Hospital

N. K. Sethi, M.D.

Weill Cornell Medical Center

J. Torgovnick, M.D.

Saint Vincent's Hospital and Medical Centers

E. Tortolani

Yoga instructor