

# Ectopic Pregnancy In A Previous Cesarean Section Scar: A Case Report

A Yalinkaya, O Yalinakay, G Olmez, M Yayla

## Citation

A Yalinkaya, O Yalinakay, G Olmez, M Yayla. *Ectopic Pregnancy In A Previous Cesarean Section Scar: A Case Report*. The Internet Journal of Gynecology and Obstetrics. 2003 Volume 3 Number 1.

## Abstract

**Objective:** The aim of this study is to evaluate an ectopic pregnancy developing in a previous cesarean section scar.

**Case:** A 38 year-old woman was referred at eight weeks, due to ectopic pregnancy. Three years before she had undergone cesarean section. She needed a reoperation because of dehiscence. However, an incisional hernia reoccurred. The incisional hernia was repaired with prolene mesh six months ago. The ectopic pregnancy was diagnosed by transvaginal ultrasound at eight weeks of viable fetus with intact and irregular gestational sac in the previous cesarean scar. A laparotomy was performed.

**Conclusion:** The ectopic pregnancy within the scar of a previous cesarean delivery is the best diagnosed by transvaginal ultrasound. However, a delay in either diagnosis or treatment can lead to uterine rupture, hysterectomy, and significant maternal morbidity. As soon as the diagnosis is confirmed, primer surgical treatment by laparotomy should be recommended.

## INTRODUCTION

The implantation of a pregnancy within the scar of a previous cesarean delivery is the rarest form of ectopic pregnancy. A computer Medline and bibliography search has yielded only 26 cases reported in the English language from 1966 through March 2003. If the early diagnosis has been made, treatment options are capable of preserving the uterus and subsequent fertility. However, a delay in either diagnosis or treatment can lead to uterine rupture, hysterectomy, and significant maternal morbidity. Although expectant and medical managements have been reported, termination of a cesarean scar pregnancy by laparotomy and hysterotomy, with repair of the accompanying uterine scar dehiscence, may be the best treatment option (1,2).

## CASE

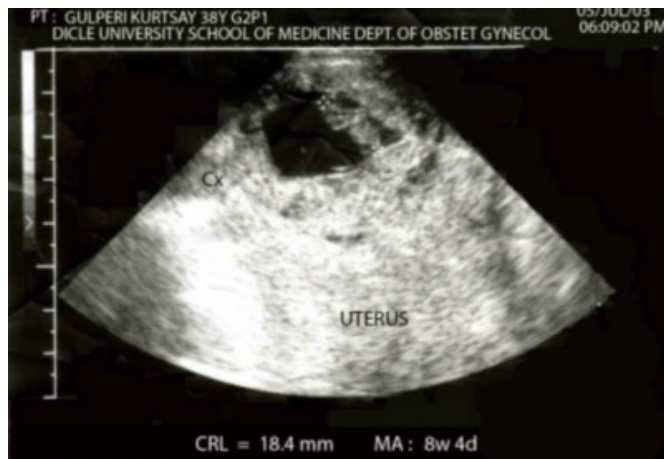A 38 year-old woman gravida 2, para 1, was referred to our clinic, due to ectopic pregnancy. The patient had undergone cesarean section three years ago. Earlier postoperative reoperation was made, due to dehiscence of the abdominal fascia, then an incisional hernia and fascial defect reoccurred. The fascial defect and hernia was repaired with prolene mesh and the patient was advised to avoid pregnancy for 18 months. However, six months after the last operation she visited a gynecologist because of suspicion of

pregnancy and was referred to our clinic with suspected abdominal ectopic pregnancy. On examination, there were no clinical findings or symptoms such as abdominal pain and vaginal bleeding. The uterus was not enlarged and mild tender and the cervix closed. We could not detect an ectopic pregnancy by transabdominal ultrasound due to the prolene mesh in the abdominal wall. A transvaginal ultrasound scan revealed a retrovert, normal uterine size, and the empty uterine cavity, and showed a pregnancy located in the isthmic region. Since the gestational sac was displaced anteriorly, the possibility of ectopic implantation in the previous cesarean section scar was considered. A 40x35 mm irregular gestational sac, 5 mm yolk-sac, crown-rump length (CRL) 18.4 mm and 8 weeks 4 day a viable fetus were detected. No fluid was seen in the cul-de-sac. The serum human chorionic gonadotrophin level was 12350 IU/mL. A diagnosis of a viable pregnancy in a uterine scar was made. Due to the prolene mesh in the abdominal wall, we preferred the laparotomy instead of other treatment methods. A laparotomy was performed with Pfannenstiel incision under general anesthesia. Approximately, 40-50 mm size of gestation was detected on anterior uterine under the peritoneum. The gestation was dissected from the anterior uterine isthmus. The implantation of the ectopic pregnancy had been caused by dehiscence of the previous cesarean section

scar. The gestation was dissected from the anterior uterine isthmus, and the cesarean dehiscence was repaired. The patient had an uneventful postoperative recovery and was discharged from the hospital on postoperative day 3.

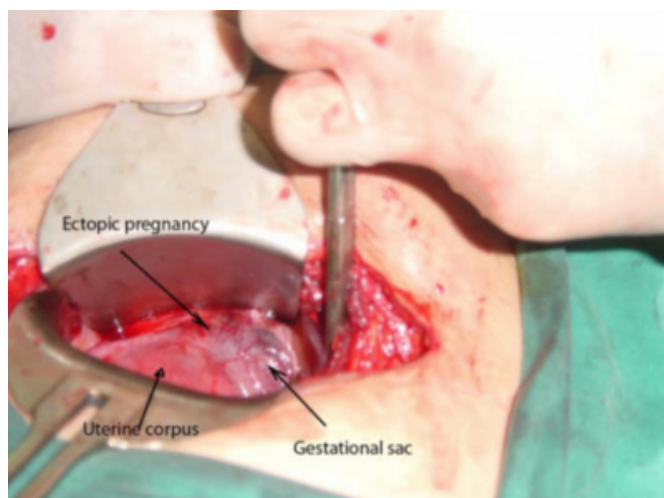
### Figure 1

Figure 1. An ectopic pregnancy within the previous cesarean section scar is demonstrated by transvaginal ultrasound.



### Figure 2

Figure 2. An ectopic pregnancy within the previous cesarean section scar is demonstrated during laparotomy.



## DISCUSSION

Endometrial and myometrial disruption or scarring can predispose to abdominal pregnancy implantation (1). Although cesarean delivery is a very common procedure, implantation of a pregnancy within a scar is a very rare occurrence. However, without a high index of suspicion and early diagnosis with transvaginal sonography, like other ectopic pregnancies, this abnormal implantation can lead to rupture and produce significant maternal morbidity and loss of future fertility. The rupture can occur early in gestation

and a delay in diagnosis potentially limits conservative treatment option (2). Rarely, such a pregnancy may be carried to the advanced stage of 35 weeks of gestation without endangering the patient. This reported pregnancy was terminated by hysterectomy when profound hemorrhage and disseminated intravascular coagulopathy developed during an emergency cesarean section. Transvaginal sonography facilitates diagnosis of location, gestational age, size and viability of an ectopic pregnancy within a uterine scar (3).

Because of the rarity of cesarean section scar pregnancy, the optimal treatment has not been established. A variety of surgical and non-surgical interventions have been proposed in order to terminate the ectopic pregnancy while preserving. Invasive measures divide roughly into intralesional injection, dilatation and curettage, and lesional excision. A review of the English literature reveals a variety of complications associated with these treatments. Curettage seems contraindicated because the trophoblastic tissue is outside the uterine cavity and can result potentially in a rupture of the uterine scar implantation and hemorrhage (4).

Godin et al. described a transvaginal injection of potassium chloride into the fetal thorax and methotrexate (MTX) to the sac and surrounding myometrium of a 9-week viable pregnancy in an existing uterine scar. Complete resolution of the pregnancy was observed. However, dehiscence of the uterine scar was noted 16 weeks later by hysterosalpingography (5). In the case reported by Lai et al. two weeks after endovaginal sonography-guided intralesional delivery of MTX into an ectopic gestational sac, an emergency laparotomy was performed at the onset of active vaginal bleeding from the ruptured uterine scar (6). Haimov-Kochman R et al. suggested that non-invasive therapy should be considered in suitable cases of cesarean scar ectopic pregnancy. In cases discovered at no more than 6-8 week's gestation without fetal cardiac activity, MTX delivery and expectant management may be a safe treatment alternative (4).

Non-surgical treatment options (which include systemic and local MTX, potassium chloride, and hyperosmolar glucose) even when successful could be expected to leave the uterine scar defect that will accompany cesarean scar implantation. The potential for an unprepared scar dehiscence that will affect future pregnancies is left to speculation. Surgical resection, in this case, offered the opportunity to remove the pregnancy and to repair the defect simultaneously. As soon

as the diagnosis is confirmed, primer surgical treatment by laparotomy should be recommended.

### **CORRESPONDENCE TO**

Ahmet Yalinkaya, MD. Dicle University School of Medicine, Department of Obstetrics and Gynecology, Diyarbakir, Turkey. Telephone Number: +90412 2286146 Fax: +90412 2488520 E-mail Address: ayalinkaya@dicle.edu.tr and ahmetyalinkaya@superonline

### **References**

1. Fylstra DL, Pound-Chang T, Miller MG, Cooper A, Miller KM. Ectopic pregnancy within a cesarean delivery scar: a case report. *Am J Obstet Gynecol* 2002;187:302-4
2. Fylstra DL. Ectopic pregnancy within a cesarean scar: a review. *Obstet Gynecol Surv* 2002;57:537-43
3. Herman A, Weinraub Z, Avrech O, Maymon R, Ron-El R, Bukovsky Y. Follow up and outcome of isthmic pregnancy located in a previous caesarean section scar. *Br J Obstet Gynaecol* 1995;102:839-41
4. Haimov-Kochman R, Sciaky-Tamir Y, Yanai N, Yagel S. Conservative management of two ectopic pregnancies implanted in previous uterine scars. *Ultrasound Obstet Gynecol* 2002;19:616-9.
5. Godin PA, Bassil S, Donnez J. An ectopic pregnancy developing in a previous caesarian section scar. *Fertil Steril* 1997;67:398-400.
6. Lai YM, Lee JD, Lee CL, Chen TC, Soong YK. An ectopic pregnancy embedded in the myometrium of a previous cesarean section scar. *Acta Obstet Gynecol Scand* 1995;74:573-6.

**Author Information**

**Ahmet Yalinkaya, MD**

Assistant Professor, Department of Obstetrics and Gynecology, Dicle University School of Medicine

**Omer Yalinakay, MD**

Assistant Doctor, Department of Obstetrics and Gynecology, Dicle University School of Medicine

**Gonul Olmez, MD**

Assistant Professor, Department of Anesthesiology and Reanimation, Dicle University School of Medicine

**Murat Yayla, MD**

Professor, Department of Obstetrics and Gynecology, Dicle University School of Medicine