

Pyometro Colpos With Low Vaginal Atresia In Ellis –Van Creveld Syndrome

A Arumugam, S Sarji

Citation

A Arumugam, S Sarji. *Pyometro Colpos With Low Vaginal Atresia In Ellis –Van Creveld Syndrome*. The Internet Journal of Pediatrics and Neonatology. 2008 Volume 11 Number 1.

Abstract

Ellis van Creveld (EVC) syndrome or chondroectodermal dysplasia has features which include polydactyly, congenital heart disease, short limbs, short ribs and chest constriction. We report a rare occurrence of vaginal atresia who presented with pyometrocolpos in a young female child with this syndrome. This case demonstrates the presence of a rare additional finding in EVC syndrome, creating an overlap with McKusick-Kaufman syndrome (MKS) where hydrometrocolpos, polydactyly and congenital heart disease are known cardinal features.

CASE REPORT

A 17 month old girl presented to the Emergency Department with abdominal pain and distension. She was born premature at 28 weeks and is an only child. There is no history of consanguinity and her parents are not dysmorphic. She is a known case of Ellis-Van Creveld syndrome and the features present in her are mesomelic dwarfism, polydactyly of both hands and her right foot, dysplastic nails, cleft lip, abnormal frenulae, a small rib cage and hypoplasia of the left lung and an asymptomatic atrial septal defect. During the neonatal period, she developed neonatal pneumonia which required ventilation and slow recovery. A cleft lip reparative surgery was done at the age of one month to enable her to feed orally. She had been having recurrent episodes of respiratory infections throughout infancy. Developmentally, there is overall delay in her physical development. She was only able to crawl and at 17 months, her height and weight is at the 50th centile for age.

At the time of presentation, her mother complained that she had developed abdominal colic and foul smelling diarrhoea. There was no associated vomiting. On examination, she was febrile and her lower abdomen was distended, tender and firm on palpation. The liver and spleen were not palpable. Per rectal examination was normal. Blood investigations revealed a leucocytosis of 15,000/uL. Renal function was normal. Stool examination for ova and cysts were negative.

Ultrasound of the abdomen revealed a well defined pear shaped mass measuring 12 cm in length, 11 cm wide and 7

cm in antero-posterior diameter, arising from the pelvis, posterior to the urinary bladder and anterior to the rectum with mixed echogenicity and a fluid-fluid level within it (Fig 1). The mass extended inferiorly into the perineum. A normal uterus was not visualized. Her ovaries were not seen. The impression was that this mass was a distended uterus and vagina. The kidneys, liver and spleen were normal. There were no enlarged lymph nodes. No free fluid was detected.

CT scan of her abdomen and pelvis confirmed the mass to be a hydrometrocolpos (Fig 2).

Figure 1

Figure 1. Ultrasound of the abdomen showing a pear shaped structure with thick walls arising from the pelvis, situated posterior to the urinary bladder and anterior to the rectum. There are mixed echoes (white arrows) within it.

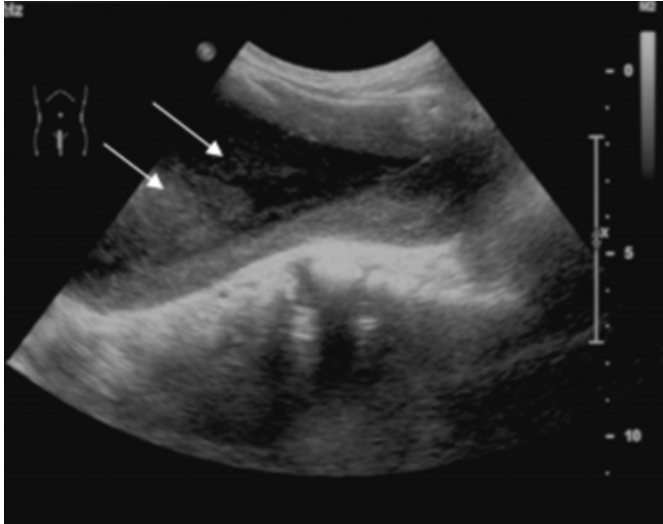
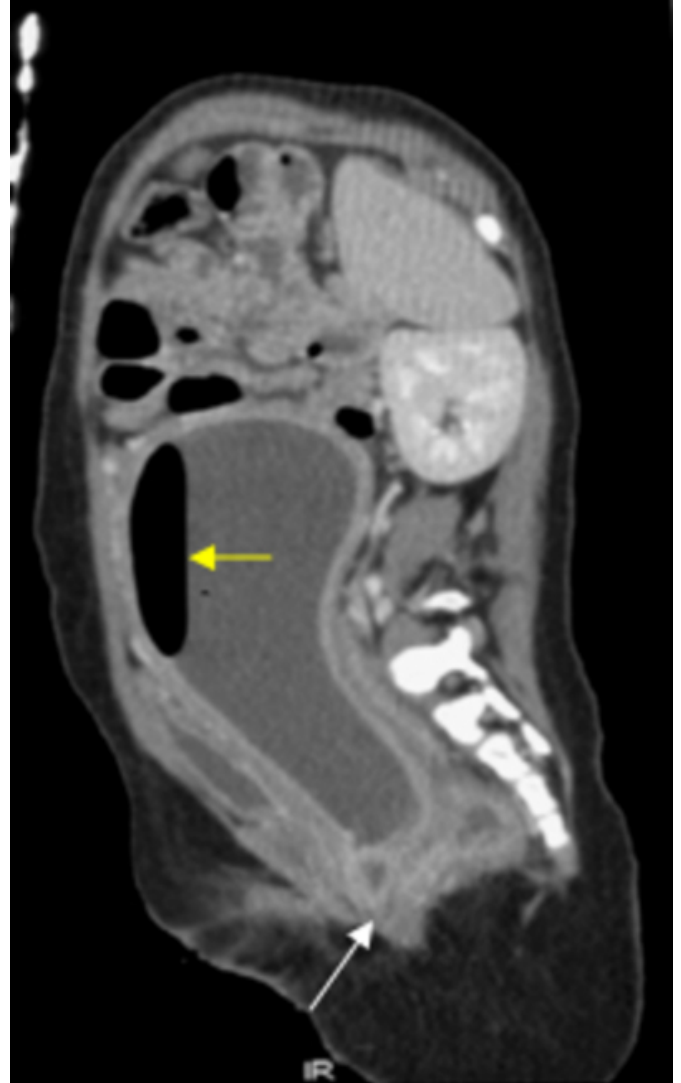


Figure 2

Figure 2. CT scan of her abdomen and pelvis (sagittal reformat) showing an enlarged pear shaped fluid filled mass with an air fluid level (yellow arrow) in keeping with an infected hydrometrocolpos. The vaginal appears atretic (white arrow).



On reviewing her skeletal survey, radiographs of her feet revealed a bifid metatarsal and her hands showed extra metacarpal bones and complete duplication of her little fingers. (Fig 3 a). Radiograph of her chest and abdomen showed a narrow thorax with short ribs, and her pelvis showed squared iliac wings with horizontal acetabuli (Fig 3b).

Figure 3

Figure 3 (a) Radiograph of her feet and hands showing bifid metatarsals (right foot) , extra metacarpals (left hand) and polydactyly (both hands and right foot)

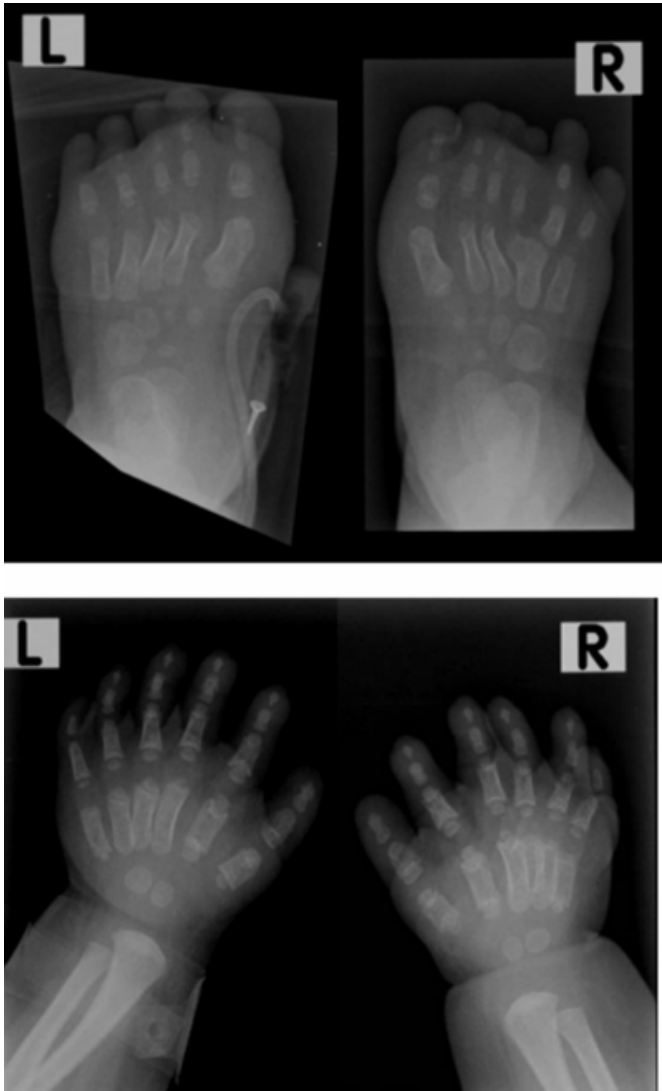
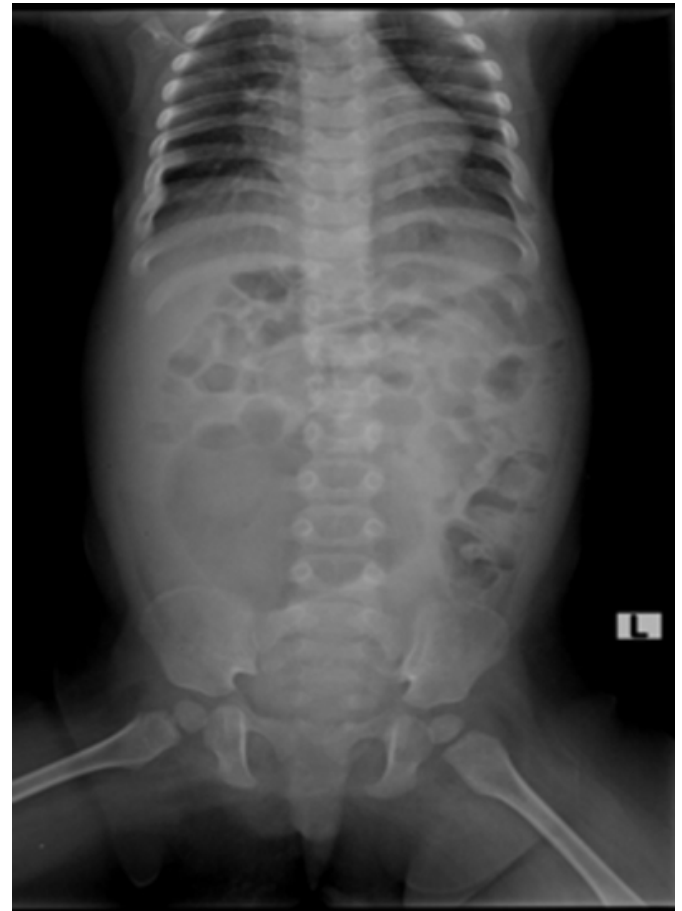

Figure 4

(b) Radiograph of her chest and abdomen showing short ribs and a narrow thorax and her pelvis showing squared iliac wings with horizontal acetabuli.



She underwent laparotomy and the uterus and vagina was found to be markedly distended with thick inflamed walls and was filled with foul smelling putrid watery pus. A low vaginal atresia was found to be the cause of the pyometrocolpos. The fallopian tubes and ovaries were normal. There was no spillage of pus into the peritoneal cavity. Following a vaginal washout, a Raffensperger pull through procedure of the vagina was performed. Post operatively, the child required assisted ventilation for 4 days in intensive care unit and recovered uneventfully. She remains well.

DISCUSSION

Hydrometrocolpos is a distension of the uterus (metro) and vagina (colpos) caused by obstruction to drainage of the genital secretions. The spectrum of hydrometrocolpos is broad, ranging from cases undetected until menarche in adolescents to those cases associated with congenital conditions in newborns or infants. In the latter, agenesis or atresia of the vagina or cervix is responsible for the

obstruction. By 8 weeks gestation, the paramesonephric (mullerian) ducts normally meet in the midline to form the uterovaginal canal and this develops into the uterus, cervix and approximately three fourths of the proximal vagina. The sinovaginal bulbs of the primitive urogenital sinus (vaginal cord) form the distal vagina. Atresia of the lower vagina is attributed to failure of recanalization of the vaginal cord at the 150 mm crown-rump stage. It may take the form of a septum in any plane and at any level, including the site of the hymen, or it may take the form of a stenosis. The term vaginal atresia is used for cases where there is more than just a simple thin imperforated hymen (1). The inheritance of müllerian defects is likely to be polygenic or multi-factorial, although some syndromes of heritable disorders are described with associated genital and non genital anomalies. Therefore, although most cases of hydrometrocolpos are sporadic, it may be part of an autosomal recessive condition, known as McKusick-Kaufman syndrome (MKS). MKS is an autosomal recessive disorder characterized by the triad of hydrometrocolpos, post axial polydactyly and congenital heart disease. Hydrometrocolpos and its association with the syndrome is well described in the literature. MKS must be differentiated from the Ellis Van Creveld (EVC) syndrome, which also includes polydactyly and congenital heart disease, but is associated with chondrodysplasia and ectodermal dysplasia (2). Here we describe the occurrence of pyometrocolpos secondary to vaginal atresia in a child with EVC syndrome. To our knowledge, there is only one report of vaginal atresia and hydrometrocolpos at birth which required surgery in the neonatal period in a baby with EVC syndrome described by Digilio et al in 1997. Thus the association of hydrometrocolpos with EVC syndrome is rare.

Ellis-Van Creveld syndrome or chondroectodermal dysplasia, is a tetrad of chondrodysplasia, ectodermal dysplasia, polydactyly and congenital heart disease (ASD or a single atrium). Chondrodysplasia of the tubular bones is the most common feature while CNS and urinary tract anomalies are rarer associations (3). The mode of inheritance is autosomal recessive, associated with mutations in two non homologous genes, both located at chromosome location 4p16 (EVC gene) (4). A high prevalence of EVC syndrome has been reported among certain populations like the old order Amish population of Pennsylvania (5). The radiological features of EVC are delayed skeletal maturation, short acro/ mesomelic limbs, delayed fusion of sutures with large fontanelles, narrow chest with short ribs, small pelvis with flared iliac bones, short sacrosciatic notches, premature ossification of the femoral head epiphyses, proximal tibial

metaphyses/epiphyses, genu valgum, pre and postaxial polydactyly and terminal hypoplasia of the fingers, fused carpal bones, slanting and cone shaped epiphyses. Our patient had bifid 5th metacarpals and complete duplication of her little fingers, short ribs, a small chest and a small pelvis with squared iliac wings and horizontal acetabuli. These features support that EVC syndrome is mainly a generalized disorder of the maturation of enchondral ossification (6). Approximately 60% of EVC patients are affected by congenital heart disease and common cardiac defects are ventricular or atrial septal defects and a single atrium. In EVC syndrome, pathognomonic oral and dental manifestations are present. These include abnormal frenulae, delayed eruption of teeth, anodontia, oligodontia, microdontia, abnormal tooth position and shape (7). Ectodermal manifestations include fine hair and absent or thin dysplastic/hypoplastic, discoloured nails of the fingers and toes.

Diagnosis of EVC syndrome in our patient was based on the clinical and radiological features described which were present in her. Differential diagnosis is made with Jeunés syndrome or asphyxiating thoracic dystrophy and MKK syndrome. The thoracic cage deformity is usually not so pronounced in EVC syndrome and in Jeunes syndrome, death occurs early in neonatal period from severe respiratory complications. Jeunes syndrome is also distinguished from EVC by the absence of ectodermal dysplasia, cardiac defects and dental anomalies. EVC and MKK syndrome are clinically similar, but clinical dwarfism due to osteochondrodysplasia and ectodermal anomalies are seen in EVC syndrome. In the rare occurrence of vaginal atresia as in our case of EVC syndrome, the explanation could lie in the course of early development of the genital tract and the skeleton as the syndrome involves all embryonic tissue layers. The lining of the urethra and urinary bladder is derived from endoderm and the urogenital sinus forms the urethra and vestibule in females. The ectoderm fuses with the endoderm to contribute to patency and canalization of the genital tract. Defects in this process lead to fusion failures and imperforate and obstruction defects. The skeleton, like the mesonephros is also derived from the mesoderm. At about the same stage of development when the embryonic defect in the genitourinary tract occurs, the skeleton develops from adjacent mesodermal cell concentrations and thus may also be damaged.

In summary, we highlight a case of isolated low vaginal atresia leading to infected hydrometrocolpos occurring in a

classical case of chondroectodermal dysplasia where chondrodystrophy of the tubular bones and ectodermal manifestations were the predominant features. There were no other genitourinary abnormalities. Prompt diagnosis by imaging studies and recognition of the underlying condition prevented further complication of spillage of the infected contents of the uterus and vagina into the peritoneal cavity which could have resulted in increased mortality and morbidity in this child.

References

1. Shaw MLA, Jones WA, Brereton RJ. Imperforate hymen and vaginal atresia and their associated anomalies. Journal of Royal Society of Medicine 1983.Vol 76; 560-566.
2. Castel Y, Toudic L, Alix D,et al. Postaxial polydactyly in a female neonate associated with hydrocolpos due to vaginal atresia and with a congenital cardiopathy: the McKusick-Kaufman syndrome. J Genet Hum 1982 Nov; 30(4):329-337.
3. Arya L, Mendiratta V, Sharma RC, et al. Ellis – van Creveld syndrome: a report of two cases. Pediatr Dermatol 2001 Nov-Dec; 18(6):485-489.
4. Polymeropoulos MH, Ide SE, Wright M, et al. The gene for the Ellis-van Creveld syndrome is located on chromosome 4p16. Genomics 1996; 35:1-5.
5. McKusick VA, Egeland JA, Eldridge R, et al. Dwarfism in the Amish. The bulletin of the John Hopkins Hospital 1964; 115:306-336.
6. Sergi C, Voigtlander T, Zoubaa S, et al. Ellis-van Creveld syndrome: a generalized dysplasia of enchondral ossification. Pediatr Radiol 2001 Apr; 31(4):289-193.
7. Varela M, Ramos C. Chondroectodermal dysplasia (Ellis-van Creveld syndrome): a case report. Eur J Orthod. 1996 Aug; 18(4):313-8.

Author Information

Allirani Arumugam, MD, MRad (UM)

Department of Biomedical Imaging University of Malaya Medical Centre 59100 Kuala Lumpur MALAYSIA

Sazilah Ahmad Sarji, MBBS (Mal), FRCR (Lond)

Department of Biomedical Imaging University of Malaya Medical Centre 59100 Kuala Lumpur MALAYSIA