

Varicella Zoster Associated Osteomyelitis

L Mason, E Carpenter, E Morris, J Davies

Citation

L Mason, E Carpenter, E Morris, J Davies. *Varicella Zoster Associated Osteomyelitis*. The Internet Journal of Orthopedic Surgery. 2008 Volume 11 Number 1.

Abstract

Chicken pox (Varicella) is a common childhood viral illness that usually runs an uncomplicated course. Serious musculoskeletal complications of varicella are only rarely reported and can be life and limb threatening. Here we present two cases and a literature review for osteomyelitis following the onset of chicken pox.

INTRODUCTION

Chicken pox is common and usually a benign self involuting disease caused by the varicella zoster virus. It occurs in epidemics seasonally; although complications are rare they can arise resulting in significant morbidity and even mortality. The literature suggests that the most common serious complications of the virus are neurological (e.g. cerebellitis, encephalitis and meningitis), this is followed by secondary infections such as cellulitis¹. Associated orthopaedic complications are infrequently reported. Here two recent cases that presented to our department with osteomyelitis following chicken pox infection are discussed.

CASE 1

A 10 month old female presented to the accident and emergency department with a two day history of pyrexia and a refusal to weight bear on the left leg. The child's mother had noticed that the child had been agitated, lethargic, generally unwell and there had been swelling to the left leg over the previous 24 hours. The child had an unremarkable past medical history apart from a recent varicella zoster infection, 10 days previously, with which she still had evidence of the dried skin vesicles. She was at the crawling stage of development and had not yet progressed to walking. The child had 6 siblings ranging in age from 4 to 14 years of age, all of which were well.

On examination the child was pyrexial (38.6°). Clinical examination revealed the left leg to be generally swollen, hip and ankle movements were normal and palpation around the knee was uncomfortable. No other focus of infection could be identified. Blood tests revealed an elevated white cell count ($25.1 \times 10^9 / l$ with a neutrophilia) and a C-reactive

protein (73 mg/l). Plain radiographs of the left leg demonstrated an extensive periosteal reaction along the shaft of the left tibia with the possibility of a medial metaphyseal corner fracture (Figure 1). Whole body isotope bone scan revealed diffuse uptake involving the whole of the left tibia corresponding with the periosteal reaction evident on the plain film (Figure 2). A diagnosis of osteomyelitis was made and the child was commenced on intravenous flucloxacillin and sodium fusidate.

Day 3 post admission the child remained unsettled, leg swollen with a pseudoparalysis, however she was afebrile. Repeat radiographs showed (Figure 3) significant radiological progression with a clear destructive lesion involving the tibial metaphysis. The patient underwent an ultrasound examination of the area which demonstrated a subperiosteal collection at the medial metaphysis approximately 9mm in depth (Figure 4). This was urgently drained, subsequently resulting in 15ml of pus discharging from the tibial metaphysis. It was noted at operation that the medial cortex of the left tibia had been destroyed and this communicated directly with the medullary canal. Microscopy of the pus showed numerous leukocytes, however no organisms were seen and there was no organism growth from the pus or blood cultures following extended incubation.

The child subsequently settled clinically. The child was treated with a week of intravenous flucloxacillin and sodium fusidate followed by another 5 weeks of the oral equivalents. For this time the child remained in an above knee polymer back slab. Repeat radiographs at 3 months showed significant remodelling (Figure 5).

CASE 2

A six year old girl attended accident and emergency with a 1 day history of pain in her left knee and a limp. There had been no history of injury. Over the previous six hours she had developed a pyrexia and was generally unwell. The patient had a relatively uneventful past medical history except for suffering from a recent varicella zoster infection from which she had made a good recovery. The child had received all her vaccinations to date. She had one older sibling, aged 18 years.

On examination the child had a pyrexia of 38.4°. The left knee appeared slightly swollen with a fullness in its posterior aspect which was non tender. There was no erythema or increase in temperature associated with the knee joint. There was a full range of movement in both knees. No further sources of infection could be identified. Blood examination showed an elevation in C-reactive protein (73 mg/l) but the white cell count remained normal ($8.0 \times 10^9/l$) with a slight neutrophilia ($6.3 \times 10^9/l$). Plain radiographs of the left femur demonstrated a well defined lucency in the medial distal femoral metaphysis suspicious of an infective focus (Figure 6) and she was commenced on intravenous flucloxacillin 600mg QDS and sodium fusidate 165mg TDS.

A mild effusion was noted on subsequent ultrasound examination. A magnetic resonance imaging scan was performed under sedation, which revealed a 1.2cm area of abnormal signal involving the posteromedial aspect of the distal femoral metaphysis with characteristics in keeping with a Brodie's type abscess (Figure 7). There was evidence of surrounding soft tissue oedema with increased signal in the epiphysis consistent with osteomyelitis. The child continued IV antibiotics for a total of one week then was switched to oral equivalents for a further 5 weeks.

Both cases are currently under regular review to ensure that there are no growth disturbances as a consequence of the infection.

DISCUSSION

Chickenpox is a common childhood exanthem with the incidence of the disease in United Kingdom reported to be on the decline². Chickenpox related osteomyelitis is rare and constitutes 0.02% of all complications secondary to varicella infection³. A number of causative organisms have been isolated with a high incidence of Group A beta-haemolytic streptococci. This is in contrast to childhood osteomyelitis where *Staphylococcus aureus* is the most

common isolated organism⁴. The association with streptococci has been postulated to be due to a number of factors including; the varicella vesicles providing a portal of entry for the organism together with the organisms' inherent ability to produce proteolytic enzymes, which facilitate soft tissue invasion and haematogenous seeding to bone.

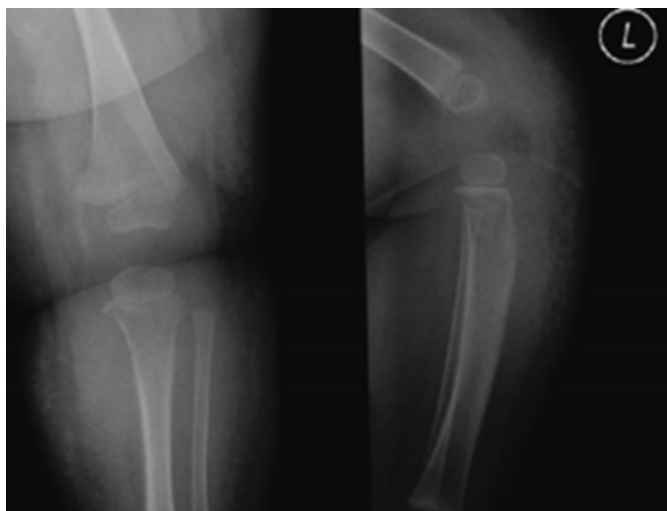
The location of the osteomyelitis is usually metaphyseal due to the nature of the blood supply and the sluggish flow within the metaphyseal vessels. The most common long bones affected are proximal tibia and distal femur.

In order to provide a prompt and accurate diagnosis it is necessary to appreciate that these sequelae can occur. Radiographic modalities are very useful to aid in the rapid diagnosis of osteomyelitis. Soft tissue swelling can be detected as early as 48 hours after the onset of the infection although bony destruction may not be evident radiographically until 10-14 days when approximately one third of the matrix has been destroyed⁵. These changes may be subtle, from a localised periosteal reaction to gross destructive bony changes, as in the case illustrated above. If clinical suspicion is high and plain radiographs are unhelpful a technetium labelled bone scan can be highly sensitive in localising the pathology⁶. Ultrasound is useful for diagnosis in the immature skeleton, detecting soft tissue swelling, an increased thickness of the periosteum or subperiosteal collection, indicative of underlying infection⁷. The use of MRI is the most specific and sensitive of all the radiographic modalities. However, this may not be practical in the young child that will require sedation or anaesthesia for the procedure to be performed.

The mainstay of treatment is a combined course of intravenous and oral antibiotics the duration of which is debatable, conventionally patients will have up to a total of 8 weeks antibiotics⁸. The use of surgery in the management of osteomyelitis is not commonplace but can be indicated in the child where there is a failure of clinical improvement despite maximal microbial therapy. Also the presence of an identifiable subperiosteal collection may be a strong indication for surgical drainage. Whether surgery results in a more rapid resolution is unknown.

Figure 1

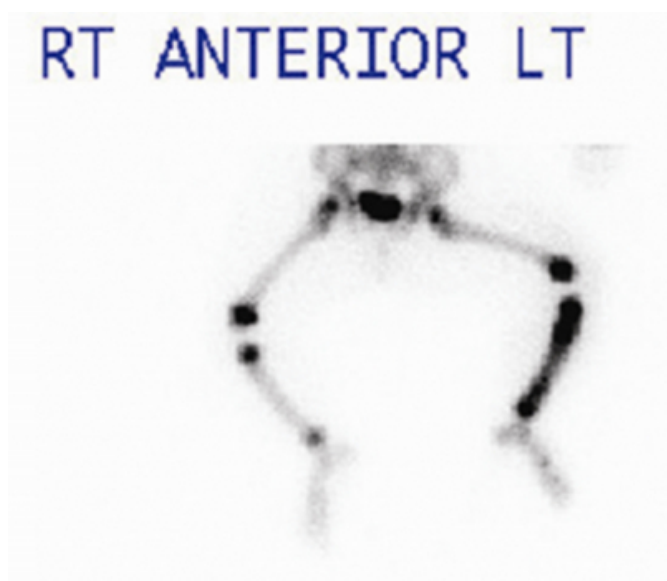Figure 1: Initial radiographs of left lower limb



There is extensive fine periosteal reaction along the tibial shaft with irregularity of the proximal medial tibial metaphysis. There is medial metaphyseal erosion of the cortex and a permeative pattern of bone destruction affecting the metaphysis.

Figure 2

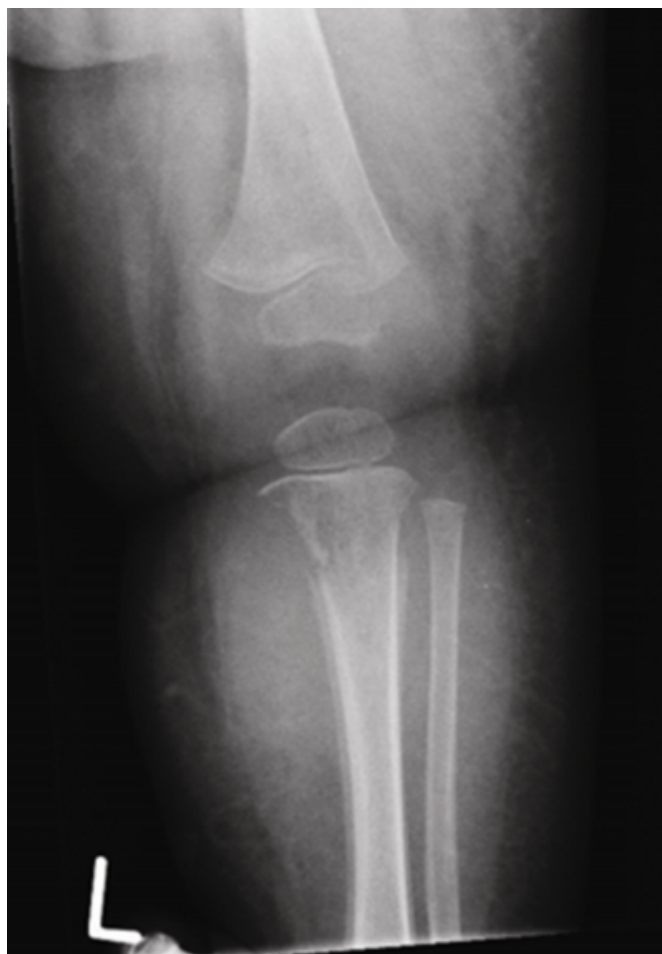Figure 2: Isotope bone scan



Demonstrating diffuse increased osteoblastic activity along the left tibial shaft compared with the normal right tibia. Note the normal increased epiphyseal activity.

Figure 3

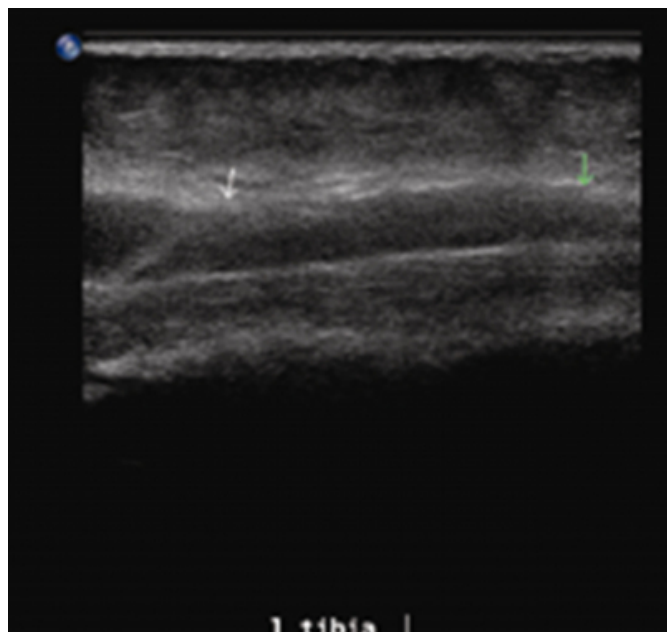
Figure 3: Repeat AP radiograph of left lower limb



Subsequent film taken 4 days following the initial series demonstrates accelerated permeation and destruction of the proximal tibial metaphysis with an associated periosteal reaction extending along the tibial shaft.

Figure 4

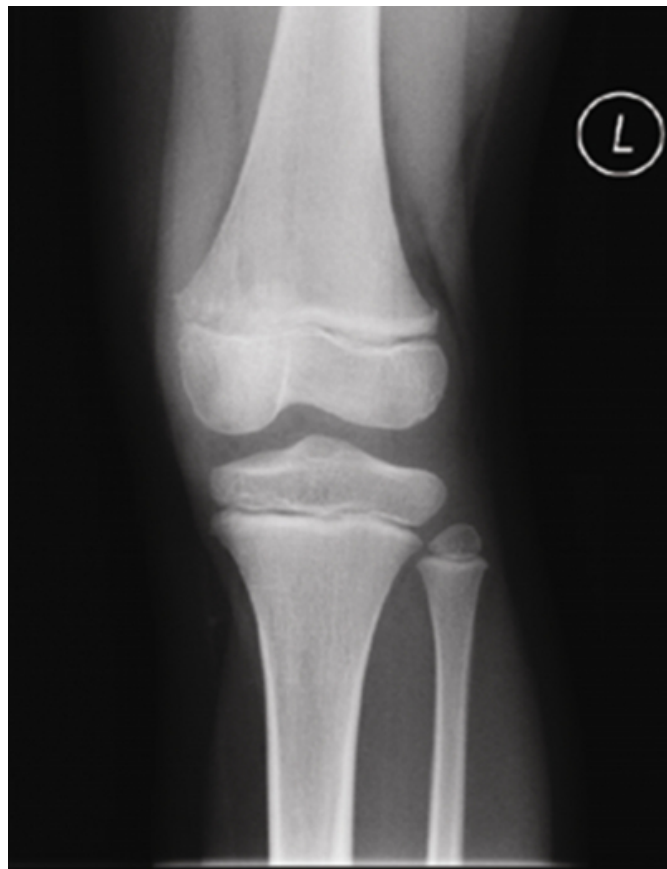Figure 4: Ultrasound



A sagittal image of a focal subperiosteal collection over the proximal tibial metaphysis.

Figure 5

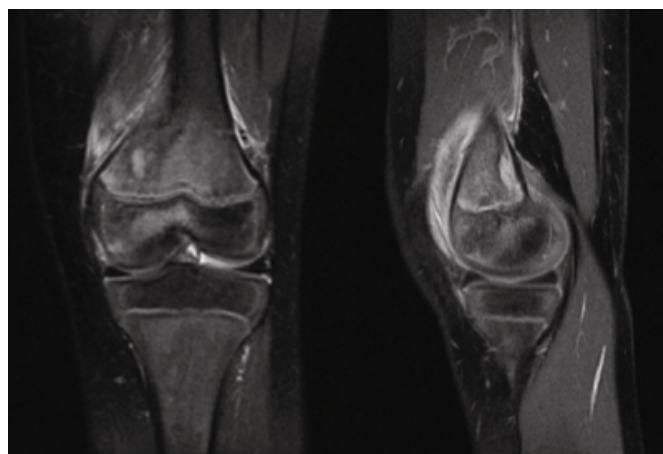
Figure 5: AP radiograph of left knee



A small ovoid focal lucency is present in the distal medial femoral metaphysis.

Figure 6

Figure 6ab: M.R.I. left knee



PD fat saturated imaging sequences demonstrating a large effusion with a 1.2cm focal collection in the posteromedial distal femoral metaphysis characteristic of a Brodie's abscess. There is surrounding inflammatory change in the metaphysis and reactive oedema in the epiphysis suggested by the increased marrow signal.

References

1. Ziebold C, von Kries R, Lang R, Weigl J, Schmitt HJ. Severe complications of Varicella in previously healthy children in Germany: a 1-Year survey. *Pediatrics*. 2001; 108(5): 79-85.
2. Lowe GL, Salmon RL, Thomas DR, Evans MR. Declining incidence of chickenpox in the absence of universal childhood immunization. 2004 *Arch Dis Child*. 89(10): 966-9
3. Schreck P, Schreck P, Bradley J, Chambers H. Musculoskeletal Complications of Varicella. *J Bone Joint Surg Am*. 1996; 78(11): 1713-
4. Blythe MJG, Kincaid R, Craigen MAC, Bennet JC. The changing epidemiology of acute and subacute haematogenous osteomyelitis in children. *J Bone Joint Surg Br*. 2001; 83-B: 99-102
5. Goergens ED, McEvoy A, Watson M, Barrett IR. Acute osteomyelitis and septic arthritis in children. *J Paediatr Child Health*. 2005; 41(1-2):59-62
6. Offiah AC. Acute osteomyelitis, septic arthritis and discitis: Differences between neonates and older children. *Eur J Radiol*. 2006; 60(2):221-32
7. Becker W, Bair J, Behr T, Repp R, Streckenbach H, Beck H, Gramatzki M, Winship MJ, Goldenberg DM, Wolf F. Detection of soft-tissue infections and osteomyelitis using a technetium-99m-labeled anti-granulocyte monoclonal antibody fragment. *J Nucl Med*. 1994; 35(9): 1436-43.
8. Azam Q, Ahmad I, Abbas M, Syed A, Haque F. Ultrasound and colour Doppler sonography in acute osteomyelitis in children. *Acta Orthop Belg*. 2005; 71(5): 590-6.
9. Jaber FM, Shahcheraghi GH, Ahadzadeh M. Short-term intravenous antibiotic treatment of acute hematogenous bone

and joint infection in children: a prospective randomized trial. *J Pediatr Orthop.* 2002; 22(3): 317-20.

10. Borgen L, Haakonsen MO, Gudmundsen TE, Solheim D & Stensvold K. Acute Osteomyelitis as a complication of Varicella. *Acta Radiol.* 2005; 46(6): 652-6.

11. Bittmann S. Bacterial Osteomyelitis after varicella infection in children. *J Bone Miner Metab.* 2004; 22: 283-5

12. Griebel M, Nahlen B, Jacobs RF, Dannenmaier W, Morrissy R. Group A streptococcal postvaricella osteomyelitis. *J Pediatr Orthop.* 1985; 5(1): 101-3.

13. Liebergall M, Porat S. Streptococcal osteomyelitis associated with varicella virus infection: a case report and review of the literature. *J Pediatr Orthop.* 1984; 4(6): 756-8.

14. Turner D, Einhorn M. Group A streptococcal osteomyelitis: severe presentation and course. *Acta Paediatr.*

2003; 92(1): 125-7.

15. Kain Z, Frogel M, Krilov LR. Osteomyelitis associated with varicella infection. *Pediatr Infect Dis J.* 1989; 8(7): 473-5.

16. Meade RH 3rd. Chickenpox and a tender shoulder. *Hosp Pract.* 1978; 13(3): 53-4.

17. Fischbacher CM, Green ST. Varicella and life-threatening streptococcal infection. *Scand J Infect Dis.* 1987; 19(5): 519-20.

18. Sethi AS, Schloff I. Purulent arthritis complicating chickenpox. *Clin Pediatr (Phila).* 1974; 13(3): 280.

19. Kouwabunpat D, Hoffman J, Adler R. Varicella complicated by group A streptococcal sepsis and osteonecrosis. *Pediatrics.* 1999; 104(4 Pt 1): 967-9.

Author Information

Lyndon W. Mason, MRCS

Specialist Registrar – Orthopaedics, Royal Glamorgan Hospital

Eleanor C. Carpenter, MRCS

Specialist Registrar – Orthopaedics, Royal Glamorgan Hospital

Eleanor Morris, FRCR

Consultant – Radiologist, Royal Glamorgan Hospital

Jonathan Davies, FRCS (Orth)

Consultant – Orthopaedic Surgeon, Royal Glamorgan Hospital