

Oesophageal intramural pseudo-diverticulosis

A Iliopoulou, P Iatrikis, J Penston

Citation

A Iliopoulou, P Iatrikis, J Penston. *Oesophageal intramural pseudo-diverticulosis*. The Internet Journal of Gastroenterology. 2007 Volume 7 Number 1.

Abstract

A case of oesophageal intramural pseudo-diverticulosis is described and the endoscopic and radiological features are presented. The relevant literature concerning this rare disease is reviewed.

CASE REPORT

A 64 year old female was referred by her general practitioner to the gastroenterology clinic with a six month history of progressive dysphagia. She complained that solids, more so than liquids, were being held up at the level of the lower sternum. She also had heartburn, acid regurgitation, nausea and vomiting.

She had a history of coronary artery disease and chronic obstructive airways disease. She had longstanding diarrhoea, which was attributed to colonic diverticular disease, and alcohol-induced chronic liver disease. She was a widow who lived with her son and grandchildren. She smoked 20 cigarettes a day for many years and had abused alcohol in the past. On examination, she had the stigmata of chronic liver disease and chest signs of hyperinflation.

Upper GI endoscopy showed a large hiatus hernia associated with mild oesophagitis and mild patchy non-erosive duodenitis. She was treated with proton pump inhibitors and her symptoms resolved.

Five months later, however, she presented with epigastric pain, weight loss, dysphagia and generalised lethargy.

At endoscopy, the previously noted oesophagitis had resolved but she had developed multiple diverticula throughout the oesophagus (Figs.1a and 1b) and these findings were confirmed on barium swallow. (Figs 2a and 2b)

Interestingly, her GP had organised a barium swallow 5 years previously, presumably for similar problems, which was reported to have been normal.

Figure 1

Figure 1ab: Endoscopic appearances of oesophageal intramural pseudo-diverticulosis

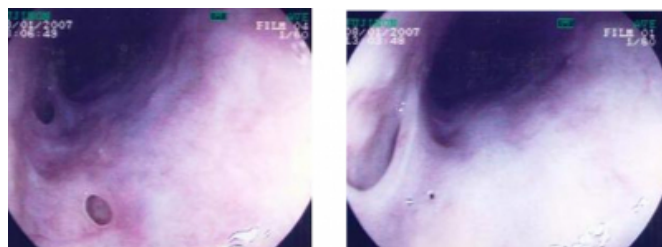
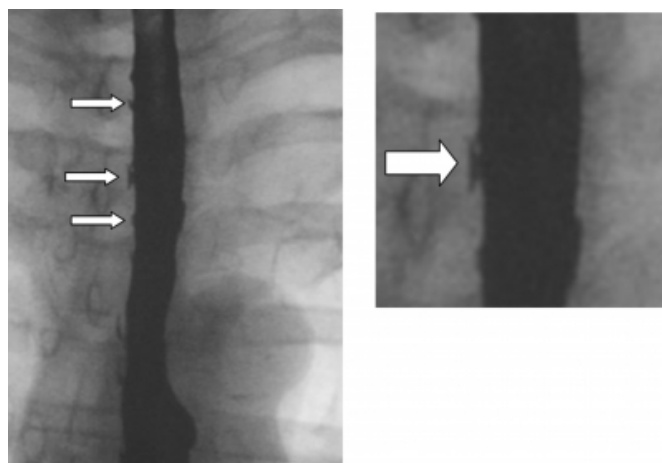


Figure 2

Figure 2ab: Intramural pseudo-diverticulosis as shown on barium swallow



DISCUSSION

The more common varieties of oesophageal diverticula usually result from either raised intraluminal pressure associated with distal obstruction of the lumen or traction from fibrosis in the mediastinum. They may be true diverticula, involving all the layers of the oesophageal wall, or pseudo-diverticula where the mucosa prolapses through

weakened muscle layers. Zenker's diverticulum is located just above the cricopharyngeus, mid-oesophageal diverticula may be associated with diffuse oesophageal spasm or mediastinal fibrosis, while epiphrenic diverticula are associated with achalasia. ¹ Oesophageal diverticula may follow ingestion of alkali which results in weakness of the wall and stricture formation. ² Dysphagia is the most common symptom. ³ However, diverticula may be an incidental finding. Recognised complications include recurrent aspiration pneumonia, ⁴ ulceration, bleeding, ⁵ perforation ⁶ and even fistulae formation into adjacent structures, such as the bronchi, mediastinum, pleural or peritoneal cavities. ^{7,8,9} Malignancy has been reported to occur in diverticula. ^{10,11}

Oesophageal intramural pseudo-diverticulosis is a rare condition. It is characterised by multiple, small, narrow-necked out-pouchings of the mucosa reaching into the muscle layers. Its cause is unknown. Speculation regarding the aetiology includes dilated excretory ducts of submucosal glands, ^{3,12} increased intraluminal pressure secondary to strictures or diffuse oesophageal spasm, ¹³ *Candida* oesophagitis ¹⁴ and eosinophilic oesophagitis. ¹⁵ In perhaps the largest series of cases published, Canon et al. described the radiological features of the disease. ¹⁶ Fifty percent of the 30 patients studied had intramural tracking, in other words, the pseudo-diverticulum penetrated the inner muscle layer and then extended proximally and distally for an average length of about 1.5cm. As the authors pointed out, the clinical significance of tracking is unknown. However, awareness of this radiological finding is important if misdiagnosis – with other conditions such as oesophageal ulcers and extra-mural collections – is to be avoided.

This case study demonstrates the typical radiological features of oesophageal intramural pseudo-diverticulosis. In addition, the less commonly observed endoscopic appearances are presented. Finally, it draws attention to the abrupt onset of this condition over a matter of just a few months.

References

1. Liu JJ, Kahrilas PJ. Pharyngeal and oesophageal diverticula, rings and webs GI Motility online (2006) doi:10.1038/gimo41.
2. Palotás A, Lázár G, Paszt A, Szentpáli K. Alkali ingestion predisposes to developing giant mid-esophageal pulsion diverticulum - a report of a medical rarity. *Med Hypotheses* 2004;62:931-4.
3. Manz M, Meier R, Schaub N, Toia D, Steuerwald M. Esophageal intramural pseudodiverticulosis. *Schweiz Rundsch Med Prax* 2007;96:1385-9.
4. Greutmann M, Marincek B, Follath F. Recurrent pneumonia--case report and review of the literature. *Ther Umsch.* 2004;61:700-2.
5. Chen L, Walser EM, Schnadig V. Fatal hemorrhage secondary to ulcerated epiphrenic pseudodiverticulum. *Arch Pathol Lab Med.* 2006;130:867-70.
6. Cantù P, Bozzani A, Penagini R. Spontaneous perforation of an oesophageal diverticulum in achalasia. *Dig Liver Dis.* 2003;35:735-7.
7. Kabra R, Welke KF, Kernstine KH, Field FJ, Thompson BH, Vats HS, Weintraub NL. Bacterial pericarditis due to group F streptococci as a complication of esophagomediastinal fistula. *Ann Thorac Surg.* 2005;79:2132-4.
8. Schacherer D, Mayer S, Borisch I, Zorger N, Kullmann F, Schoelmerich J, Grossmann J. Esophagobronchial and esophagomediastinal fistula, pleural and pericardial effusion due to severe pseudodiverticulosis of the esophagus. *Z Gastroenterol.* 2006;44:491-5.
9. Vantsian EN, Chissov VI. Etiology and pathogenesis of fistulas in esophageal diverticulosis. *Khirurgiia (Mosk)* 1975;5:103-8.
10. Honda H, Kume K, Tashiro M, Sugihara Y, Yamasaki T, Narita R, Yoshikawa I, Otsuki M. Early stage esophageal carcinoma in an epiphrenic diverticulum. *Gastrointest Endosc.* 2003;57:980-2.
11. Avisar E, Luketich JD. Adenocarcinoma in a mid-esophageal diverticulum. *Ann Thorac Surg.* 2000;69:288-9.
12. Rahlf G, Wilbert L, Lankisch PG, Huttemann U. Intramural diverticulosis. *Acta Hepatogastroenterol (Stuttg).* 1977;24:110-5.
13. Montgomery RD, Mendl K, Stephenson SF. Intramural diverticulosis of the oesophagus. *Thorax* 1975;30:278-284.
14. Irakam SP, Kunavarapu C, Hasan M, Marsh F, Cerulli M. Report of a case illustrating the dilemma of primary esophageal pseudodiverticulosis with colonization of candida vs. recurrent esophageal candidiasis leading to pseudodiverticulosis. *The American Journal of Gastroenterology* 2000;95:2423.
15. Engel MA, Raithel M, Amann K, Greeß H, Hahn EG, Konturek PC. Rare coincidence of eosinophilic esophagitis with esophageal stenosis and intramural pseudodiverticulosis. *Dig Liver Dis.* (2007) doi:10.1016/j.dld.2007.04.011.
16. Canon CL, Levine MS, Cherukuri R, Johnson LF, Smith JK, Koehler RE. Intramural tracking: a feature of esophageal intramural pseudodiverticulosis. *AJR Am J Roentgenol.* 2000;175:371-4.

Author Information

Amalia Iliopoulou

Department of Gastroenterology, Scunthorpe General Hospital

Ptychion Iatrikis

Department of Gastroenterology, Scunthorpe General Hospital

James Penston, MD

Department of Gastroenterology, Scunthorpe General Hospital