

# Traumatic Ureteroarterial Fistula Treated with Endovascular Stenting

D Point, J Hakim, V Chander, A Luchey, S Zaslau

## Citation

D Point, J Hakim, V Chander, A Luchey, S Zaslau. *Traumatic Ureteroarterial Fistula Treated with Endovascular Stenting*. The Internet Journal of Endovascular Medicine. 2008 Volume 1 Number 2.

## Abstract

Ureteroarterial fistulas (UAF), a rare cause of hematuria [1,2] with a mortality rate reported as high as 14-23%, [2,3] were first reported in 1908 [4]. Although there has been an increase in incidence, reports in the literature consist only of case review and a single institution case series [2]. The identified predisposing factors for UAF formation are chronic ureteral catheterization, previous pelvic surgery, radiotherapy and vascular disease with previous vascular surgery or grafting [2]. Additional awareness of this complication may possibly aid in identification of high risk individuals and preventive measures. We present a case report of UAF, and a review of UAF focusing on identifying patients at risk for fistula development, presentation, diagnostic imaging/procedures, and treatment modalities.

## INTRODUCTION

Ureteroarterial fistulas (UAF), a rare cause of hematuria [1,2] with a mortality rate reported as high as 14-23%, [2,3] were first reported in 1908 [4]. Although there has been an increase in incidence, reports in the literature consist only of case review and a single institution case series [2]. The identified predisposing factors for UAF formation are chronic ureteral catheterization, previous pelvic surgery, radiotherapy and vascular disease with previous vascular surgery or grafting [2]. Additional awareness of this complication may possibly aid in identification of high risk individuals and preventive measures. We present a case report of UAF, and a review of UAF focusing on identifying patients at risk for fistula development, presentation, diagnostic imaging/procedures, and treatment modalities.

## CASE REPORT

A 62-year-old female presented with a two day history of intermittent but worsening gross hematuria. Four days prior the patient was seen and placed on antibiotics for suspected urinary tract infection along with irritative voiding symptoms. Her previous history is significant for colorectal cancer treated with preoperative radiation and chemotherapy followed by lower anterior resection in 1997 as well as prior bilateral tubal ligation. As a consequence of her radiotherapy, the patient developed chronic bilateral hydronephrosis in 2008 with bilateral ureteral obstruction at the level of the iliac vessels, requiring serial ureteral

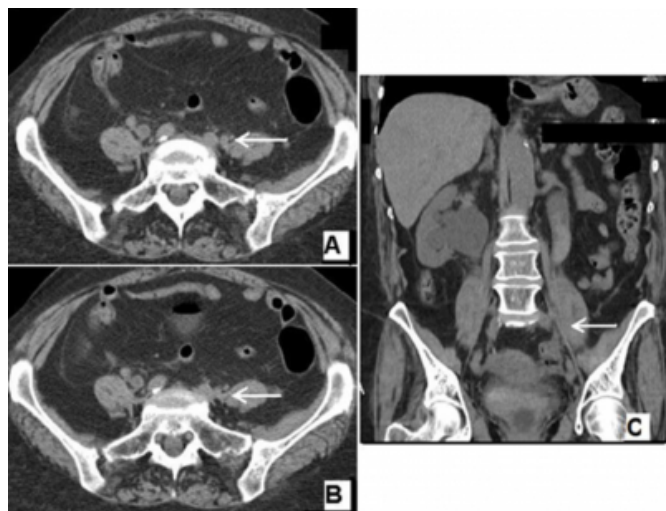
stenting. Review of the patient's chart demonstrated a negative non-contrast CT scan five weeks prior to her presentation as well as a fifty-three pack year history.

Upon presentation a KUB demonstrated migration of the right ureteral stent. The next day, she was taken for stent exchange, and cystoscopy demonstrated both stents emerging from their respective ureter orifices without any tissue inflammation present, and the right stent was removed without complication. Following removal of the left ureteral stent, profuse hemorrhage was observed quickly preventing any further visualization. The patient rapidly became hypotensive requiring transfusion with three units of packed red blood cells to maintain hemodynamic stability. The diagnosis of UAF was clinically suspected and the patient was emergently transferred to a larger facility with the interdisciplinary teams necessary for management.

Upon arrival the patient underwent a non-contrast abdominal and pelvic CT scan which demonstrated bilateral markedly hydronephrosis with abrupt narrowing in the low pelvis approximately 5 to 6 millimeters from the ureterovesical junction. The left ureter passed immediately adjacent to the left common iliac artery (Figure 1), and fluid levels were observed within the left kidney collecting system, suggesting acute hemorrhage (Figure 2). Hyperdense material with air was observed in the bladder suggestive of thrombus.

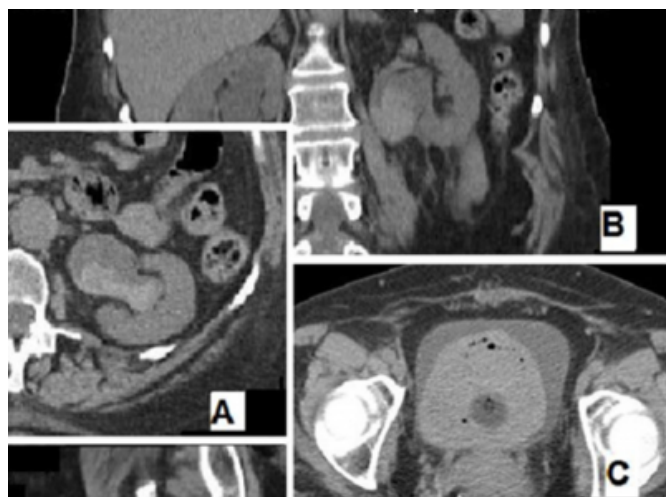
**Figure 1**

Figure 1: Non-contrast CT. (A) Demonstration of left common iliac artery and ureter (white arrow). (B) Coronal section depicting possible attachment at the intersection of the left ureter and left common iliac artery. (C) Sagittal section depicting crossing of the left ureter and left common iliac artery (white arrow).



**Figure 2**

Figure 2: Non-contrast CT. (A) Coronal section of left kidney demonstrating fluid levels suggestive of possible thrombus. (B) sagittal section demonstrating left hydroureteronephrosis and casting of the renal collecting system. (C) Coronal section with hyperdense material and air demonstrated in bladder.

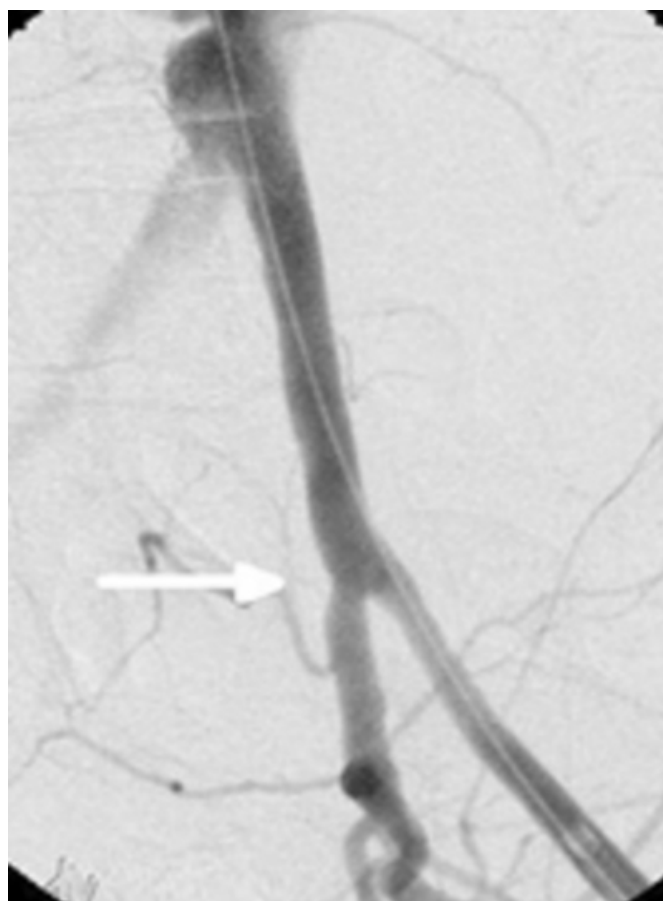

The patient was again taken to the operating room. Left iliac angiography and aortography failed to reveal the fistula, but did demonstrate an indentation in the distal medial common iliac artery (Figure 3). Intravascular ultrasound demonstrated the appearance of pulsatile material in the ureter, despite no active bleeding demonstrated on angiography. Suspecting left common iliac ureter fistula and the site of indentation, a

soft Omni catheter was successfully passed from artery into the left distal ureter, and contrast was demonstrated in the bladder (Figure 4). The left internal iliac artery was catheterized distally and embolized with placement of 5 coils. The left external and common iliac arteries were next serially stented with overlapping endoprosthesis (Viabahn). After withdrawal of the endovascular balloon catheter, pelvic angiography demonstrated closure of the fistula with no verifiable leakage of contrast into the ureter (Figure 5). Excellent blood flow to the left foot was verified at the conclusion of the procedure.

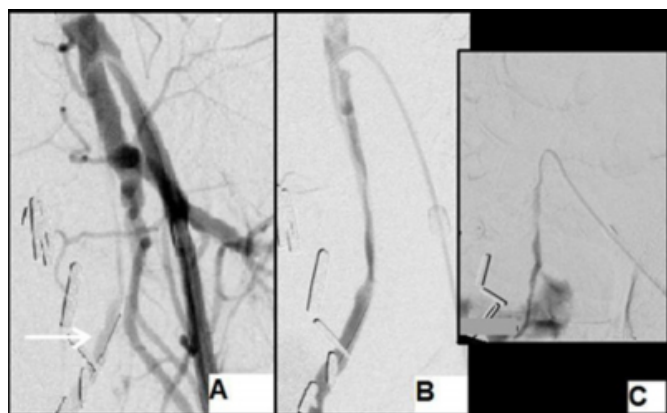
**Figure 3**

Figure 3: Angiography of the left common iliac artery reveals a slight indentation (white arrow) near the bifurcation, suggesting the location for a suspected ureter common iliac artery fistula.



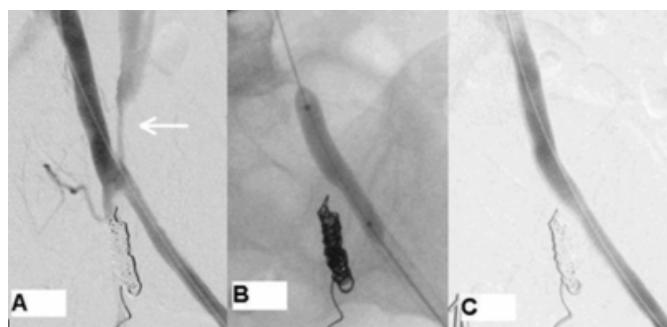
**Figure 4**

Figure 4: (A) Provocative angiography with endovascular catheterization and guide wire placement through fistula into the left ureter (white arrow). (B) Injection of contrast reveals outline of left ureter with collection in the bladder (C).



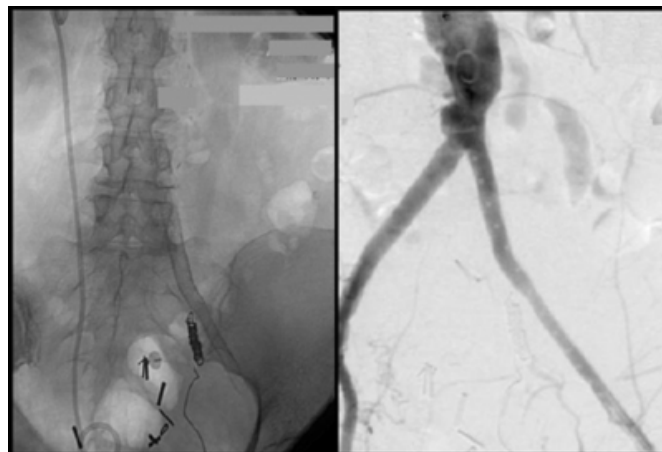**Figure 5**

Figure 5: Angiography. (A) Extravasation of contrast into the ureter through patent ureteroarterial fistula (white arrow) following endovascular coiling of the internal iliac artery and provocative angiography. (B) Tympanade of the fistula and dilation of the common and external iliac arteries by endovascular angioplasty. (C) Occlusion of fistula following endovascular stent placement.



**Figure 6**

Figure 6: Successful management of common iliac artery to ureter fistula with common and external iliac artery endovascular stent placement and embolization of the internal iliac artery. The left ureter was managed by percutaneous nephrostomy placement



During the course of the operation, the patient developed a very tense bladder, particularly after left endovascular ureteral catheterization. The bladder softened following exclusion of the common iliac artery. Over the course of treatment and postoperatively the patient received three more units of packed red blood cells and was placed on continuous bladder irrigation for clot retention. Post-operatively the left ureter was managed with left percutaneous nephrostomy tube, and a cystoscopy was performed which noted a small extra peritoneal bladder perforation. She was placed on antibiotic prophylaxis, and had resolution of her hematuria at her two-week follow-up.

## DISCUSSION

There has been a dramatic increase in the incidence of UAF following the introduction of ureteral stents and the advancement/aggressive nature of surgical resection along with radiotherapy in the treatment of pelvic malignancy [1]. A review by Batter and associates of 37 cases identified several predisposing risk factors for fistula formation: previous genitourinary or pelvic surgery (68%); chronic ureteral stent placement (65%); radiation therapy (46%); previous vascular surgery (19%); and underlying vascular pathology, such as atherosclerotic aneurysms (19%) [5]. Similar studies have since confirmed these findings, with history of prior pelvic surgery, pelvic radiation and indwelling ureteral stents identified as the most highly associated conditions with UAF [2,5,6,8]. These factors appear to be additive and there is an association with carcinomas of the cervix, bladder, endometrium, rectum and

vulva most likely due to the combined use of surgery, radiation, and ureteral stenting in disease management.

Other less common conditions reported with UAF are abdominal aortic aneurysms, ureteral lithiasis, prior balloon dilation of ureteral strictures, appendectomy, pelvic abscesses, external penetrating trauma, diverting urinary conduits, pelvic vessel aneurysms and pyelonephritis during pregnancy [1,5,6,9]. Idiopathic ureteroiliac fistula are extremely rare and are reported to constitute less than 15% of the reported fistulas, with aorto-iliac aneurysm being the dominant finding, and rarely arteriovenous malformation or aberrant vasculature observed during surgical exploration [1].

The first reported case of UAF occurred following open bilateral ureterolithotomies [4]. The fistulas were a result of compression due to placement of external drainage tubes and the complication was identified after their removal prompted gross hematuria and external hemorrhage. The current increase in the incidence of this rare condition appears to be associated with the expanded use of indwelling ureteral stents, suggesting a related mechanism for fistula formation. Fistula formation frequently occurs where the ureter crosses over the artery, with the ipsilateral common iliac artery being the most common followed by the external and internal iliac arteries [2]. As demonstrated by this case, the initial step in UAF formation is thought to arise as when fibrosis following surgery or radiation fixates the ureter to the artery at the point of intersection. Atherosclerotic aneurysms may generate perivascular inflammation and contribute or produce local fibrosis. Following fibrotic attachment of the ureter to the artery; the presence of an indwelling ureteral catheter serves as a pressure counter point. The constant pulsation of the iliac artery is then transmitted to the already damaged ureter and artery. This stress generates pressure necrosis with eventual fistula formation. Factors that promote tension and damage to the lining of these structures (hydronephrosis, infection, interruption of blood supply and innervations second to surgery, hypotension, and radiation) generate further compromise [7].

As in our case, the presence of these conditions can weaken wall strength of both structures, and precipitate or worsen fistula hemorrhage during ureteral stent exchange [7]. As a result Van den Bergh et al. recommend the use of smaller softer stents in patients requiring chronic ureteral catheterization with a coexisting history of pelvic radiation or surgery to prevent this rare but devastating complication

[10]. The fact that a 7 French stent provides the same flow rate as a 12 French further supports the argument. However, as this case and others demonstrate, UAF can result despite smaller stents use, and smaller French size does not exclude possible fistula formation [9,11].

Currently endovascular stenting has become the treatment modality of choice due to its minimally invasive approach, rapid control of bleeding, and earlier patient recovery times. Additionally, it can be rapidly initiated following provocative angiography [2,9]. Previously balloon-expandable autologous vein covered grafts were the treatment of choice, however they have largely been replaced by self-expandable synthetic resin stents with good results [2,6]. However, the long term graft patency and infection rates of these grafts have yet to be evaluated. Without active bleeding to identify fistula location common iliac arterial embolization can be difficult. Endovascular stenting has several advantages over embolization; arterial supply to the lower extremity is preserved which excludes the need for a secondary arterial bypass graft along with its inherent complications and the need for visualization of the fistula is not required [12]. . The internal iliac artery is often embolized in the case of a fistula located at the common iliac in order to successfully ensure graft placement and vascular control.

## **CONCLUSION**

Ureteroarterial fistulae are a rare cause of both intermittent and continuous hematuria. Due to the lack of definitive diagnostic studies, and the high rate of mortality associated with delays in diagnosis, clinicians must maintain a high index of suspicion when addressing patients with gross hematuria and other risk factors that are concerning for UAF. Identification of predisposing factors can lead to prompt diagnosis or suggest the need for emergent laparotomy in the presence of negative diagnostic studies. Additional treatment procedures, including leaving ureteral catheters in place following hemorrhage can aid in management. Traditional imaging studies may lend support to the diagnosis, warranting the use of potentially more invasive procedures to yield the diagnosis; however negative findings are cannot exclude a possible UAF due to the low sensitivity. Endovascular stenting has become the treatment of choice in recent years with good results reported in the literature; however no long term studies have reported on potential long term complications of graft placement.

## References

1. Bergqvist D, Parsson H, Sherif A. Arterio-ureteral fistula- a systematic review. *European Journal of Vascular and Endovascular Surgery* 2001;22(3):191-196.
2. Krambeck AE, DiMarco DS, Gettman MT, Segura JW. Ureteroiliac artery fistula; Diagnosis and treatment algorithm. *Urology* 2005;66:990-994.
3. Kim DH, Mahdy A, Mundra V, Berman M, Ghoniem GM. Ureteroarterial fistula. *Case Report Med*. 2009;2009;326969. Epub 2009 Nov 15.
4. Moschcowitz A. Simultaneous ligation of both external iliac arteries for secondary hemorrhage following bilateral ureterolithotomy. *Annals of Surgery*. 1908;48:872-875.
5. Batter SJ, McGovern FJ, Cambria RP. Ureteroarterial fistula: case report and review of literature. *Urology* 1996;48(3):481-9.
6. Van den Bergh RC, Moll FL, de Vries JP, Lock TM. Arterio-ureteral fistulas: unusual suspects-systemic review of 139 cases. *Urology*. 2009;74(2);251-5.
7. Pappy R, Abu-Fadel M, Hennebry T. Ureteroarterial fistula: A rare cause of hematuria managed in the cardiac cath lab. *Journal Invasive Cardiology* 2008;20(5):158-160.
8. Araki T, Nagata M, Araki T, Takihana Y, Takeda M. Endovascular treatment of ureteroarterial fistulas with stent-grafts. *Radiation Medicine* 2008;26:372-375.
9. Yamasaki K, Omori K, Takaoka E, Sekido N, Shigai M, Mori K, Minami M, Watanabe Y, Shimazui T, Akaza H. Successful management by provocative angiography and endovascular stent of ureteroarterial fistula in a patient with long-term indwelling ureteral stent. *Jpn J Clin Oncol*. 2010;40(3):267-70.
10. Van den Bergh RC, Moll FL, de Vries JP, Yeung KK, Lock TM. Arterio-ureteral fistula: 11 new cases of wolf in sheep's clothing. *Journal of Urology*. 2008;179(2):578-81.
11. Chew BH, Knudsen BE, Denstedt JD. The use of stents in contemporary urology. *Curr Opin Urol*. 2004;14:111-5.
12. Bilbao JI, Cosin O, Bastarrika G, Rosell D, Zudaire J, Martinez-Cuesta A. Treatment of ureteroarterial fistulae with covered vascular endoprostheses and ureteral occlusion. *CardioVascular and Interventional Radiology*. 2005;28(2):159-163.

**Author Information**

**Dana C. Point, BA**

Senior Medical Student, Marshall University School of Medicine

**Jonathan I. Hakim, MD**

Staff Urologist, War Memorial Hospital

**Vishnu Chander**

Department of Radiology, War Memorial Hospital

**Adam Luchey, MD**

Senior Resident, Division of Urology, West Virginia University

**Stanley Zaslau, MD, MBA, FACS**

Professor and Chief, Division of Urology, West Virginia University