

Relapsing and Migrating Transient Osteopenia Post-Pregnancy

N Parmar, M Beverly

Citation

N Parmar, M Beverly. *Relapsing and Migrating Transient Osteopenia Post-Pregnancy*. The Internet Journal of Orthopedic Surgery. 2006 Volume 4 Number 1.

Abstract

Transient osteoporosis of the hips and knees has been described in adults and is self limiting and resolving. Migrating osteoporosis has not been described previously. We report of a case of relapsing and migrating hip osteopaenia during and after pregnancy.

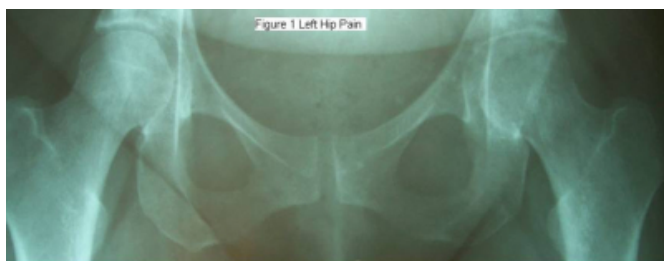INTRODUCTION

Transient osteoporosis of the hips and knees was first reported by Curtiss and Kincaid (1959) in a series of three women during the third trimester of pregnancy (1). This benign and self limiting condition may also affect middle aged men. It presents as joint pain, often debilitating which can be of gradual or sudden onset. A history of significant trauma or antecedent illness is uncommon. There is usually temporary osteopaenia with preservation of joint space on x ray. We describe a case of relapsing and migrating hip osteopaenia during and after pregnancy.

CASE REPORT

A 33 year old primigravida woman was seen in late pregnancy with a 5 week history of left sided hip pain and stiffness. She was able to walk only with crutches. She denied any history of trauma. She had reduced power in her left leg but an otherwise normal clinical examination. After delivery the patient had osteoporosis in her left hip evident on x ray (fig 1). She was managed conservatively with analgesia. Her left hip symptoms settled fully after two months.

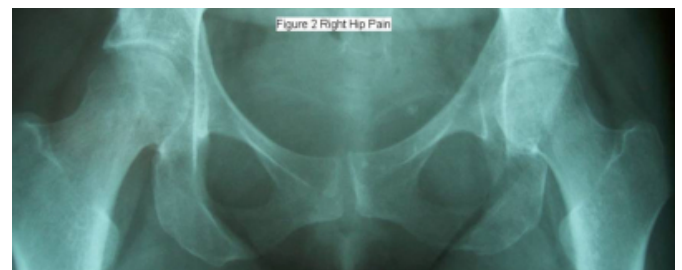
Figure 1



Five months after her initial presentation our patient developed similar symptoms in the right hip.

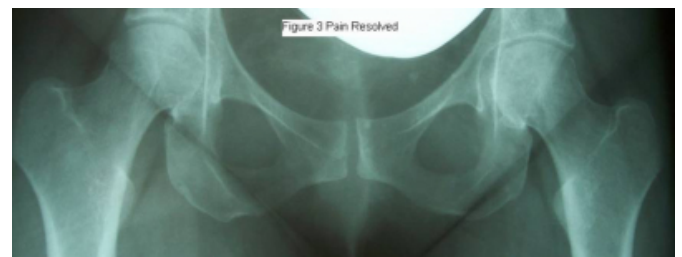X-rays at this stage showed resolution on the left side and osteopaenic changes on the right side (fig 2). A bone scan was obtained which showed increased blood flow and pooling to the right hip and acetabulum while the left was normal.

Figure 2



She was managed conservatively. The patient was seen 6 months later and was symptom-free. Her hip x rays showed resolution of the hip osteoporosis bilaterally (fig 3).

Figure 3



DISCUSSION

Hunder and Kelly named this syndrome transient osteoporosis in 1967 (2). Pregnant women in their third trimester are most commonly affected. The hip joint is the most affected joint with the left side more than the right (3). Bilateral involvement is present in 25-30% of patients (4). We could find no previous reports of migratory osteopaenia in the literature.

The aetiology of transient osteoporosis of the hip (TOH) is unknown. Oestrogen deficiency is associated with bone loss (5,6). Other factors implicated include negative calcium balance in favour of foetus during pregnancy, increased adrenal cortex activity (4) Sudeck's atrophy (2), intra-medullary bone hypertension (7), small vessel ischaemia, genetic predisposition and compression of the obturator nerve (8). Our patient's blood results were unremarkable and she was otherwise medically fit.

Three phases or patterns of TOH have been described by Lequesne and Mauger (9) namely 1- increasing pain with normal x rays, 2- maximal pain with osteopaenia, and 3- regression of the symptoms and radiologic changes. Our patient showed phases 2 & 3 with relapsing osteopaenia and symptoms lasting in all about 8 months. The mean duration is typically 6 to 8 months but can last up to and beyond a year (9) with complete recovery. Migratory or sequential TOH has not been described previously.

Our patient recovered completely with conservative management. We highlight its possible importance and relevance in post partum orthopaedic pathology.

References

1. Curtiss PH., Kincaid WE. Transitory demineralisation of the hip in pregnancy: a report of three cases.(abstract) J Bone Joint Surg. 1959;41:1327-33
2. Hunder GG., Kelly PJ. Transient osteoporosis of the hip: A clinical syndrome?(abstract).Arthritis Rheum 1967;10: 285
3. Rosen RA. Transitory demineralisation of the femoral head. Radiology 1970;94:509-512
4. Debnath UK., Kishore R., Black RJ. Isolated acetabular osteoporosis in TOH in pregnancy: A Case Report. Southern Medical Journal 2005;98(11): 1146-48
5. Ma FYP., Falkenberg M. Case reports: Transient osteoporosis of the hip: An atypical case. Clinical Orthopaedics and related research 2006;445: 245-9
6. Axt-Flidner R., Schneider G., Seil R, et al. Transient bilateral osteoporosis of the hip in pregnancy: a case report and review of literature. Gynae Obstet Invest.2001;51:138-40
7. Lequesne M. Transient osteoporosis of the hip: a non traumatic variety of Sudeck's atrophy. Ann Rheum Dis. 1968;27:463-71
8. Schapira D. Transient osteoporosis of the hip. Semin Arthritis Rheum 1968;22:787-92
9. Lequesne M., Mauger B.100 decalcifying algodystrophies of the hip in 74 Patients (French- abstract).Rev Rhum Mal Osteoarthri.1982;49:787-792

Author Information

Nandita Kantilal Parmar, BSc., MBBS, MRCS

SHO Trauma & Orthopaedic Surgery, Ealing Hospital

Michael Beverly, DCH, FRCS, FRCS Orth

Consultant Trauma and Orthopaedic Surgery, Ealing Hospital