

Beating Heart Coronary Bypass Procedure In A Hepatic Hydatid Cystic Patient

L Yılık, U Yetkin, B Özpak, A Özelçi, ? Yürekli, M Aksun, A Gürbüz

Citation

L Yılık, U Yetkin, B Özpak, A Özelçi, ? Yürekli, M Aksun, A Gürbüz. *Beating Heart Coronary Bypass Procedure In A Hepatic Hydatid Cystic Patient*. The Internet Journal of Parasitic Diseases. 2007 Volume 3 Number 1.

Abstract

Coronary bypass operations (CABG) can be performed with acceptable risks in the patients with diseases of different systems. Cardiopulmonary bypass has been reported to have many effects on the immune system with conventional CABG.

In this study, we reported our case with coronary artery disease who underwent beating heart CABG under the light of current literature. She was diagnosed as hydatid cystic disease of liver and cholelithiasis priorly by Department of General Surgery and preoperative investigations for these diseases revealed coronary artery disease.

Concerns about systemic inflammatory response to CPB and its consequences include possible systemic dissemination because of the immune system or direct vascular dissemination . We suggest that avoidance of CPB is beneficial for the treatment. Off-pump coronary artery surgery clearly has a place and can be a successful procedure for these patients.

Hydatidosis, caused by *Echinococcus granulosus*, is an endemic parasitic disease in Mediterranean countries. The most frequent anatomic locations are liver and lung⁽¹⁾. In humans, most hydatid cysts occur in the liver and 75% of these are single⁽²⁾. Widespread and successful performance in cardiac operations, leads these operations in the patients with high risk due to other systemic pathologies⁽³⁾.

CASE PRESENTATION

Our case was a 75-year-old female. She was being investigated by Department of General Surgery with diagnoses of hydatid cyst in liver and cholelithiasis. Her preoperative tests revealed significant coronary artery disease requiring CABG and she was referred to our clinic. Whole abdominal ultrasound showed a multilocular cystic lesion of 170x126 millimeters with inner calcifications and septations localized within the right hepatic lobe at subdiaphragmatic region with concomitant cholelithiasis (Figures 1 and 2).

Figure 1

Figure 1

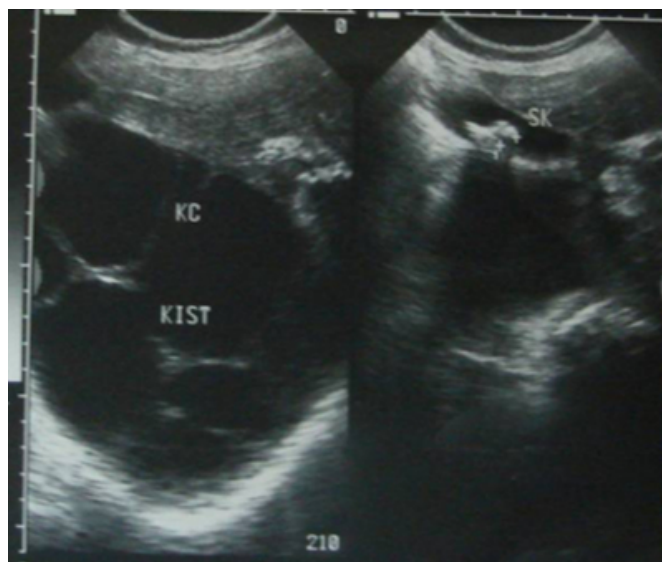
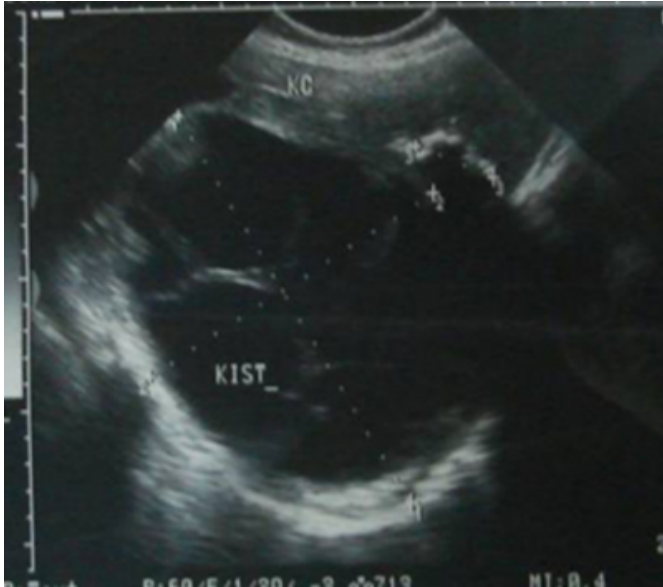

Figure 2

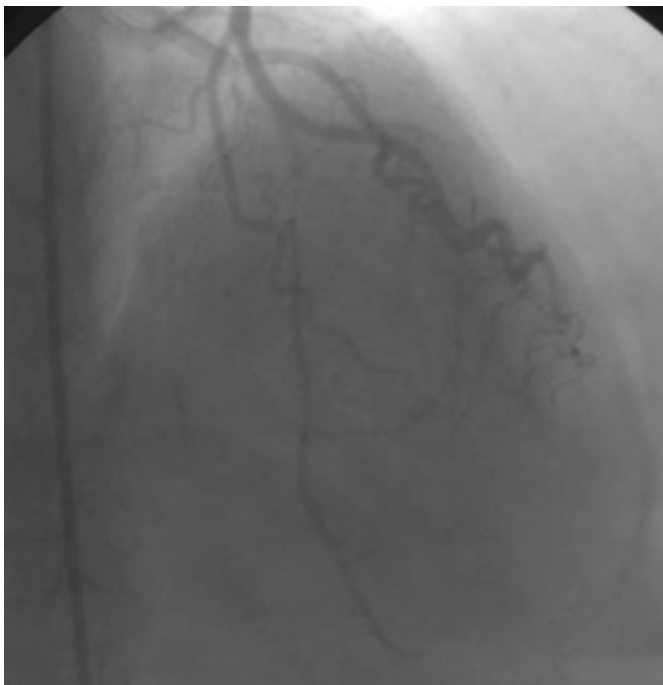Figure 2



His coronary angiography revealed that there were significant stenotic lesions in left anterior descending (LAD) artery. Moreover, left ventricular ejection fraction was calculated as 40% (Figure 3).

Figure 3

Figure 3



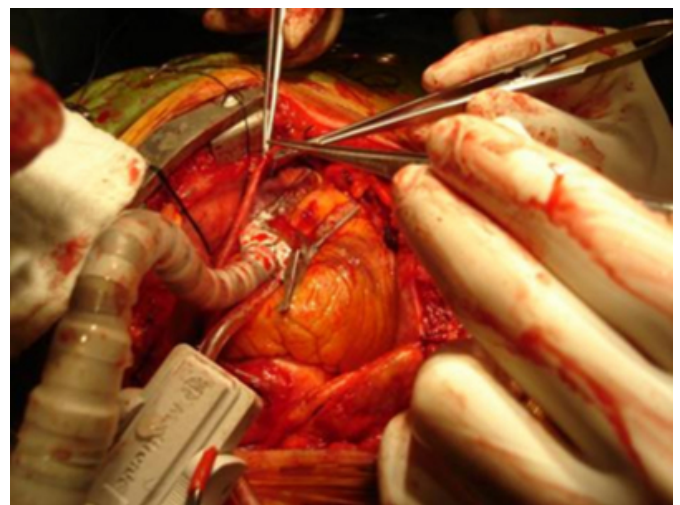Before operation cystic metastatic investigations were held with brain CT, whole abdominal USG and thoracic CT and no metastatic focus finding was determined. All preoperative biochemical parameters were normal. Regarding her cardiac

performance and her hydatid cystic lesion at liver, we planned to carry out OPCAB surgery in order to avoid the side effects of cardiopulmonary bypass (CPB).

She underwent coronary revascularization with these findings. Following median sternotomy 1/3 distal part of great saphenous vein of the right leg was harvested. Following half-dose heparin administration OPCAB surgery was performed using the Octopus 3 (Medtronic Inc, Minneapolis, MN) stabilizer. The saphenous vein graft was anastomosed to the LAD (Figure 4).

Figure 4

Figure 4



The patient was extubated at 9th hour postoperatively and the total drainage from the mediastinal drains was 450 mLs in 24 hours, one unit blood transfusion was required. She was transferred to service from intensive care unit on second postoperative day. She didn't have additional problem and she was discharged home with surgical success and without any cardiac complications at 7th day. She was recommended to apply to our outpatient clinic for follow-up and our General Surgery Clinic for the operation for hydatid cyst and cholelithiasis after 8 weeks.

DISCUSSION

Patients who require coronary artery bypass grafting and who also have concomitant disease constitute a high-risk group, and surgical strategy for these patients remains controversial. Management of these concomitant lesions is controversial because of the systemic side-effects of a cardiopulmonary by-pass.

Beating heart CABG relieves cardiac problem synchronically or subsequently and enhances the solution of

potential problems during and after the major resection surgery⁽³⁾. For these patients, extracorporeal circulation impairs the immune system and negatively affects the defense of host. Hirose and assoc. proved that healing period is shorter and hospital stay and cost, decrease significantly when compared with conventional CABG in the patients with beating heart CABG procedure if the risks of cardiopulmonary bypass procedure are relieved⁽⁴⁾.

Intrathoracic rupture of hydatid cysts situated in the hepatic dome is a serious complication resulting in damage to the pleura, pulmonary parenchyma, and bronchi⁽¹⁾. Hydatid cyst of the dome of the liver can cause significant associated intrathoracic complications including pleural effusion, pleural empyema, erosion through the diaphragm into lung, various degrees of pneumonitis or pulmonary abscess, or severe destruction of both diaphragm and right lower pulmonary lobe⁽⁵⁾. Analysis of these instances allowed us to see that ultrasonograms of the liver and roentgenograms of the thorax are often the most sensitive and reliable diagnostic procedures for showing the intrathoracic evolution of the cyst⁽⁶⁾. Kilani et al believe ultrasonography to be the best examination for assessing biliary, hepatic, diaphragmatic, and pleuropulmonary lesions⁽¹⁾. Kanko and assoc suggest that in the persistent right pleural effusion that occurs after open heart surgery hydatid cyst of the liver should be remembered, especially in the endemic regions⁽⁷⁾.

CORRESPONDENCE TO

Doç. Dr. Ufuk YETKİN, 1379 Sok. No: 9, Burç Apt. D: 13 - 35220, Alsancak – İZMİR / TURKEY Tel: +90 505 3124906 , Fax: +90 232 2434848 e-mail: ufuk_yetkin@yahoo.fr

References

1. Kilani T, El Hammami S, Horchani H, Ben Miled-Mrad K, Hantous S, Mestiri I, Sellami M. Hydatid disease of the liver with thoracic involvement. *World J Surg* 2001;25(1):40-5.
2. Perek A, Numan F, Perek S, Durgun V, Kapan M, Aykuter G. Management of a patient with hepatic-thoracic-pelvic and omental hydatid cysts and post-operative bilio-cutaneous fistula: a case report. *Hepatogastroenterology* 1999 ;46(28):2202-7.
3. Yetkin U, Yilik L, Gürbüz A. Beating Heart Coronary Bypass Procedures In Patients With Stomach Cancer: Case Report. *J Thorac Cardiovasc Surg* 2004;12(3):194-5.
4. Hirose H, Amano A, Yoshida S, et al. Coronary artery bypass grafting in patient with malignant neoplasm. Efficacy of coronary artery bypass grafting on beating heart. *Jpn J Thorac Cardiovasc Surg* 2000;48(2):96-100.
5. Yacoubian HD. Thoracic problems associated with hydatid cyst of the dome of the liver. *Surgery* 1976 ;79(5):544-8.
6. Pinna AD, Marongiu L, Cadoni S, Luridiana E, Nardello O, Pinna DC. Thoracic extension of hydatid cysts of the liver. *Surg Gynecol Obstet* 1990 ;170(3):233-8.
7. Kanko M, Akbas H, Liman T, Berki KT. Persistent pleural effusion after open heart surgery: giant hydatid cyst of the liver and its demonstrative images. A case report. *Heart Surg Forum* 2005;8(5):E378-9.

Author Information

Levent Yilik

Department of Cardiovascular Surgery, İzmir Atatürk Training and Research Hospital

Ufuk Yetkin

Department of Cardiovascular Surgery, İzmir Atatürk Training and Research Hospital

Berkan Özpak

Department of Cardiovascular Surgery, İzmir Atatürk Training and Research Hospital

Ahmet Özelçi

Department of Cardiovascular Surgery, İzmir Atatürk Training and Research Hospital

İsmail Yürekli

Department of Cardiovascular Surgery, İzmir Atatürk Training and Research Hospital

Murat Aksun

Department of Cardiovascular Surgery, İzmir Atatürk Training and Research Hospital

Ali Gürbüz

Department of Cardiovascular Surgery, İzmir Atatürk Training and Research Hospital