Right Sided Pleural Effusion After Central Venous Catheterization: A Case Report And Review Of Literature

S Moosavi, P Kharazm

Citation

S Moosavi, P Kharazm. *Right Sided Pleural Effusion After Central Venous Catheterization: A Case Report And Review Of Literature*. The Internet Journal of Surgery. 2005 Volume 8 Number 1.

Abstract

Pleural effusion is a rare complication of central venous catheters. It is usually due to malpositioned catheter. Our patient was a 74-year-old man underwent transhiatal esophagectomy because of distal esophageal carcinoma. A cervical central vein catheter was placed into his right jugular vein after induction of anaesthesia. In postoperative chest x ray we encountered right side pleural effusion and drained it with a chest tube. During following days the patient has daily drainage of almost 2 liter of clear yellowish fluid from chest tube. Fluid analysis was not diagnostic. We removed the central vein catheter and plural drainage was stopped.

INTRODUCTION

Central venous catheterization is one of the most common minor surgical procedures used for cardiopulmonary monitoring or total parenteral nutrition. Several complications have been reported in relation to central venous catheterization including infection, malposition, hemorrhage, venous thrombosis, and life threatening superior vena cava or cardiac perforation [1,2]. Pleural effusion is a relatively rare complication of central catheters caused by pleural perforation by catheter during catheterization [1]. We present a new case of this complication.

CASE REPORT

The patient was a 74-year-old man referred to Shohada-E-Tajrish hospital because of a 4 month history of dysphagia. He wasn't able to eat anything except for liquids. On physical examination he had no significant finding. In upper GI endoscopy a 3 cm tumor was found 36cm distant to incisor teeth which was biopsied. Pathologic examination revealed a poorly differentiated adenocarcinoma arising in a bed of barrett's esophagus. Routine studies and metastatic work ups showed no sign of systemic disease. He was prepared for operation. After induction of anaesthesia a cervical central vein catheter was placed into his right jugular vein for cardiopulmonary monitoring and a transhiatal esophagectomy was performed. In postoperative chest x ray we encountered right side pleural effusion. Since pleural injury is not a rare complication of transhiatal esophagectomy, we drained it with a chest tube (Figure 1).

Figure 1

Figure 1: Chest x ray after chest tube insertion shows good expansion without significant remaining effusion

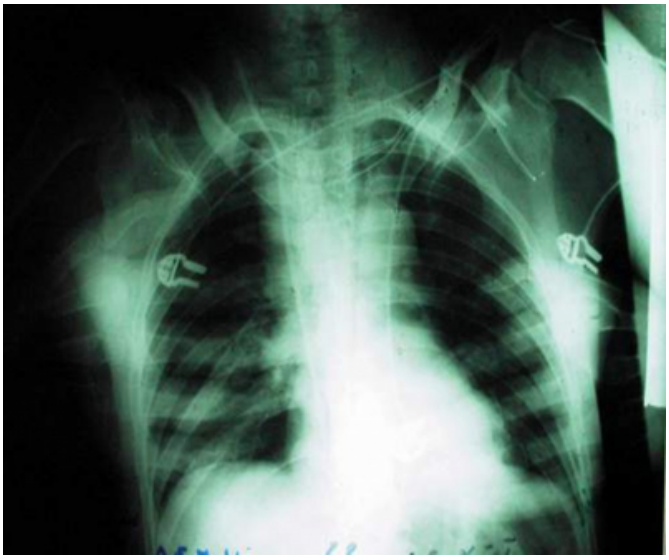

It contained of approximately 1.5 liter serosanginous fluid. During following days the patient has daily drainage of almost 2 liter of clear yellowish fluid with x rays showing different degrees of effusion (Figure 2). We send the fluid for laboratory which reported it free from cells and contained 2 g/dl of glucose, while the blood glucose was114 mg/dl at the same time. We suggested that it may be due to intra pleural positioning of the cervical catheter. We aspirated the catheter and blood returned to the syringe

without any problem and chest x rays showed that the tip of the catheter is in a suitable position. Paying more attention we noticed the angulation of the catheter in x rays (Figure 2).

Figure 2

Figure 2: Chest x ray in fourth post operative day shows right sided pleural effusion in spite of chest tube drainage. Look at the angulation of the cervical catheter.

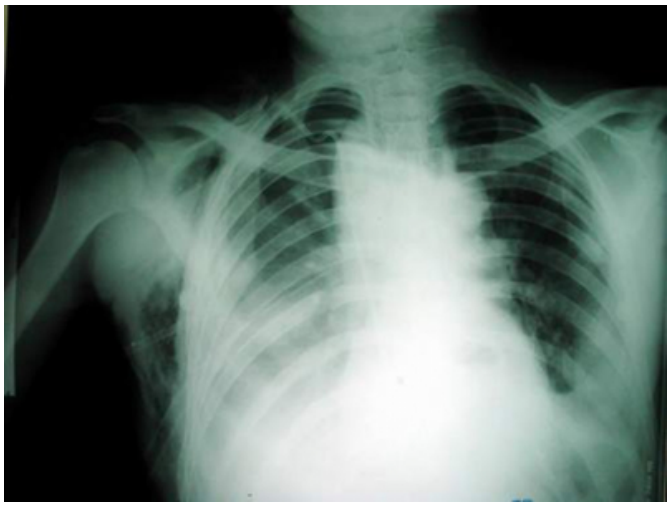

As a diagnostic study, we stopped any fluid infusion from catheter and used a peripheral venous access. The thoracic secretion was discontinued. Then we removed the catheter and two days later the chest tube was removed. Both lungs were full expanded without any effusion in control x rays (Figure 3).

Figure 3

Figure 3: Chest x ray after removal of cervical catheter and chest tube shows normal expansion of both lungs without significant effusion

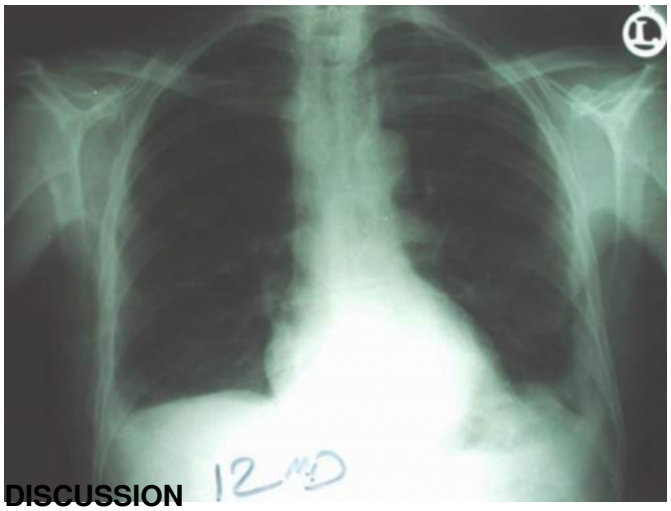

DISCUSSION

Pleural effusion secondary to vascular perforation and leakage of total parenteral nutrition (TPN) is a rare complication of central lines [3]. Although it is usually unilateral, three cases of bilateral effusion have been reported [4]. The incidence of this complication appears to be approximately 0.4-1.0 % of catheter placements, but it may be higher considering that some cases remain unrecognized [5]. Catheterization via the internal jugular vein may result in fewer malpositions than catheterization via the subclavian vein [6]. Generally, catheterization via the left internal jugular vein results in more malposition and vascular perforation than a catheter placed from the right internal jugular vein [4]. In most reported cases it was impossible to aspirate blood from the catheter when pleural effusion had occurred [4]. But in our case when we aspirated the catheter, blood filled the syringe. It showed that the tip of the catheter was in the lumen of the vein and x ray suggested the perforation of the catheter where it was angulated and it was proved when we removed the catheter and inspected it.

ACKNOWLEDGMENT

Dr Moosavi, The chief surgeon; Pezhman Kharazm, assistant surgeon and literature researcher

References

1. Youngberg B. The Risk Manager's Desk Reference. Second edition, Jones and Bartlett, 1998; p 320
2. Burchard K, Gann D, Wiles C. The Clinical Handbook of Surgical Critical Care. First edition, Taylor & Francis.2001; pp 36-7
3. Diaz M, Lorda I, Sanchez C, Gutierrez I, Monton JM, Vidal A. Milky-white pleural effusion complicating peripherically inserted central venous catheter for total parenteral nutrition.Eur J Clin Nutr. 2005 Feb;59(2):302-3
4. Paw H. G. W. Bilateral pleural effusions: unexpected complication after left internal jugular venous catheterization for total parenteral nutrition. Br J Anaesth 2002; 89: 647-50
5. Bouros D. Pleural Disease. first edition. Marcel Dekker, 2004; p 897
6. Dunbar RD, Mitchell R, Lavine M. Aberrant locations of central venous catheters. Lancet 1981; 1: 711-5

Author Information

Seyyed Reza Moosavi
Associate professor, Department of Surgery, Shohada-E-Tajrish Hospital

Pezhman Kharazm
Resident, Department of Surgery, Shohada-E-Tajrish Hospital