

An Oncocytoma Associated With Acquired Cystic Disease of Kidney: A Case Report and Review of the Literature

Z Pan, C Deng, E Adickes

Citation

Z Pan, C Deng, E Adickes. *An Oncocytoma Associated With Acquired Cystic Disease of Kidney: A Case Report and Review of the Literature*. The Internet Journal of Nephrology. 2007 Volume 4 Number 2.

Abstract

Oncocytoma is the most common benign solid renal tumor that accounts for approximately 3-7% of all renal neoplasms. Oncocytoma associated with acquired cystic kidney disease (ACKD) is rare, and so far only five cases have been reported in patients on hemodialysis. We here report an oncocytoma associated with ACKD in a patient without history of hemodialysis or familial cystic renal disease. A brief review of the literature is also presented.

INTRODUCTION

Oncocytoma is a benign renal neoplasm that is usually identified incidentally on imaging study. ACKD is commonly seen in patients on hemodialysis with end stage renal disease [1]. The major complications of ACKD are hemorrhage and neoplasia that includes adenoma, oncocytoma and renal cell carcinoma (RCC) [1]. In patients with ACKD, the benign adenoma and oncocytoma have a higher incidence rate than that of RCC, and therefore, in the patients with ACKD and renal tumor, a clinicopathological investigation may be required before a nephrectomy. In our report, an 82-year-old male was incidentally found to have numerous simple cysts in bilateral kidneys, and a solid mass was also identified in the lower pole of the right kidney. Following a nephrectomy of the right kidney, a classic oncocytoma was reported. The patient does not have any family history of cystic renal disease and has never been on hemodialysis due to any end stage renal disease.

CASE REPORT

An 82-year-old gentleman had a history of hypertension, benign prostate hyperplasia and essential thrombocytopenia. He had a transurethral resection of the prostate (TURP) in 1992 due to benign prostate hypertrophy. In 2002, he underwent a second TURP, and 10 months later, he had a transurethral resection of bladder neck contracture due to severe bladder outlet obstructive symptoms. In 2007, he came to the clinic with a complaint of weight loss and fatigue for the past four months, and he also felt a lump in the abdomen without constipation, diarrhea or bloody stool. A subsequent CT scan showed multiple large simple cysts in

bilateral kidneys that had a thin wall with a uniform low attenuation (Figure 1A). An enhancing exophytic mass in the lower pole of the right kidney was identified, which was solid with a heterogeneous attenuation and measured up to 6.0 cm in maximal dimension (Figure 1B). The liver, lung and pancreas were free of mass or cyst, and no pelvic mass or lymphadenopathy was present. The patient has no familial history of cystic renal disease. A malignant tumor was highly suspected and the patient then underwent an open nephrectomy.

Grossly, the renal specimen weights 373 grams and the surface is distorted by multiple thin-wall cysts from 1.0 cm to 5.0 cm in diameter. Upon bisecting the kidney, the renal parenchyma and pelvis are distorted by numerous simple cysts at various sizes (Figure 1C). The cysts contain clear-yellow to dark-brown fluid and the inner walls of the cysts are smooth. A well-demarcated mass is noted in the lower pole of the kidney with a solid brown, yellow cut surface (Figure 1C and 1D). The tumor measures 5.0x5.0x5.5 cm and is restricted in the renal capsule with a pushing border. The renal artery, vein and ureter are grossly free of tumor invasion.

Microscopically, the tumor cells are arranged in a glandular, cord, sheet or nested pattern in a capillary-rich background. There are focal areas with abundant myxoid stroma, especially in the center of the tumor. The tumor cells are large, polygonal with abundant bright pink cytoplasm that is filled with numerous finely, eosinophilic granules (Figure 2A and 2B). The tumor cells have one smooth round nucleus with clumped chromatin and a centrally placed nucleolus.

There is no marked atypia or polymorphism present in the tumor, and no vascular, nerve or capsular invasion is noted. Multiple benign simple cysts are also noted microscopically (Figure 2C and 2D), and the cysts do not contain lining epithelium. A Hale's colloid iron staining shows focally weak luminal positivity in the tumor nests. Immunohistochemistry stains demonstrate that the tumor cells have diffuse strong positivity for CD117 (Figure 2E) and scattered strong reaction to CK7 (Figure 2F) but negative for RCC, CD10 and vimentin. Ultrastructurally, the tumor consists of large polygonal cells with abundant cytoplasm that is filled with numerous enlarged, rounded mitochondria (Figure 2G and 2H). All these features support a diagnosis of benign oncocytoma.

Figure 1

Table 1: a summary of the case reports on oncocytoma associated with ACKD

| Author, Year | Gender/Age | History |
|---------------------------|------------|---|
| Hashimoto et al, 2005 [5] | M/56 | Hemodialysis for 15 years due to chronic renal failure |
| Lu, et al, 2001 [6] | M/67 | Hemodialysis for 5 years due to hypertension-associated end-stage renal disease |
| Satoh, et al, 1998 [7] | F/56 | Hemodialysis for 6 years |
| Fachai et al, 1993 [8] | N/A | Hemodialysis for 2 years due to chronic end renal insufficiency |
| Makita, et al, 1991 [9] | F/38 | Hemodialysis for 7 years |

Figure 2

Figure 1: A, CT scan shows multiple large simple cysts in bilateral kidneys; B, A solid mass in the lower pole of the right kidney is identified; C and D, gross renal specimen shows multiple cysts, and a well-demarcated mass is noted in the lower pole with a solid brown, yellow cut surface.

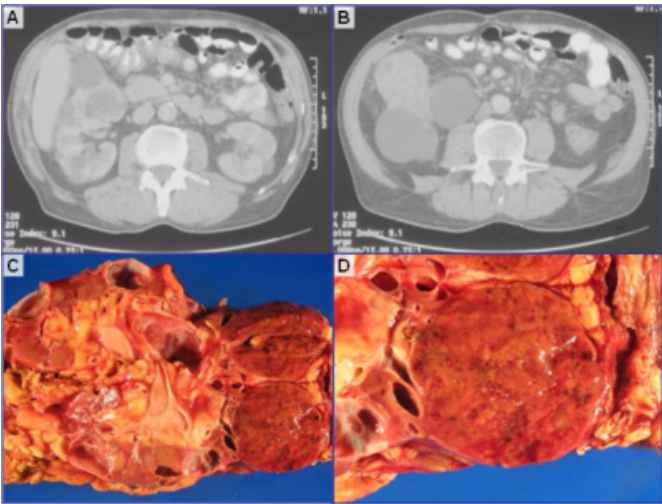
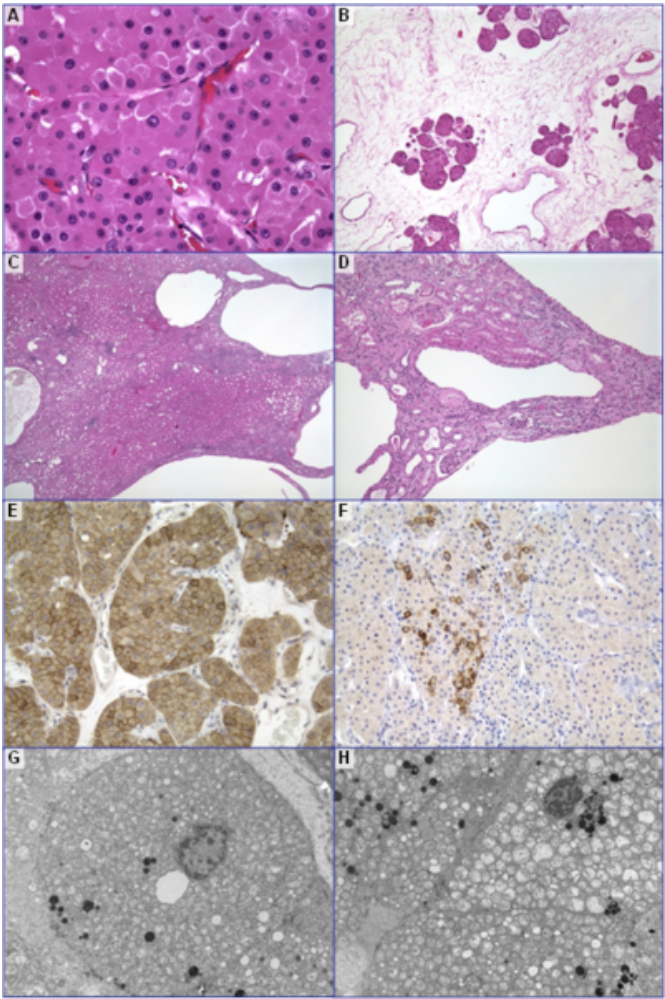


Figure 3

Figure 2: A, the tumor cells are large, polygonal with abundant bright pink granular cytoplasm and one smooth round nucleus; B, focal areas have abundant myxoid stroma; C and D, many benign simple cysts are noted; E, the oncocytes have diffuse strong positivity for CD117; F, tumor cells have scattered strong reaction to CK7; F and G, ultrastructurally, the tumors are filled with numerous enlarged, rounded mitochondria in the cytoplasm.



DISCUSSION

Oncocytoma is the most common benign solid renal tumor with a mean age of 62-68 years at diagnosis, which originates from the intercalated cells of the renal collecting duct. Oncocytoma accounts for approximately 3-7% of all renal neoplasms, and 2-12% of the oncocytomas are multifocal and 4-14% of the cases are bilateral [2, 3]. Most patients with oncocytomas are asymptomatic and the tumors are usually detected incidentally on imaging studies for another indication. Some patients present with symptoms such as hematuria, flank pain, and an abdominal mass. Oncocytoma has a characteristic cut surface that appears

homogeneous with a unique mahogany color, and a characteristic fleshy central scar is observed in 33-54% of such cases. The oncocytes in the tumor contain abundant bright pink cytoplasm that is filled with numerous mitochondria when visualized under electron microscopy. Our case has a typical appearance of the cut surface although no central scar is present. The features under the light microscopy and the electron microscopy are classic. The immunohistochemical stainings show a typical diffuse CK117 positivity and scattered CK7 strong reaction without vimentin expression. Chromophobe renal cell carcinoma (RCC) also shows granular eosinophilic cytoplasm and is among the top differential diagnoses. However, the tumor cells in chromophobe RCC have perinuclear clearing with diffuse strong reaction to CK7, vimentin and colloid iron stains.

Renal cystic disease can be hereditary, developmental or acquired. Acquired cystic kidney disease (ACKD), also called acquired renal cystic disease (ARCD), is characterized by the development of numerous fluid-filled cysts in bilateral kidneys in individuals who have no history of hereditary cystic disease. It is highly associated with hemodialysis, and the prevalence of ACKD is 7-22% in predialysis population, 44% within 3 years after dialysis, 79% more than 3 years after dialysis, and 90% more than 10 years after dialysis [4]. Patients with hypertension or benign prostate hyperplasia are also at a high risk of developing ACKD. However, the exact mechanism of the cystic formation is not known. ACKD gives rise to many significant complications, one of which is the development of renal cell neoplasms. In ACKD patient, benign tumor (adenoma and oncocytoma) and renal cell carcinoma occur at respective rates of 4.8% and 0.6-1.5% [1]. In patients with oncocytoma and ACKD, the renal functions may be already suboptimal, and these patients may be managed conservatively. In some cases, the surgeons may perform nephrectomy without doing further workup to make an accurate diagnosis. Therefore, a careful clinicopathological investigation should be required in patients with ACKD and renal tumor, and in these patients, a fine needle biopsy or an intra-operative frozen section is highly suggested in guiding

further workup.

To date, few cases of oncocytoma with ACKD have been reported with only five cases in patients on hemodialysis (Table 1). In our case, the patient has never been on hemodialysis, and there is no family history of cystic renal disease. However, he does have a long history of hypertension and benign prostate hyperplasia with obstruction symptoms, both of which put him at a risk of developing ACKD.

CORRESPONDENCE TO

Edward D. Adickes, D.O. Department of Pathology
Creighton University Medical Center Omaha, NE 68131,
USA TEL: (402) 977-5611 FAX: (402) 449-0609 E-mail:
EdwardAdickes@creighton.edu

References

1. Basile JJ, McCullough DL, Harrison LH, Dyer RB. End stage renal disease associated with acquired cystic disease and neoplasia. *J Urol.* 1988 Nov;140(5):938-43. (PMID: 3172362)
2. Schatz SM, Lieber MM. Update on oncocytoma. *Curr Urol Rep.* Feb 2003;4(1):30-5. (PMID: 12537936)
3. Dechet CB, Bostwick DG, Blute ML, Bryant SC, Zincke H. Renal oncocytoma: multifocality, bilateralism, metachronous tumor development and coexistent renal cell carcinoma. *J Urol.* Jul 1999;162(1):40-2.
4. Mattoo TK, Greifer I, Geva P, Spitzer A. Acquired renal cystic disease in children and young adults on maintenance dialysis. *Pediatr Nephrol.* 1997 Aug;11(4):447-50.
5. Hashimoto T, Togo Y, Yasuda K, Fukui K, Nagakai J, Nakao A, Higuchi Y, Maruyama T, Yamamoto S, Kondo N, Nojima M, Takiuchi H, Mori Y, Hirota S, Shimai H. Oncocytoma associated with acquired cystic disease of kidney (ACDK): a case report. *Hinyokika Kiyo.* 2005 Nov;51(11):747-9. (PMID: 16363707)
6. Lu TC, Lim PS, Hsu WM, Wang TH, Liu ST. Renal oncocytoma in acquired renal cystic disease. *J Formos Med Assoc.* 2001 Jul;100(7):488-91. (PMID: 11579616)
7. Satoh T, Nagata M, Nukui F, Kurokawa J, Okamoto S, Fukui J, Ohiwa T. A case of renal oncocytoma associated with acquired cystic disease of the kidney. *Hinyokika Kiyo.* 1998 July; 44(7):493-6. (PMID: 9752605)
8. Fachal Bermúdez C, Carretero Albiñana L, Coma del Corral MJ, Fernández Matía G, Gutierrez Mínguez E. Renal oncocytoma in acquired cystic diseases. *Actas Urol Esp.* 1993 May;17(5):333-6.
9. Makita Y, Inenaga T, Kinjo M, Komatsu K, Onoyama K, Fujishima M. Renal oncocytoma developed in a long-term hemodialysis patient. *Nephron.* 1991;57(3):355-7.

Author Information

Zenggang Pan, M.D., Ph.D.

Department of Pathology, Creighton University Medical Center

Caishu Deng, M.D.

Department of Pathology, Creighton University Medical Center

Edward D. Adickes, D.O.

Department of Pathology, Creighton University Medical Center