

An incidental finding of ectopic liver tissue on the gallbladder of two patients during routine elective laparoscopic cholecystectomy

A Malhas, M Howlader, I Chishti, M Siddiqui

Citation

A Malhas, M Howlader, I Chishti, M Siddiqui. *An incidental finding of ectopic liver tissue on the gallbladder of two patients during routine elective laparoscopic cholecystectomy*. The Internet Journal of Surgery. 2007 Volume 16 Number 1.

Abstract

The presence of ectopic liver tissue is a rare developmental abnormality that has previously been found during autopsy and during laparoscopic procedures in the abdomen. We present two cases of incidental ectopic liver tissue on the gallbladder during elective laparoscopic cholecystectomy.

INTRODUCTION

The presence of ectopic liver tissue is a rare developmental abnormality that has previously been found during autopsy and during laparoscopic procedures in the abdomen [1,2,3,4,5,6,7,8,9,10,11]. It has only been described in case reports.

We present two cases of incidental ectopic liver tissue on the gallbladder during elective laparoscopic cholecystectomy. A further review of the world literature of case reports was then performed.

CASE REPORT 1

A 39-year-old lady presented to hospital with a one-month history of right upper quadrant pain. The pain was typical of biliary colic and was associated with vomiting. Past medical history included mild lupus, chronic back pain and depression. She was clinically obese.

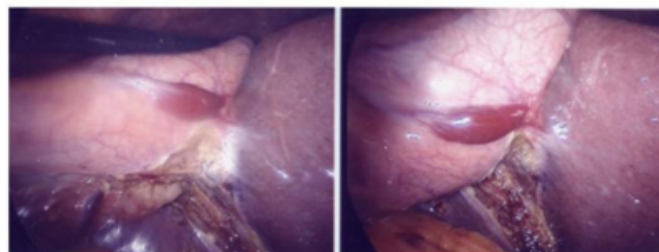
Examination revealed right upper quadrant tenderness. Blood tests revealed normal liver function, renal function, a normal white cell count and a haemoglobin level of 11.3 g/dL. She was admitted and an ultrasound scan demonstrated several gallstones in the gallbladder and a normal common bile duct. Although her symptoms settled with conservative management she continued to have epigastric pain. She underwent a gastroscopy, which demonstrated oesophagitis and she was treated with proton pump inhibitors.

She was discharged and later underwent an elective laparoscopic cholecystectomy which was completely uneventful. However, at time of surgery she was found to

have an ectopic liver tissue on the gallbladder attached to the liver by a pedicle (Figure 1). Histology demonstrated normal hepatic tissue. She made an uneventful postoperative recovery and remains symptom-free since discharge.

Figure 1

Figure 1



CASE REPORT 2

A 42-year-old gentleman attended the A & E department in April 2006 with right upper quadrant pain consistent with biliary colic. He had no previous medical history but was clinically obese (BMI 42).

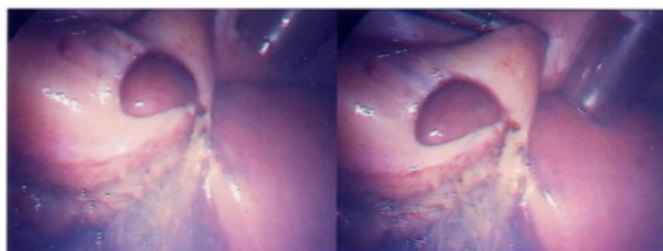
Blood tests demonstrated marked liver function derangement (Bilirubin 70 mmol/L (~4 mg/dl), ALP 244 U/L, ALT 497 U/L, Gamma GT 270 U/L). He was admitted and a subsequent ultrasound scan demonstrated: an echogenic focus in the lumen of the gallbladder suggestive of small calculi with a normal common bile duct and fatty infiltration of the liver. He was managed conservatively and was subsequently discharged.

He underwent an elective laparoscopic cholecystectomy in

August 2006 and was found to have a small ectopic liver on the gallbladder which was discrete from the liver (Figure 2). Histology demonstrated normal hepatic tissue. He had an uneventful recovery and was discharged with no further issues.

Figure 2

Figure 2



DISCUSSION

As the histological reports of the two specimens showed normal hepatic parenchyma, we feel that the ectopic tissue appeared to be incidental to the underlying pathology of gallstones.

Anatomists have described the presence of ectopic liver lobes in the perinatal liver (11.5% of cases [10]). The persistence of these ectopic tissues markedly drops in the adult (>0.5% based on autopsy [11]). They can be found on the gallbladder, hepatic ligament, thorax and the retroperitoneum [6]. They can be attached to the liver (and hence an accessory lobe) or a discrete island of hepatic tissue [10].

The ectopic liver tissue is subject to environmental changes and cirrhosis of ectopic tissue has been noted [13]. There have been case reports of primary hepatocellular carcinoma in ectopic tissues (with a tumour-free liver) [13,14,15]. There has been some suggestion that ectopic liver tissue is more prone to cirrhotic and neoplastic changes [13].

Ectopic liver tissue has been reported to have had a compression effect in two case studies: on the pylorus [16] and on the portal vein [17].

SUMMARY

Ectopic liver tissue is a rare developmental abnormality that

is often an incidental finding on laparoscopic procedures.

ACKNOWLEDGEMENTS

Many thanks to the patients who allowed their cases to be discussed.

CORRESPONDENCE TO

Amar Malhas BSc MB BS MRCS SHO in Surgery 1. Queen Elizabeth Hospital NHS, 2. 2 Scarsdale Villas Stadium road, Kensington, Woolwich, London, London, England W8 6PR E18 4QH Email: amarmalhas@hotmail.com

References

1. Pollack and Burton. Accessory lobes of the liver. California Medicine 1953; Vol. 78, No. 6.
2. Ashby. Accessory liver lobe attached to the gallbladder. Br J Surgery 1969; 56: 311-312.
3. Natori et al. Intra-cholecystic ectopic liver. Acta Pathologica Japonica 1986; Vol. 36, PT 8: 1213-6.
4. Fellbaum, Beham and Schmid. Isolierte Nebenleber (hepar succenturiatum) am Gallenblasenhals. Wien Klin Wochenschr 1987; 99: 825-7.
5. Tejada and Danielson. Ectopic or heterotopic liver (choristoma) associated with the gallbladder. Arch Pathol Lab Med 1989; 113: 950-2.
6. Watanabe et al. Five cases of ectopic liver and a case of accessory lobe of the liver. Endoscopy 1989; 21: 39-42.
7. Svane and Knudtzon. Ektopisk lever i galleblaere og kolestase. Tidsskr Nor Laegeforen nr. 21, 1991; 111: 2643-4.
8. Acar, Tacylidiz and Karakayali. Ectopic liver tissue attached to the gallbladder. Acta Chir Belg 2002; 102: 210-1.
9. Sakarya et al. Ectopic liver (choristoma) associated with the gallbladder encountered during laparoscopic cholecystectomy: a case report. Surg Endosc. 2002; 16: 1106.
10. Wang. Ectopic liver tissue in the gallbladder. Zhonghua Gan Zang Bing Za Zui. 2006; 14: 369.
11. Parke et al. Malformations of the Liver: Some prenatal and postnatal developmental aspects. Clinical Anatomy 1996; 9: 309-316.
12. Eiserth. Beitrage zur Kenntnis der Nebenlebern. Virchows Arch Pathol Anat 1940; p.307.
13. Arakawa M et al. Propensity of ectopic liver to hepatocarcinogenesis: case reports and a review of the literature. Hepatology 1999; 29: 57-61.
14. Tamura et al. A case of ectopic liver cancer - hepatocellular carcinoma that developed in the gallbladder. Jpn J Gastroenterology 1985; 82: 2448.
15. Ichikawa et al. Six cases of extrahepatic growing hepatocellular carcinoma - clinicopathological classification and surgical therapy. Acta Hepatol Jpn. 1984; 25: 806-812.
16. Haddad et al. Pyloric obstruction by ectopic liver tissue. Br J Surg 1985; 72: 917.
17. Mateley, Rhode and Cywes. Portal vein obstruction by ectopic liver tissue. J Paed Surg 1989; 24: 1163-64.

Author Information

Amar Malhas, SHO in General Surgery

Queen Elizabeth Hospital, NHS Trust England

Mohammed Howlader, SPR in General Surgery

Queen Elizabeth Hospital, NHS Trust England

Imran Chishti, SPR in General Surgery

Queen Elizabeth Hospital, NHS Trust England

Midhat Siddiqui, Consultant Upper GI Surgeon

Queen Elizabeth Hospital, NHS Trust England