

# Superior Mesenteric Artery Syndrome After Restorative Proctocolectomy With Ileal Pouch-Anal Anastomosis: A Case Report

J Haddow, S Sangal, P Agarwal

---

## Citation

J Haddow, S Sangal, P Agarwal. *Superior Mesenteric Artery Syndrome After Restorative Proctocolectomy With Ileal Pouch-Anal Anastomosis: A Case Report*. The Internet Journal of Surgery. 2006 Volume 13 Number 1.

## Abstract

**Purpose:** Superior mesenteric artery syndrome (SMAS) is a rare complication following restorative proctocolectomy with only eight previous reports. We report the case of a 16-year-old girl known to have familial adenomatous polyposis who underwent a restorative proctocolectomy with an ileal pouch-anal anastomosis.

**Methods:** The features of the case were studied followed by a review of the current literature.

**Results:** After an uneventful first postoperative week, the patient developed SMAS, characterised by voluminous bilious vomiting. Laparotomy revealed compression of the duodenum by the overlying mesenteric root containing the superior mesenteric artery. Unexpected dense peri-mesenteric and intraperitoneal fibrosis was also encountered.

**Conclusion:** Previous reports suggested the aetiology is directly related to the accentuated angle between the superior mesenteric artery and the aorta, which is created at the time of surgery. Our case suggests that it may actually be events in the postoperative period such as fibrosis of the mesentery that are responsible. When surgical intervention is required, we advocate duodenojejunostomy as the preferred solution.

## INTRODUCTION

Compression of the duodenum by the superior mesenteric artery is a rare complication following restorative proctocolectomy. We report an interesting case in point, consider the possible aetiological factors, and discuss the management of the condition.

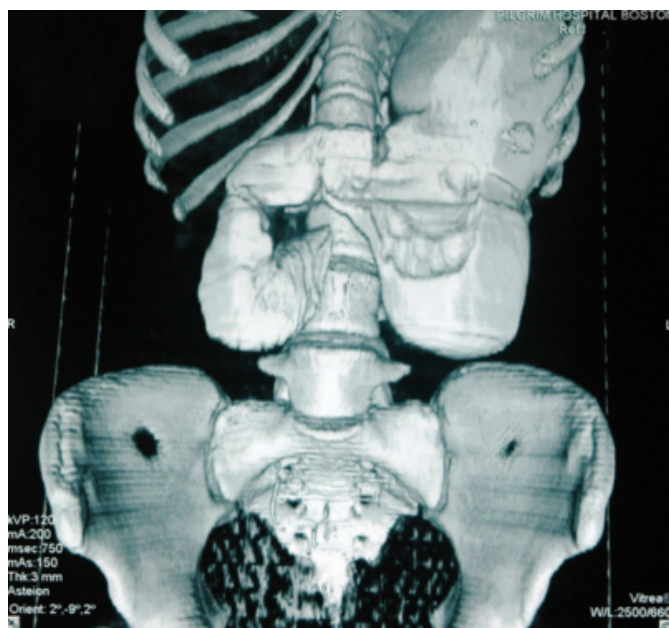
## CASE REPORT

A 16-year-old girl known to have familial adenomatous polyposis underwent a restorative proctocolectomy with anastomosis of a J-shaped ileal pouch to the anal canal and fashioning of a covering loop ileostomy. The small bowel mesentery was mobilised close to its root and the ileocolic artery was divided, facilitating an anastomosis free from any tension. The initial post-operative course saw a timely reinstatement of her normal diet with a satisfactory stoma function. On the eighth day, she developed significant fresh rectal bleeding, which although required a blood transfusion, was self-limiting. The anastomosis felt intact on digital rectal examination.

On the tenth day, she complained of significant pain in her left iliac fossa and had voluminous bilious vomiting. The ileostomy continued to function normally and there were no other signs suggestive of bowel obstruction. Plain abdominal radiography was normal. A computed tomography scan demonstrated a distended stomach and duodenum to its third part (see figure 1). Total parenteral nutrition was started and she was managed expectantly.

**Figure 1**

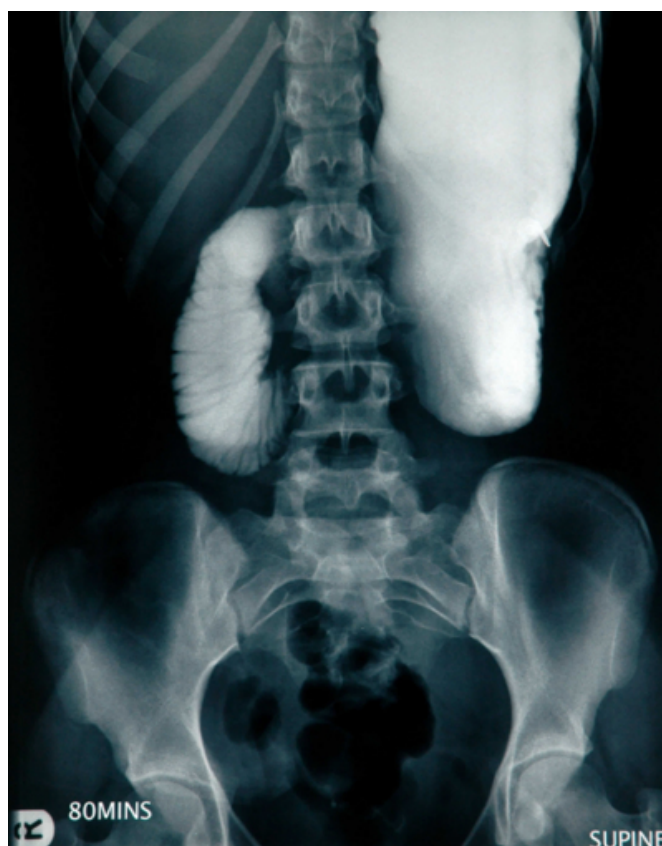Figure 1: Computed tomography 3D reconstruction showing oral contrast arrested in the third part of the duodenum with proximal dilation of the stomach and duodenum.



On the sixteenth day, after no clinical improvement and continued vomiting, a contrast study was performed which demonstrated a complete obstruction of the duodenum at its third part (see figure 2). Laparotomy performed on the same day revealed the duodenum obstructed at its third part by the overlying leaf of the mobilised mesentery containing the superior mesenteric artery. Unexpected dense adhesions involving the root of the mesentery and throughout the peritoneum were also found.

**Figure 2**

Figure 2: Contrast study showing complete obstruction of the duodenum at its third part.



A duodenojejunostomy was performed to bypass the obstruction. A steady and uneventful recovery followed where oral intake commenced after a week and discharge occurred after two weeks.

## DISCUSSION

Restorative proctocolectomy with ileal pouch-anal anastomosis is widely practiced in cases of familial adenomatous polyposis. Early complications include pelvic sepsis, anastomotic leakage, wound infection, haemorrhage and ileostomy dysfunction.

Superior mesenteric artery syndrome (SMAS), whereby the duodenum is compressed against the aorta by the overlying mesentery, is a rare, early complication following restorative proctocolectomy. There have only been eight other reported cases [1,2,3,4,5,6,7]. It has been more readily described as a consequence of acute weight loss, spinal surgery, or neurological injury [8].

Current theory suggests the aetiology is directly related to the accentuated angle between the superior mesenteric artery

(SMA) and the aorta, which is brought about by mobilisation of the mesentery down towards the pelvis [1,2,3]. It has been suggested that loss of the duodenal fat pad, indicated by a low body mass index, is a prerequisite to developing the syndrome [9], but this has recently been refuted [8].

However, in our case, the patient only developed intestinal obstruction after 10 days during which a normal diet and stoma function had been achieved. There was no tension on the anastomosis at the time of its construction, and the vascular supply to the ileal pouch was never compromised. Compression of the duodenum must therefore have occurred after the first week following the operation. The discovery of dense peri-mesenteric and intraperitoneal fibrosis so shortly after the primary procedure was unexpected, and may offer an insight into the aetiology of SMAS.

We propose that SMAS following restorative proctocolectomy may occur as a consequence of postoperative events. Our hypothesis is that a fibrotic reaction within the mesentery causes its gradual contraction during the early postoperative period. Where the initial length of the mesentery may have been adequate, subsequent shortening gives rise to compression of the underlying duodenum. As the mesentery actually shortens, the superior mesenteric vessels are neither stretched nor impinged, explaining the absence of vascular compromise to the ileal pouch.

Superior mesenteric artery syndrome secondary to restorative proctocolectomy has been successfully managed expectantly by employing nasogastric drainage and prolonged parenteral nutrition, achieving resolution in 14 to 18 days [1,3]. In other instances, duodenal division with re-anastomosis anterior to the SMA [2,5], gastrojejunostomy [6] and Strong's procedure [4] (mobilisation of the duodenum inferiorly by division of its retroperitoneal attachments and the ligament of Treitz [10]) have all been utilised with a satisfactory outcome. We successfully employed a duodenojejunostomy and believe it should be the procedure of choice in this situation: the integrity of the duodenum is at less risk compared with dividing the duodenum and there is less reflux of bile into the stomach compared with gastrojejunostomy.

## CONCLUSION

Superior mesenteric artery syndrome is a rare complication of restorative proctocolectomy. Our case suggests that events in the postoperative period such as fibrosis may be implicated in its pathogenesis. When surgical intervention is required, we advocate duodenojejunostomy as the preferred solution.

## CORRESPONDENCE TO

Mr James B Haddow 2 Trellis Drive, Basingstoke RG24 8YU T: +44 7788 723535 F: +44 1256 816540 E: james.haddow@mac.com

## References

1. Ballantyne GH, Graham SM, Hammers L, Modlin IM. Superior mesenteric artery syndrome following ileal J-pouch anal anastomosis. An iatrogenic cause of early postoperative obstruction. *Dis Colon Rectum*. 1987; 30: 472-474.
2. Christie PM, Schroeder D, Hill GL. Persisting superior mesenteric artery syndrome following ileo-anal J pouch construction. *Br J Surg*. 1988; 75: 1036.
3. Tonelli F, Anastasi A, Mazzoni P, Batignani G, Monaci I, Ferretti P, Ficari F. Prevenzione della sindrome del compasso aorto-mesenterico negli interventi di ileo-ano-anastomosi. [The prevention of the aorto-mesenteric compression syndrome in interventions for ileoanal anastomoses]. *Ann Ital Chir*. 1993; 64: 675-679.
4. Goes RN, Coy CS, Amaral CA, Fagundes JJ, Medeiros RR. Superior mesenteric artery syndrome as a complication of ileal pouch-anal anastomosis. Report of a case. *Dis Colon Rectum*. 1995; 38: 543-544.
5. Ravindra KV, Rajasekhar P, Rozario AP, Pais AV, Thomas PG. Superior mesenteric artery syndrome following ileo-anal pouch procedure. *Indian J Gastroenterol*. 1999; 18: 35-36.
6. Essadel A, Benamr S, Taghy A, Lahlou MK, Mohamadine E, Chad B, Belmahi A. Une complication rare de l'anastomose iléoanale avec réservoir: le syndrome de la pince mésentérique. [A rare complication of ileal pouch anal anastomosis: superior mesenteric artery syndrome]. *Ann Chir*. 2001; 126: 565-567.
7. Matheus CO, Waisberg J, Zewer MHT, Godoy AC. Syndrome of duodenal compression by the superior mesenteric artery following restorative proctocolectomy: a case report and review of literature. *Sao Paulo Med J*. 2005; 123: 151-153.
8. Biank V, Werlin S. Superior mesenteric artery syndrome in children: a 20-year experience. *J Pediatr Gastroenterol Nutr*. 2006; 42: 522-525.
9. Burrington JD, Wayne ER. Obstruction of the duodenum by the superior mesenteric artery - does it exist in children? *J Pediatr Surg*. 1974; 9: 733-741.
10. Strong EK. Mechanics of arteriomesenteric duodenal obstruction and direct surgical attack upon etiology. *Ann Surg*. 1958; 148: 725-730.

**Author Information**

**James B. Haddow, MRCS**

Senior House Officer

**Sam Sangal, MRCS**

Specialist Registrar

**Pradeep K. Agarwal, FRCS**

Colorectal Surgeon