

Angiosarcoma, a Rare Neoplasm of the Liver: a Case Report and Review of Literature

G Maheshwari, N Shivathirthan, D Kamath, P Halder

Citation

G Maheshwari, N Shivathirthan, D Kamath, P Halder. *Angiosarcoma, a Rare Neoplasm of the Liver: a Case Report and Review of Literature*. The Internet Journal of Surgery. 2008 Volume 18 Number 2.

Abstract

We describe the case of a 44-year-old male with a rare malignant neoplasm of the liver: an angiosarcoma. This case is interesting because there was no history of exposure to the known carcinogens for this malignancy, and no predisposing chronic medical condition. We believe that this was a case of primary hereditary angiosarcoma, which has been rarely reported in the literature.

CASE REPORT

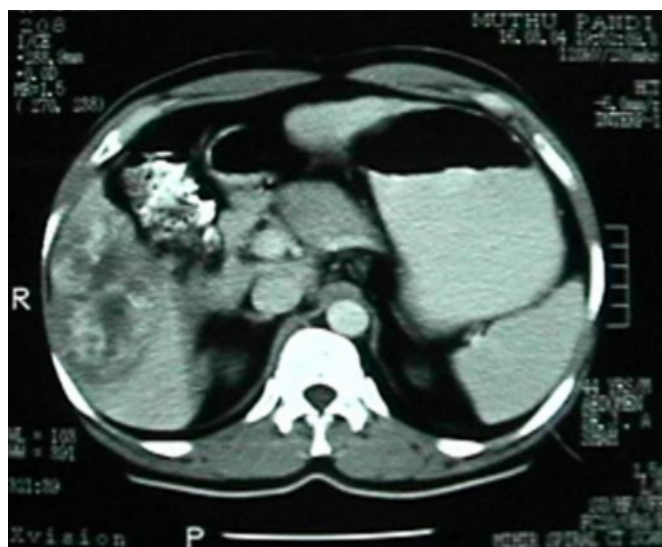A 44-year-old man, a chronic alcoholic with no significant medical history, was admitted with complaints of pain in the right upper quadrant of the abdomen, nausea and loss of appetite and weight for 4 months.

There was no abnormal finding on physical examination. Liver biochemistry and routine blood investigations were normal. Viral markers were normal. USG revealed evidence of chronic liver disease with a mass suggestive of hepatocellular carcinoma in the right lobe of the liver.

CT scan showed a 9 x 5.9 x 8.1cm heterogeneously enhancing mass lesion involving the right lobe of the liver (Fig. 1).

Figure 1

Figure 1: CT scan showing a heterogeneously enhancing mass lesion involving the right lobe of the liver

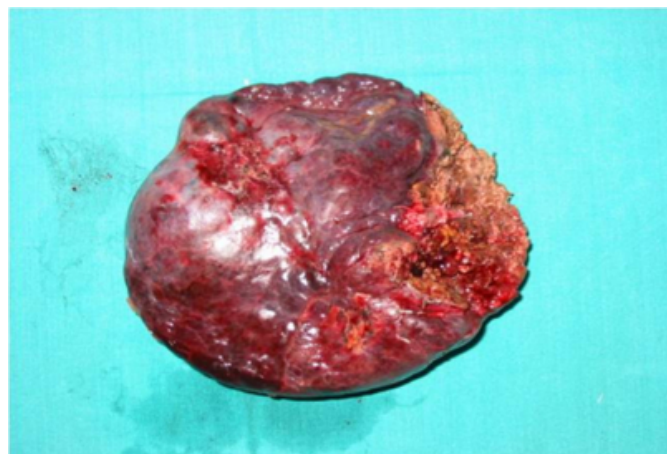


Tumour markers AFP and CEA were within normal range.

Right hepatectomy was performed and the post-operative period was uneventful (Fig. 2)

Figure 2

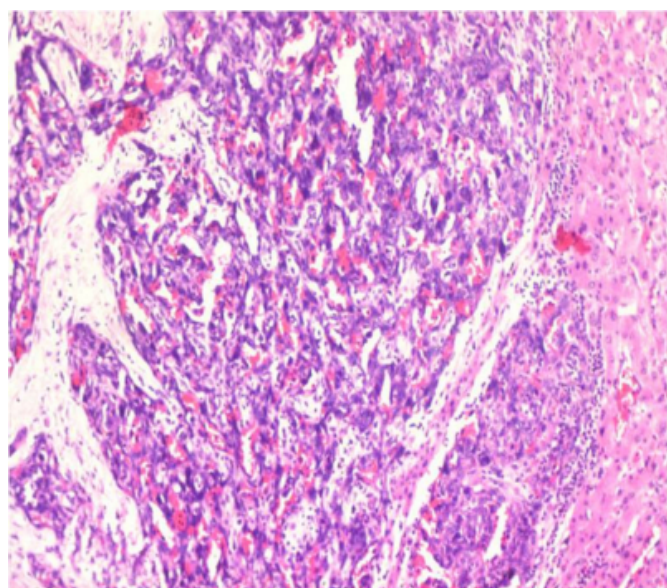
Figure 2: Resected gross specimen of the right lobe of the liver



Histopathology showed a poorly differentiated angiosarcoma with cavernoma formation (Fig. 3).

Figure 3

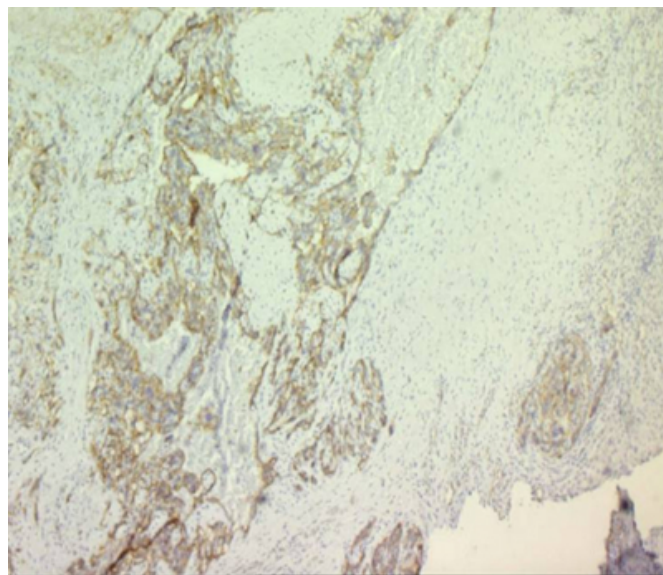
Figure 3: Histomicrograph of poorly differentiated angiosarcoma with cavernoma formation



Immunohistochemistry profile: CD 31, CD 34, factor 8 positive, confirmatory for angiosarcoma (Fig 4).

Figure 4

Figure 4: Immunohistochemistry profile confirmatory for angiosarcoma



Retrospectively there was no history of exposure to any of the known carcinogens for angiosarcoma.

On follow-up at 1 month and 3 months postoperatively the patient was asymptomatic. CT scan showed no evidence of focal lesion in the residual liver.

DISCUSSION

Angiosarcoma is responsible for about 2% of primary liver tumors¹, and is considered to be the most common of the mesenchymal liver tumors. About 25 cases occur each year in the United States. Males (ratio 3:1) in their fifth or sixth decade are most often affected², but it can also occur in children.³⁴ It often presents with abdominal discomfort and distension, weight loss, and fatigue. On examination, the patient may have jaundice, hepatomegaly, and ascites.⁵ Liver function tests are usually abnormal. Thrombocytopenia, microangiopathic haemolytic anaemia, and disseminated intravascular coagulation may also be present⁶. There are no tumour markers.

CT images classically show multiple hypodense areas. After administration of contrast medium, the lesions become partly or completely isodense with the normal hepatic tissue.⁷ On T2-weighted MRI imaging, there are areas of high signals with central regions of low signals. Liver biopsy is hazardous as it may cause severe haemorrhage⁸.

Macroscopically, 'blood lakes' may be seen as the tumor is angioinvasive. On histological examination, there are typical spindle-shaped hyperchromatic cells with nucleoli, which,

on immunostaining, are positive for endothelial cells markers.⁹

More than 30% of cases have been linked to exposure to environmental agents including Thorotrast® which was used as a radiological contrast agent in the past. Evidence of previous exposure is seen on a CT scan, and the latency period can be longer than 30 years.¹⁰¹¹

Angiosarcoma is also associated with exposure to vinyl chloride, which is used in rubber and plastic processing¹²¹³. Again the latency period can be very long. The risk ratio is 400:1 compared to the general population¹⁴ and may be due to increased frequency of p53 mutations in these people¹⁵. The incidence in this group has decreased since the acceptable exposure level to vinyl chloride has been reduced.

Angiosarcoma has also been reported to be associated with exposure to arsenic¹⁶, anabolic steroids¹⁷, and oral contraceptives.¹⁸ It has been reported in a previous haemangioma¹⁹, with Von Recklinghausen's neurofibromatosis²⁰, and in patients with certain hereditary conditions such as congenital hereditary lymphoedema (Milroy's disease)²¹ and Von Hippel Lindau disease.²²

Detailed history from our patient failed to reveal previous exposure to any of the known carcinogens or predisposing medical conditions. Our case is one of the few reports of primary angiosarcoma reported in literature.

CORRESPONDENCE TO

Dr Gaurav Maheshwari Dept of Surgical Gastroenterology
Jagjivanram Hospital, Mumbai Email:
drgauravmaheshwari@gmail.com

References

1. Neshiwat LF, Friedland ML, Schorr-Lesnick BS, et al. Hepatic angiosarcoma. *Am J Med* 1992;93:219-2.
2. Locker GY, Doroshow JH, Zwelling LA, Chabner BA. The clinical features of hepatic angiosarcoma: a report of four cases and a review of the English literature. *Medicine (Baltimore)* 1979;58:48-64.
3. Noronha R, Gonzalez-Crussi F. Hepatic angiosarcoma in childhood. A case report and review of the literature. *Am J Surg Pathol* 1984;8:863-71.
4. Selby DM, Stocker JT, Ishak KG. Angiosarcoma of the liver in childhood: a clinicopathologic and follow-up study of 10 cases. *Pediatr Pathol* 1992; 12:485-98.
5. Tordjman R, Eugene C, Clouet O, et al. Hepatosplenic angiosarcoma complicated by hemoperitoneum and disseminated intravascular coagulation. Treatment by arterial embolization and chemotherapy. *Gastroenterol Clin Biol* 1995;19:625-8.
6. Truell JE, Peck SD, Reiquam CW. Hemangiosarcoma of the liver complicated by disseminated intravascular coagulation. A case report. *Gastroenterology* 1973;65:936-42.
7. White PG, Adams H, Smith PM. The computed tomographic appearances of angiosarcoma of the liver. *Clin Radiol* 1993;48:321-5.
8. Hertzanu Y, Peiser J, Zirkin H. Massive bleeding after fine needle aspiration of liver angiosarcoma. *Gastrointest Radiol* 1990;15:43-6.
9. Fortwengler Jr HP, Jones D, Espinosa E, Tamburro CH. Evidence for endothelial cell origin of vinyl chloride-induced hepatic angiosarcoma. *Gastroenterology* 1981;80:1415-9.
10. Kojiro M, Nakashima T, Ito Y, et al. Thorium dioxide-related angiosarcoma of the liver. Pathomorphologic study of 29 autopsy cases. *Arch Pathol Lab Med* 1985; 109:853-7.
11. Abe M, Wakasa H. Thorotrast-induced hepatic angiosarcoma with 39 years latency. A pathologic and immunohistochemical study. *Acta Pathol Jpn* 1987; 37:1653-60.
12. Creech Jr JL, Johnson MN. Angiosarcoma of liver in the manufacture of polyvinyl chloride. *J Occup Med* 1974;16:150-1.
13. Hozo I, Andelinovic S, Ljutic D, et al. Two new cases of liver angiosarcoma: history and perspectives of liver angiosarcoma among plastic industry workers. *Toxicol Ind Health* 1997;13:639-47.
14. Heath Jr CW, Key MM. Nationwide surveillance of angiosarcoma of the liver [letter]. *Arch Environ Health* 1974;28:360.
15. Marion MJ. Critical genes as early warning signs: example of vinyl chloride. *Toxicol Lett* 1998;102-103:603-7.
16. Lander JJ, Stanley RJ, Sumner HW, et al. Angiosarcoma of the liver associated with Fowler's solution (potassium arsenite). *Gastroenterology* 1975;68:1582-6.
17. Falk H, Thomas LB, Popper H, Ishak KG. Hepatic angiosarcoma associated with androgenic-anabolic steroids. *Lancet* 1979;2:1120-3.
18. Shi EC, Fischer A, Crouch R, Ham JM. Possible association of angiosarcoma with oral contraceptive agents. *Med J Aust* 1981;1:473-4.
19. Drouot F, Piard F, Thome C, et al. A case of liver angiosarcoma arising in a pre-existing cavernous hemangioma [in French]. *Ann Pathol* 1990;10:336-40.
20. Lederman SM, Martin EC, Laffey KT, Lefkowitz JH. Hepatic neurofibromatosis, malignant schwannoma, and angiosarcoma in von Recklinghausen's disease. *Gastroenterology* 1987;92:234-9.
21. Offori TW, Platt CC, Stephens M, Hopkinson GB. Angiosarcoma in congenital hereditary lymphedema (Milroy's disease). Diagnostic beacons and review of literature. *Clin Exp Dermatol*. 1993;18:174-7.
22. Martz CH. Von Hippel Lindau disease: A genetically transmitted multisystem neoplastic disorder. *Semin Oncol Nurs* 1992; 8:281-7.

Author Information

Gaurav Maheshwari, MS, MRCS(UK)

Dept. of Surgical Gastroenterology, Jagjivanram Hospital

Nairuthya Shivathirthan, MS, MRCS

Dept. of Surgical Gastroenterology, Jagjivanram Hospital

Dinesh Kamath, MS

Dept. of Surgical Gastroenterology, Jagjivanram Hospital

Premashish Halder, MS

Head of Dept., Dept. of Surgical Gastroenterology, Jagjivanram Hospital