

A Rare Entrapment Of Medial Root Of Median Nerve Between Axillary Artery And Its Anomalous Branch

P Vijaya, V Vollala, R Mohandas, S Shetty

Citation

P Vijaya, V Vollala, R Mohandas, S Shetty. *A Rare Entrapment Of Medial Root Of Median Nerve Between Axillary Artery And Its Anomalous Branch*. The Internet Journal of Neurology. 2005 Volume 5 Number 2.

Abstract

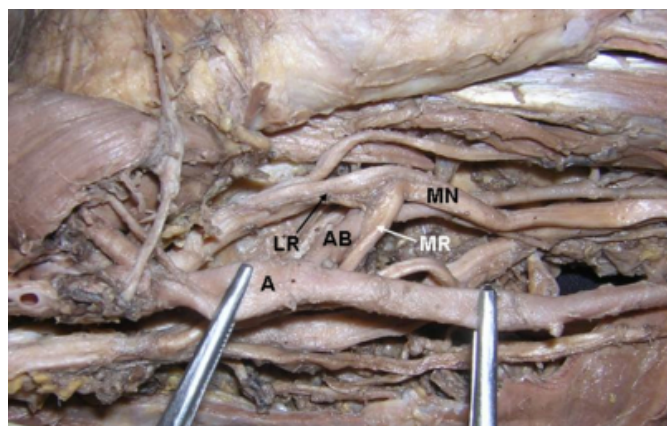
In the present paper we present a rare variation of entrapment of the medial root of median nerve. During the dissection classes in the Department of Anatomy at Melaka Manipal Medical College, a 50-year-old male cadaver showed the medial root of median nerve passing between the axillary artery and its anomalous branch. Due to this the medial root may be compressed. The clinical significance of the variation is discussed.

CASE REPORT

During the gross anatomy dissection of a 50-year-old male cadaver, we observed a rare variation of entrapment of the medial root of median nerve between the axillary artery and its anomalous branch (Figure 1).

Figure 1

Figure 1: Entrapment of medial root of median nerve between third part of axillary artery and its anomalous branch.



A – third part of axillary artery, AB – anomalous branch, MR – medial root of median nerve, LR – lateral root of median nerve, MN – median nerve.

DISCUSSION

The median nerve (C5, 6,7,8;T1) is formed in the axilla by one root from each from the medial and lateral cords of brachial plexus. It descends anterior to the axillary and upper part of brachial arteries to reach the medial aspect of the brachial artery in the distal half of the arm. It supplies most of the flexor muscles in the anterior aspects of the forearm

and the thenar and two lumbrical muscles in the hand. It also supplies skin in the hand and fingers but only sympathetic postganglionic fibers to the axillary and brachial arteries in the axilla and arm [1]. Normally the medial root derived from the medial cord, carries the fibers from C8, T1 and joins with the lateral root after crossing the front of the third part of the axillary artery. In the present case the medial root of median nerve passed posterior to the third part of the axillary artery and then between the axillary artery and the anomalous branch and united with the lateral root, due to this the medial root of median nerve may be compressed.

This variation may be clinically important because symptoms of median nerve compression arising from similar variations are often confused with more common causes such as radiculopathy and carpal tunnel syndrome.

Although high median nerve entrapments have been reported for many years, there is still a general lack of awareness on the part of many physicians compared with carpal tunnel syndrome; because it occurs much less frequently, its presentation and physical findings are not as “classic,” and electrophysiological investigations are often equivocal. In short, the diagnosis is elusive, the localization of compression is a challenge, and it is often overlooked in the differential diagnosis.

Compression of the median nerve in the arm is often caused by vascular structures because the nerve has an intimate relationship with brachial vessels. In the region of the elbow and proximal forearm, the nerve may be compressed, often in a dynamic nature, by various musculoskeletal structures.

Moreover, the presentation and diagnosis of peripheral nerve compress may be confusing because of the commonly associated anomalies of the nerve itself (e.g., Martin-Gruber anastomosis).

Knowledge of the branching patterns of the median nerve is very important to understand the various presentations of median nerve entrapment. The courses of the median nerve and its branches have common variations relevant to proximal median nerve entrapment. In the arm, the most common variation relates to the “delayed” contribution of the lateral cord. The medial and lateral cords can pass posteriorly to the axillary artery to form the median nerve, which subsequently takes a posterior course to reach the medial aspect of the brachial artery. These anomalies, however, are not as pertinent to compressive neuropathies as those at the level of the elbow and proximal forearm.

Chronic pain arising from the proximal median nerve in the arm is predominantly caused by trauma, typically direct damage caused by penetrating or crushing injuries. In this situation, the diagnosis and location of the lesion or site of entrapment are often straightforward. Nontraumatic compression is predominantly caused by slowly expanding

lesions, often vascular in nature. Arterial aneurysms, arteriovenous malformations, and expanding arteriovenous fistulas for hemodialysis are reported causes [2, 3]. The increasing use of interventional investigations, arteriograms, and vascular access often is responsible for acute or subacute proximal median nerve injury or compression.

Compression of the median nerve at the wrist is the most common nerve entrapment syndrome but may be over- or misdiagnosed. With high (proximal) median nerve entrapment being uncommon and having an elusive diagnosis, proximal compression may be overlooked as a cause of the painful upper extremity. Recognition and diagnosis of this problem will help ensure timely and effective management of the more common pain syndromes.

References

1. G J Romanes. Cunningham's Manual of Practical Anatomy. 15th edition, Volume One, Upper and lower limbs, Oxford University press, 2003; p. 70.
2. Ergungor MF, Kars HZ, Yalin R. Median neuralgia caused by brachial pseudoaneurysm. Neurosurgery 1989; 24: 924-925.
3. Reinstein L, Reid WP, Sadler JH: Peripheral nerve compression by brachial artery-basilic vein vascular access in long-term hemodialysis. Arch Phys Med Rehab 1984; 65: 142-144.

Author Information

P.S. Vijaya

Department of Anatomy, Melaka Manipal Medical College (Manipal Campus), International Centre for Health Sciences

V. R. Vollala

Department of Anatomy, Melaka Manipal Medical College (Manipal Campus), International Centre for Health Sciences

R. Mohandas

Department of Anatomy, Melaka Manipal Medical College (Manipal Campus), International Centre for Health Sciences

S. Shetty

Department of Biochemistry, Melaka Manipal Medical College (Manipal Campus), International Centre for Health Sciences