

# Adenoid cystic carcinoma of external auditory canal

M S G., M B. V., A Nair., B A.M.

## Citation

M S G., M B. V., A Nair., B A.M.. *Adenoid cystic carcinoma of external auditory canal*. The Internet Journal of Otorhinolaryngology. 2009 Volume 11 Number 2.

## Abstract

A rare case of Adenoid Cystic Carcinoma (ACC) of the External Auditory Canal (EAC) encountered in a 45 year old female is reported. The patient underwent a radical resection of the EAC, mastoidectomy and partial resection of the parotid. On histopathological examination cells were found to be arranged in a cribriform glandular pattern and focal perineural invasion was also noted. These tumors need to be diagnosed early and treated radically or the long clinical course ultimately results in death due to local invasion or distant metastasis.

## INTRODUCTION

Malignant tumors of the External Auditory Canal (EAC) are rare and most are squamous cell carcinomas.<sup>1</sup> Glandular tumors are infrequent lesions of the EAC and account to 20% of all EAC neoplasms.<sup>2</sup> Controversy still exists about nomenclature, classification, tissue of origin, and accurate diagnosis of these tumors. Adenoid Cystic Carcinoma (ACC) arising in the EAC is exceedingly rare one in 18 to one in 30 malignant EAC tumors.<sup>3,4</sup> Despite a benign histological appearance and slow growth of ACC, the natural history of this disease is characterized by a slow malignant course. Local recurrences and metastasis to the cervical lymph nodes, lungs, bones and liver can occur over many years.<sup>5</sup> Moreover, ACCs tend to invade surrounding tissue by perineural or periosteal extension. The 5 - year survival rate is high but local recurrence rate is equally high.<sup>1</sup>

We report a case of adenoid cystic carcinoma of the external auditory canal with emphasis on the features that distinguish it from benign lesions, the surgical aspects of therapy and review the medical literature existing in relationship with this pathology.

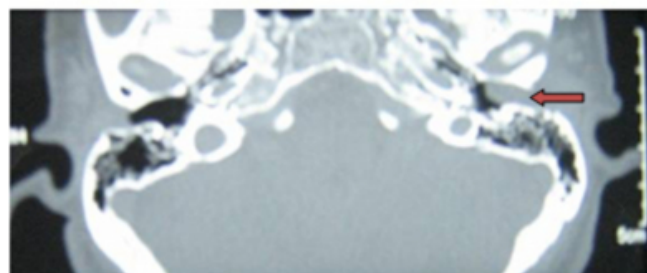
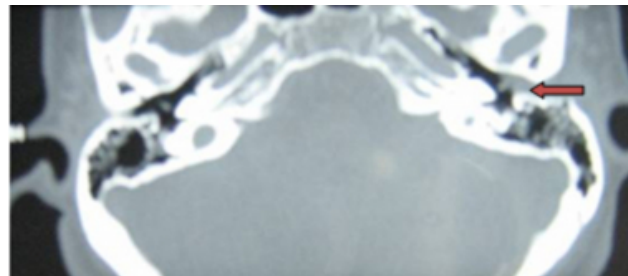
## CASE REPORT

A 45 year old female presented to Department of ENT, St. Johns Medical College Hospital a tertiary referral centre in south India in May 2007, with complaints of sharp pain in the left ear, radiating to the neck for 3 months. She had decreased hearing on the same side and left ear discharge since childhood. On examination, a smooth pink swelling was seen in the left external auditory canal, which blocked the canal lumen completely. The swelling was seen to arise

from the posterior canal wall. Biopsy of the swelling was performed. Histopathological examination was suggestive of adenoid cystic carcinoma. Computed Tomography scan of temporal bone were done (Fig1.)

## Figure 1

Figure 1: Axial Computed Tomography scans showing the lesion in the left EAC.

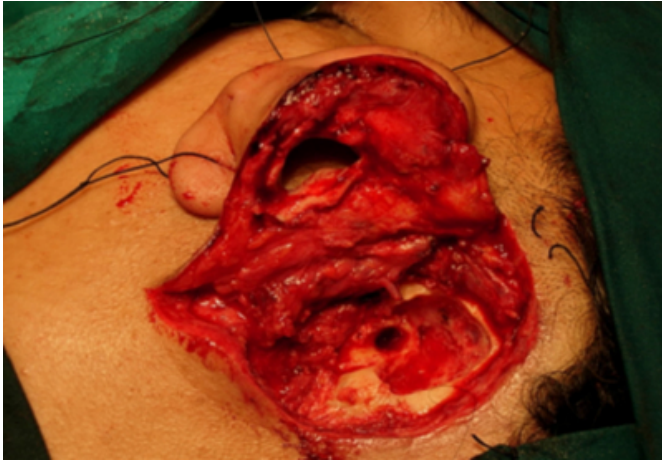


The tumor was classified as a stage 1 (T1N0) lesion based on University of Pittsburgh TNM staging for EAC carcinoma.<sup>6</sup> The patient underwent left lateral temporal bone resection. An en-block excision of the bony and cartilaginous canal was carried out. Initially an intact bridge mastoidectomy was done and facial nerve exposed. Facial

recess opening was extended inferiorly to hypotympanum till the level of stylomastoid foramen. Mastoidectomy was extended superiorly to the root of zygoma. ( Fig 2)

**Figure 2**

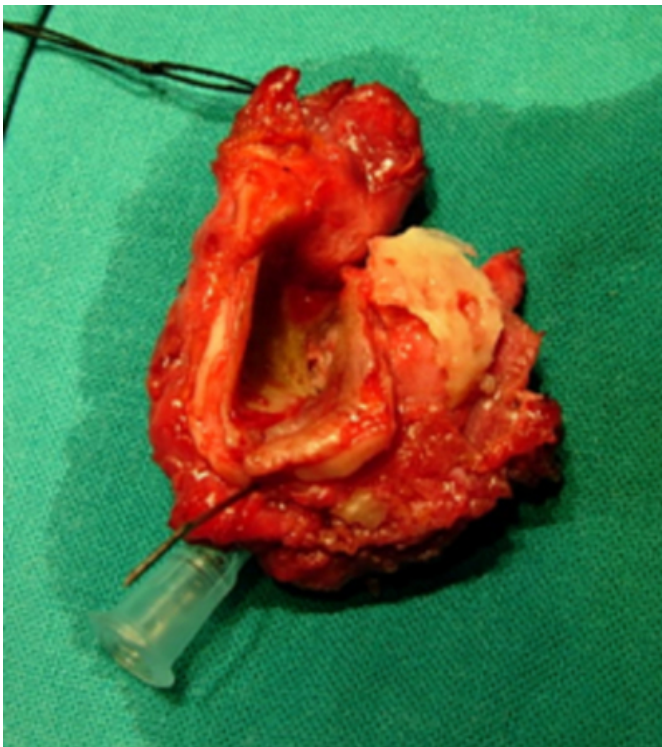
Figure 2 : Sub temporal resection



Posterior canal wall was penetrated just lateral to the facial ridge. Specimen consisting of the osseous and cartilaginous canal wall, lateral to tympanic membrane, along with a cuff of parotid tissue was removed intoto. (Fig 3 ).

**Figure 3**

Figure 3: Resected specimen

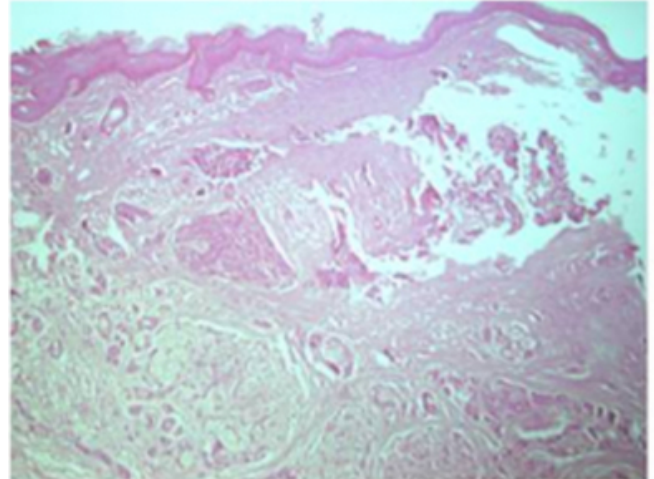


On histopathological examination cells were found to be arranged in a cribriform glandular pattern and focal

perineural invasion was also noted. No sign of recurrence has been observed with a follow up of 2 years. (Fig 4)

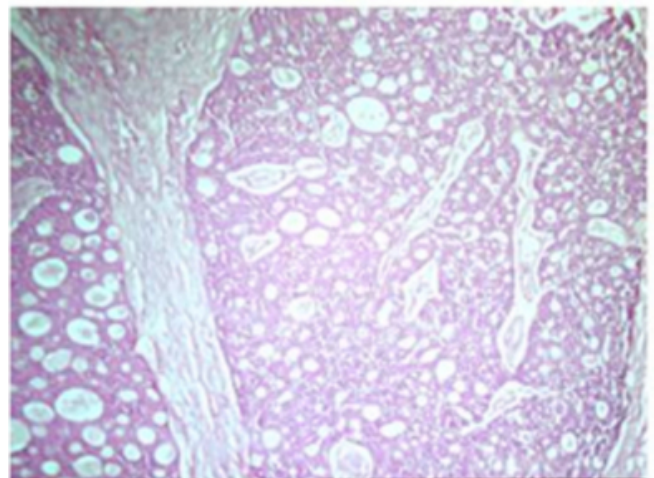
**Figure 4**

Figure 4: A, Skin with underlying infiltrative neoplasm, H&E x40



**Figure 5**

Figure 4: B, Neoplastic cells in cribriform pattern, H&E x 200



## DISCUSSION

Adenoid Cystic Carcinomas (ACC) may involve the External Auditory Canal (EAC). Glandular tumors of the EAC are rare but ACC is the most common type of these rare glandular tumors. ACC appears to arise from the ceruminous glands, sweat glands or ectopic salivary gland tissue.<sup>7</sup> In some cases, the tumor may have arisen in the adjacent parotid salivary gland and secondarily may have extended into the ear canal<sup>8</sup>. ACC originating from the EAC appear to be more aggressive

Adenoid cystic carcinoma of the external auditory canal is usually seen in the 40-50 year age group. A characteristic feature of this neoplasm; is the presence of a sharp pain radiating away from the ear and an EAC lesion. The EAC lesion may present as a polyp, ulceration, and granulation or simply as a sub epithelial swelling. It may not be possible to clearly demarcate the borders of the swelling. Other symptoms include facial paresis, tinnitus and hearing loss. It is important to assess the nasopharynx to rule out tumor arising from that area and then spreading to EAC. The tumor may sometimes spread to the EAC from the parotid.<sup>1</sup>

High resolution Computed Tomography (HRCT) of the temporal bone is the imaging of choice. Evidence of irregular bone erosion or destruction of the canal wall is indicative of malignancy. ACC may locally invade soft tissue and bone, extend into the parotid gland and temporomandibular joint and metastasize to the regional lymph nodes, lung and liver. So lungs and regional lymph nodes must also be evaluated with CT for metastasis.

A tumor of stage 1 requires a lateral temporal bone resection. Other stages require subtotal to total temporal bone resection. Stage 3 & stage 4 tumors also require post operative radiotherapy. Adjuvant radiotherapy may also be given in cases of incomplete excision or in the presence of inadequate margins. Radiotherapy and chemotherapy are not curative but can help in palliation and as adjuvant therapy. ACC has a propensity for recurrence, so patients treated need to be followed up for a long time. The presence of tumor along the margins of resection, perineural spread, involvement of parotid or the involvement of bone increases the chance for recurrence.

Histologically three main patterns of ACC have been described: tubular, cribriform and solid.<sup>7</sup> In the EAC significant correlation between histological patterns and prognosis has not been demonstrated because of the small number of cases.<sup>1</sup> However in salivary glands prognosis of ACC correlates with the histological pattern.<sup>7,9</sup> Predominantly tubular ACCs have the best prognosis, whereas the predominantly solid ACCs have the worst

prognosis. These neoplasms are characterized by the presence of nerve sheath and lymphatic invasion. There is also perineural or periosteal extension. Histological differential diagnosis of ACC should include basal cell carcinoma, ceruminous gland adenocarcinoma and ceruminous gland adenoma. And it may be difficult to differentiate from an adenoma or a benign mixed tumor arising in ceruminous glands from small sample biopsies<sup>10</sup>

### CONCLUSION

ACC of the EAC is a rare malignant tumor. This tumor has an aggressive behavior characterized by local invasiveness and a metastatic risk of approximately 30%. We would therefore like to emphasize the need for early detection of adenoid cystic carcinoma of the external auditory meatus; its differentiation from other benign conditions; the necessity of radical surgery and the need for long term follow up.

### References

1. Perzin K H, Gullane P, Conley J. Adenoid cystic carcinoma involving the external auditory canal. *Cancer* 1982;50:2873-83.
2. Conley J , Schuller DE. Malignancies of the ear 1976;86:1147-63.
3. Shih L, Crabtree JA. Carcinoma of the external auditory canal: An update. *Laryngoscope* 1990;100:1215-18.
4. Kinney SE, Wood BG. Malignancies of the ear canal and temporal bone: Surgical techniques and results. *Laryngoscope* 1987;97:158-64.
5. Spiro RH, Koss LG, Hajdu SI. Tumours of minor salivary gland origin: a clinicopathologic study of 492 cases *Cancer* 1973;31:117-29.
6. Micheal M, Herman J. Temporal bone neoplasms and lateral cranial surgery .In: Cummings CW. *Otolaryngology Head & Neck Sugery* .4th ed. Pennsylvania: Elsevier Mosby; 2005.p. 3719.
7. Fliss DM, Kraus M, Tovi F. Adenoid cystic carcinoma of the external auditory canal. *Ear Nose Throat J* 1990;69:635-45.
8. Szanto PA, Luna MA, Tortoledo ME. Histologic grading of adenoid cystic carcinoma of the salivary gland. *Cancer* 1984;54:1062-9.
9. Perzin K H, Gullane P, Clairmont AG. Adenoid cystic carcinomas arising in salivary glands. *Cancer* 1978;42:265-82.
10. Pulec JL, Parkhill EM, Devine KD . Adenoid cystic carcinoma of external auditory canal .*Trans Am Acad Ophthalmol Otolaryngol* 1963;67:673-694.
11. Wetli CV , Pardo V, Millard M, Gertson K. Tumours of ceruminous glands. *Cancer* 1972;29:1169-1178.

**Author Information**

**Maneesh S G., DLO**

Senior Resident, Department of Otolaryngology and Head and Neck Surgery, St. Johns Medical College and Hospital

**Manjula. B. V., DLO, DNB**

Department of Otolaryngology and Head and Neck Surgery, St. Johns Medical College and Hospital

**Arun B Nair., DLO**

Registrar, Department of Otolaryngology and Head and Neck Surgery, St. Johns Medical College and Hospital

**Balasubramanya. A.M., MS**

Professor, Department of Otolaryngology and Head and Neck Surgery, St. Johns Medical College and Hospital