

Primary Effusion Lymphoma In A Non-HIV Patient: A Case Report And Discussion Of Treatment Modalities

J Heidecker, C Strange

Citation

J Heidecker, C Strange. *Primary Effusion Lymphoma In A Non-HIV Patient: A Case Report And Discussion Of Treatment Modalities*. The Internet Journal of Pulmonary Medicine. 2004 Volume 4 Number 2.

Abstract

Pleural effusion is a rare initial presentation of lymphoma. There is a subset of lymphoma based in serosal surfaces that is almost universally associated with advanced HIV infection. We describe a case of primary pleural SCLL that proved refractory to pleuridesis. With initiation of chemotherapy, his effusions have decreased in size and his dyspnea has abated. There are subsets of B-cell lymphoma known as primary pleural lymphomas (PPL) that manifest as an isolated pleural effusion(s). There are distinct subtypes with different phenotypes and clinical courses. Prognosis in HIV associated PEL is grim. The patients with non-HIV associated PPL achieve remission of their disease with chemotherapy. Because patients with breast cancer and lymphoma can have prolonged survival, the role of the indwelling catheter (Pleurx) is not well established in patients with these malignancies. Other cases of PEL reported in the literature have shown good survival and response rates to systemic chemotherapy.

INTRODUCTION

Pleural effusions from chronic lymphocytic leukemia/small cell lymphocytic lymphoma (CLL/SCLL) occur from mediastinal obstruction, chylothorax, or from lymphomatous cells in the pleural space. Effusions secondary to lymphoma are usually lymphocytic exudates in nature and can be unilateral or bilateral; however, there is almost always accompanying adenopathy. Rarely, lymphoma occurs in the pleural space as a presenting manifestation. There is a subset of lymphoma based in serosal surfaces originally described by Knowles in 1989 that is almost universally associated with advanced HIV infection^[1]. We describe a case of SCLL that presented as bilateral pleural effusions and proved refractory to pleuridesis.

CASE REPORT

The patient is a 63 year-old with type II diabetes with a two week history of dyspnea on exertion. His past surgical history was significant for coronary artery bypass surgery two years previously without any chest pain or congestive heart failure since his surgery. Physical examination revealed decreased bilateral breath sounds that corresponded to large bilateral effusions on chest radiograph (figure 1.) Serum white blood cell count was 8400 cells/mL; 69% were neutrophils, 15% lymphocytes, 12% macrophages, and 2.7% eosinophils. Hemoglobin was 14 mg/dL, platelets were

269000/mL. Antinuclear antibody, anti-neutrophil cytoplasmic antibody, purified protein derivative (PPD), and rheumatoid factor were negative. Echocardiogram revealed normal systolic and diastolic function. Chest computed tomography (CT) scan showed bilateral pleural thickening without mediastinal adenopathy. Thoracentesis was performed on both effusions (table 1.). Flow cytometry revealed 86% lymphocytes with a 10% clonal population of B cells that expressed CD 5, CD19, CD 20, CD 22, CD 23, CD 45, HLA-DR, and dim FMC-7. These cells did not express CD 10, CD 34, or CD 38. There was light intensity kappa light chain rearrangement. This population of cells was consistent with a low- grade chronic lymphocytic leukemia/ small-cell lymphocytic lymphoma (CLL/SLL). Bone marrow biopsy revealed normal cell line maturation. There were 15% lymphocytes. 7% were B-lymphocytes and 6% were T-lymphocytes. There was also an abnormal B-cell clonal population with identical markers to the abnormal pleural fluid cells. HIV was negative.

After drainage of his pleural spaces, patient felt improvement in his dyspnea; however, both sides re-accumulated. Because his symptoms were limited to his pleural effusions, pleuridesis was attempted. Talc slurry was inserted through a large bore chest tube into the right pleural space and the chest tube was pulled three days later. However, pleuridesis failed and his pleural effusions re-

accumulated. Therefore, a permanent, tunneled, indwelling catheter (Pleurex) was placed in the left pleural space and provided symptomatic relief. The patient had an initial drainage of 100 mL on day one that rapidly decreased to 50 mL/day by day 12 (Figure 1) However, he continued to have persistent daily drainage and dyspnea on exertion. Further, a CT scan was done one month after catheter placement that showed persistence of his effusions. Because of persistent drainage, the patient was started on 25 mg/m2 of fludarabine for five days each month. With initiation of chemotherapy, his effusions have decreased in size and his dyspnea has abated.

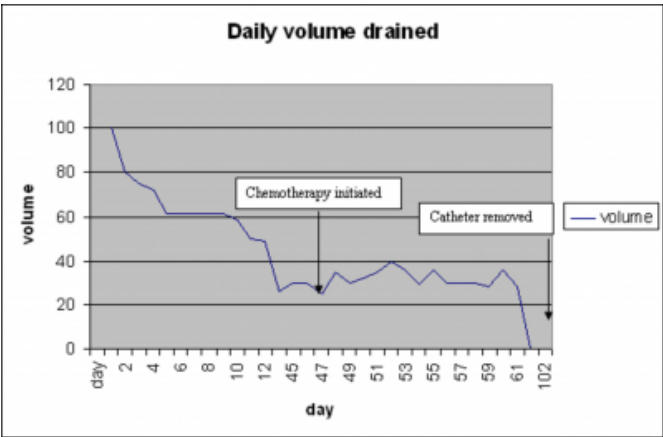
Figure 1

Table 1: Thoracentesis data

	Left effusion	Right effusion
RBC count	213000/mL	300000/mL
WBC count	900/mL	400/mL
Neutrophil%	10	5
Lymphocyte%	68	87
PH	7.3	7.3
Protein	4.2g/dL	3.8g/dL
LDH	341 IU/mL	289 IU/mL
Triglycerides		36 IU/mL
Cultures	negative	negative
ANA, RF		negative
Cytology	small lymphocytes	small lymphocytes
Flow cytometry	abnormal population B cells expressing CD 5,19,20,22, 23,45,HLA-DR, dim FMC-7 with clonal kappa light chain rearrangement in 10% of lymphocytes	same as left

Figure 2

Figure 1: Daily volume drained



*Data not available from days 12-44 or 61-88

DISCUSSION

Pleural involvement is rare in CLL[2]. CLL's counterpart, small cell lymphocytic lymphoma (SLL) commonly presents either symptomatic or asymptomatic pleural effusions.

However, these are usually associated with bulky mediastinal adenopathy. In these cases, pleural effusion is due to one of three mechanisms. It can be due to direct pleural involvement, diffuse blockage of pulmonary parenchymal or pleural lymphatics, or compression of the thoracic duct. Compression of the thoracic duct presents as chylothorax. There have been case reports of SLL with pleural effusions in the absence of any identifiable adenopathy [3]

There are subsets of B-cell lymphoma that present with isolated pleural effusion(s). They are known as primary pleural lymphomas (PPL). The four specific types of PPL are shown in table 2. The subtypes known as body cavity based lymphoma or primary effusion lymphoma (PEL) manifest as pleural or pericardial effusions or ascites and are most often seen in advanced AIDS patients. PEL is associated with Human Herpes virus 8, the cause of Kaposi's Sarcoma[4],[5]. PEL has been shown to involve mutations of the variable heavy chain regions of immune globulins. It has also been shown to have variable CD expression and maturation, although CD 19 and CD 20 are usually negative[6]. Further, all but of the known reported PEL cases were B-cell lymphomas.

Primary pleural lymphoma has two distinct subtypes in non-HIV infected patients (table 2).

Figure 3

Table 2: Classifications of Primary Pleural Lymphoma

HIV positive	HIV negative
PEL a/w HHV-8 (B-cell phenotype)	Secondary to long-standing pyothorax a/w EBV
PEL with HHV-8 (T-cell phenotype- only 2 cases)	Non- HIV PEL
	-HHV-8 related
	-non-HHV-8 related

The first subtype occurs in patients with longstanding pleural inflammation (mainly patients with chronic pleural tuberculosis.) In these patients, there has been an association with EBV [7]. The other subgroup of non-HIV patients with PPL is comprised of limited numbers of case reports in the literature. These patients are usually elderly and HHV-8 has been implicated [8]. Our patient was CD19 and CD20 positive like other cases of non-HIV, HHV-8 associated PEL. In contrast, the patients with HIV associated PEL are usually CD 19 and 20 negative. Patients with non-HIV associated PEL both in the pathogenesis as well as the outcomes. Prognosis in HIV associated PEL is grim. The patients with non-HIV associated PEL achieved remission of

their disease with chemotherapy [7].

We believe our patient has non-HIV related PEL because the effusions were the presenting symptom and the clonal population in the marrow was small. Although the initiation site of the malignancy may have been from the marrow, the lack of adenopathy, presence of pleural thickening, and lack of other organ manifestations make a pleural origin likely.

Our patient received right-sided pleurodesis, left sided permanent, tunneled, indwelling catheter (Pleurx®) and systemic chemotherapy as treatment. His pleurodesis occurred before his diagnosis was secure and failed. In Hodgkin's and non-Hodgkin's lymphoma complete and partial response to pleurodesis has been reported at 30 and 50% respectively [9]. Limited information is available about pleurodesis success in PEL although failure may be common since these effusions commonly have large amounts of drainage making pleural apposition difficult.

Given that pleural effusion in malignancy generally portends a mean survival of less than six months, care is often palliative. In CLL/SLL, survival is often prolonged, making control of pleural fluid more important. The Pleurx tunneled, indwelling pleural catheter has proven invaluable in alleviating dyspnea, decreasing length of hospitalization, and empowering patients with malignant effusions. Further, 50% malignancy patients with these catheters achieve spontaneous pleurodesis,[10] although few patients with pleural lymphoma were included in licensing studies.

The main complications from indwelling tunneled pleural catheter are cellulitis, obstruction, and tumor seeding all related to dwell time of the catheter. Therefore, if they do not achieve spontaneous pleuridesis, they are at increased risk for complications from the catheter. Thus, the role of the indwelling catheter is not well established in patients with breast cancer and lymphoma. Though our patient had relief in dyspnea with his Pleurx catheter, he did not have complete resolution of his symptoms until systemic chemotherapy was begun (see graph 1.) Other cases of PEL reported in the literature have shown good survival and response rates to systemic chemotherapy[11].

CONCLUSIONS

Primary pleural lymphoma should be considered in the

differential diagnosis of all patients with lymphocytic pleural effusions without adenopathy. Further, in non-HIV primary pleural lymphoma, remission rates are excellent. Therefore, treatment should not be viewed as palliative as in other malignant effusions. The primary treatment modality of primary pleural lymphoma in both HIV and non-HIV patients is systemic chemotherapy. Pleuridesis should be reserved for patients with persistent effusion despite use of chemotherapy and the pleurx catheter as it has a high failure rate.

References

1. Knowles, D.e.a., Molecular genetic analysis of three AIDS-associated neoplasms of uncertain lineage demonstrates their B-cell derivation and the possible pathogenetic role of Epstein-Barr virus. *Blood*, 1989. 73: p. 792-799.
2. van de Berge, M.e.a., A 73 year-old man with chronic lymphocytic leukaemia and haemorrhagic pleural effusion. *Annals of Hematology*, 2001. 80(3): p. 183-6.
3. Iwahashi, M.e.a., Primary effusion lymphoma with B-cell phenotype. *American Journal of Hematology*, 2000. 64(4): p. 317-318.
4. Cesarman, E., et al., Kaposi's Sarcoma-Associated Herpesvirus-Like DNA Sequences in AIDS-Related Body-Cavity-Based Lymphomas. *N Engl J Med*, 1995. 332(18): p. 1186-1191.
5. Arvanitakis, E.e.a., Establishment and Characterization of a Primary Effusion (Body Cavity-Based) Lymphoma Cell Line (BC-3) Harboring Kaposi's Sarcoma-Associated Herpesvirus (KSHV/HHV-8) in the Absence of Epstein-Barr Virus. *Blood*, 1996. 88(7): p. 2648-2654.
6. Matolcsy, A., et al., Immunoglobulin VH Gene Mutational Analysis Suggests that Primary Effusion Lymphomas Derive from Different Stages of B Cell Maturation. *Am J Pathol*, 1998. 153(5): p. 1609-1614.
7. Martin, A., Epstein-Barr virus-associated primary malignant lymphomas of the pleural cavity occurring in longstanding pleural chronic inflammation. *Human Pathology*, 1994. 25(12): p. 14-18.
8. Perez, C.e.a., Anti-CD20 monoclonal antibody treatment of human herpesvirus 8-associated, body cavity-based lymphoma with an unusual phenotype in a human immunodeficiency virus-negative patient. *Clinical & Diagnostic Laboratory Immunology*, 2001. 8(5): p. 993-6.
9. Alifano, M., Management of concurrent pleural effusion in patients with lymphoma: thoracoscopy a useful tool in diagnosis and treatment. *Monaldi Archives of Chest Disease*, 1997. 52(4): p. 330-334.
10. Putnam, J.B.e.a., A Randomized Comparison of Indwelling Pleural Catheter and Doxycycline Pleuridesis in the Management of Malignant Pleural Effusions. *Cancer*, 1999. 86(10): p. 1992-1999.
11. Ariad, S.e.a., Early peripheral lymph node involvement of human herpesvirus 8-associated, body cavity-based lymphoma in a human immunodeficiency virus-negative patient. *Archives of Pathology and Laboratory Medicine*, 2000. 124: p. 753-755.

Author Information

Jay T. Heidecker, M.D.

Department of Pulmonary and Critical Care Medicine, Medical University of South Carolina

Charlie Strange, M.D.

Department of Pulmonary and Critical Care Medicine, Medical University of South Carolina