

# Dispersion of Optic Disc Melanocytoma Following Argon Laser Photocoagulation.

H Fesharaki, M Masjedi, G Naderian, A Salehi

## Citation

H Fesharaki, M Masjedi, G Naderian, A Salehi. *Dispersion of Optic Disc Melanocytoma Following Argon Laser Photocoagulation..* The Internet Journal of Ophthalmology and Visual Science. 2009 Volume 8 Number 2.

## Abstract

**Purpose:** To report a case of optic disc melanocytoma (ODM) with a long term follow up after being treated by argon laser.

**Materials and Methods:** This case describes a 63 year old white Iranian woman with optic disc melanocytoma in her right which was first detected during a routine eye examination at 1989, the eyes were otherwise normal. The size and the shape of the tumor were static until 1992 when argon green laser was applied over the lesion.

**Results:** Tumor dispersion, vitreous seeding, changes in the tumor configuration, and apparent tumor enlargement was observed at the first post laser visit that happened three weeks after laser photocoagulation. Alterations in the tumor configuration were continued during the following year. From 1993 to 2010 the tumor remained static in shape but gradually lost some of its black hue color.

**Conclusion:** Tumor dispersion, vitreous seeding, and tumor enlargement were the main observed complications of argon laser photocoagulation in this case of ODM.

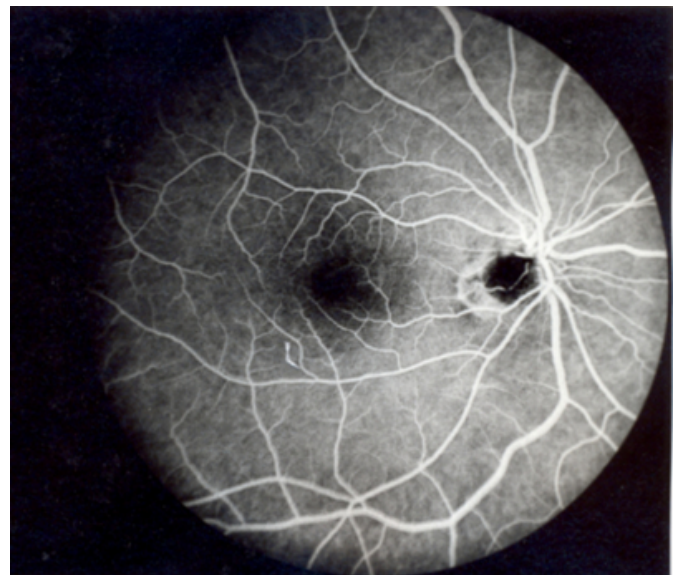
## INTRODUCTION

Laser photocoagulation treatment was found a useful option in the treatment of small choroidal melanomas.<sup>(1)</sup> Laser photocoagulation has not been considered for the treatment of optic disc melanocytoma (ODM), and there is no previous report about the effect of laser photocoagulation on this tumor. This case is a woman who mistakenly received argon laser photocoagulation for the treatment of her ODM and was followed for 17 years after laser application.

**Materials and Methods:** A 63 year old white Iranian woman was found to have ODM in her right eye. This lesion was first detected during a routine eye examination at 1989 (figure 1).

## Figure 1

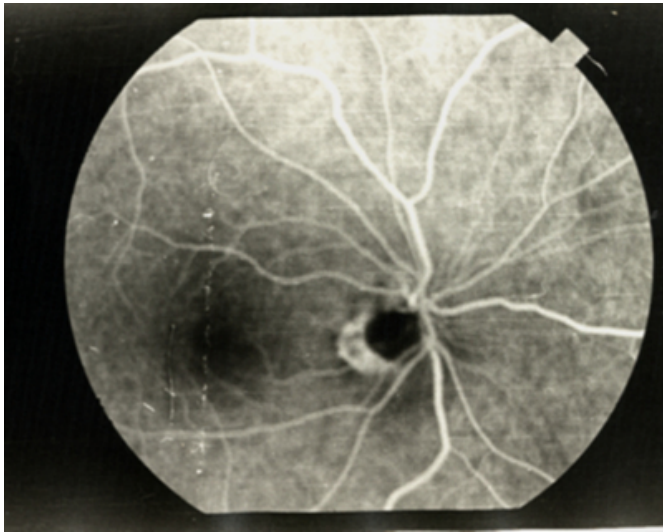
Figure 1: Fundus picture of the right eye of the 63 year old woman with optic disc melanocytoma at 1989.



Visual acuity was 20/20 OU, ocular and systemic examinations were otherwise normal. On follow up fundus examinations, the size and the shape of the lesion and the visual acuity were static till 1992 (figure 2).

**Figure 2**

Figure 2: Fundus picture of the right eye of the 63 year old woman with optic disc melanocytoma before argon laser photocoagulation at 1992



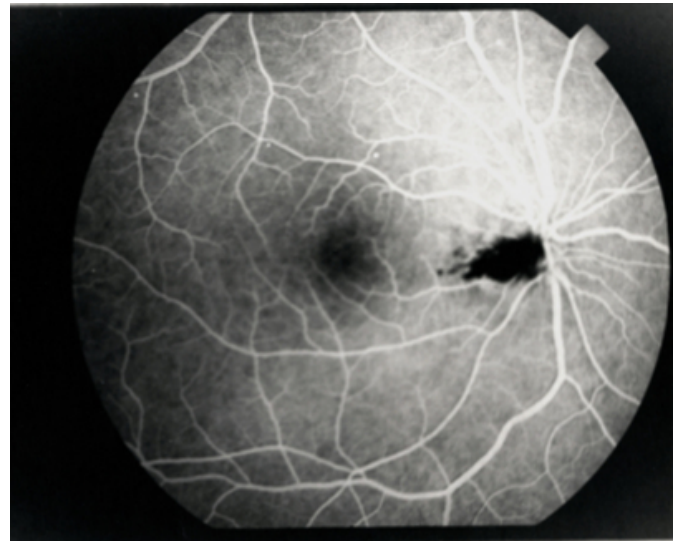
The patient received one session of argon green laser photocoagulation for the treatment of her ODM in another center at 1992.

## **RESULTS**

The first post laser eye examination happened three weeks following laser application. The patient referred to the first author complaining of floaters and reduced visual acuity in her right eye being developed following laser treatment, visual acuity was 20/30 OD, which could be improved by head tilt and head turn, there was no relative afferent papillary defect (RAPD). Fundus examination showed tumor dispersion, vitreous seeding, and change of the tumor configuration from a round sharp bordered lesion into an oval irregular bordered lesion (Figure 3). The black particles overlying the tumor around the posterior pole were assumed to be the seeded tumor cells.

**Figure 3**

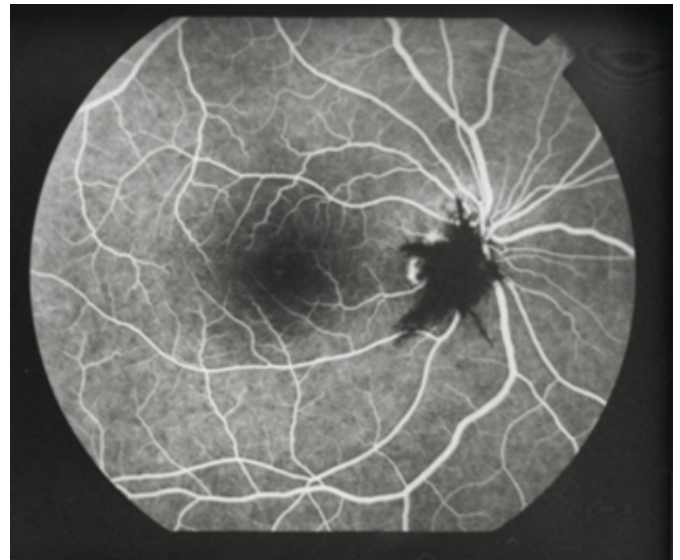Figure 3: Fundus picture of the right eye of the 63 year old woman with optic disc melanocytoma 3 weeks after argon laser photocoagulation at 1992



During the first year following laser application, continuous change in the tumor shape was accompanied by its apparent enlargement. Figure 4 shows the tumor with a star like configuration and feathery border at 1993.

**Figure 4**

Figure 4: Fundus picture of the right eye of the 63 year old woman with optic disc melanocytoma after argon laser photocoagulation at 1993

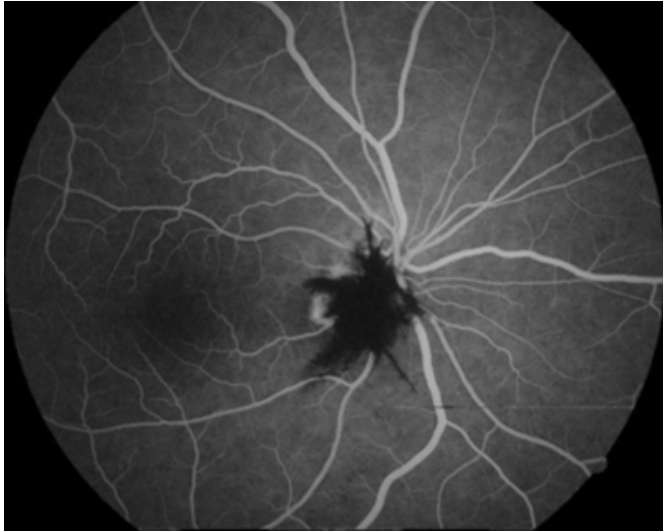

From 1993 to 2010 the tumor remained static with no remarkable change in shape and size. At the final eye examination at 2010 the tumor configuration was the same as it's configuration at 1993 (Figure 5), the tumor color was turned from dark black to gray black, and the intravitreally

seeded tumor particles were almost resolved. The corrected visual acuity was 20/25 OD, 20/20 OS, refraction was +2.50 OU, and RAPD was negative.

### **Figure 5**

Figure 5: Fundus picture of the right eye of the 63 year old woman with optic disc melanocytoma after argon laser photocoagulation at 2010.



### **DISCUSSION**

The effect of argon laser photocoagulation on ODM was not known before. In this case tumor dispersion and vitreous seeding developed early after application of argon laser over an already static ODM. Change in the tumor configuration accompanied by its apparent enlargement continued during the first year following laser application. The tumor remained silent then after for 17 years. Therefore all of the tumor alterations could be attributed to the laser intervention. It is not clear whether the apparent enlargement of the tumor was due to a transient tumor proliferation or in fact dispersion of the tumor particles around the perimeter of

the melanocytoma had mimicked the enlargement of the tumor.

Spontaneous vitreous seeding was not found to be a common finding in ODM. In a review study by Shields JA et al, spontaneous vitreous seeding was found in 4% of cases.<sup>(2)</sup>

Spontaneous rapid enlargement of ODM was found to be less common. In a follow up study by Shields JA et al, 115 patients with melanocytoma of the disc were followed for 10 years; minor tumor enlargement occurred in 11% of the patients by 5 years, and in 32% of the patients by 10 years.<sup>(3)</sup> In a study by Joffe L et al, follow-up examination of 1-19 years was obtained in 27 patients with ODM, of the 27 lesions, four of them (15%) showed a slight increase in size, one tumor (4%) showed decrease in size, and the remaining 22 tumors (81%) showed no ophthalmoscopic changes during the follow up.<sup>(4)</sup>

According to this follow up case study, tumor dispersion, vitreous seeding, and tumor enlargement were the main observed complications of argon laser photocoagulation of ODM.

### **References**

1. Qiang, Z. and Cairns, J. D. Laser photocoagulation treatment of choroidal melanoma. Australian and New Zealand Journal of Ophthalmology. May 1993, Volume 21, Issue 2, pages 87-92,
2. Shields JA, Demirci H, Mashayekhi A, Eagle RC Jr, Shields CL. Melanocytoma of the optic disc: a review. Surv Ophthalmol. 2006 Mar-Apr; 51(2):93-104.
3. Shields JA, Demirci H, Mashayekhi A, Shields CL. Melanocytoma of optic disc in 115 cases: the 2004 Samuel Johnson Memorial Lecture, part 1. Ophthalmology. 2004 Sep;111(9):1739-46.
4. Joffe L, Shields JA, Osher RH, Gass JD. Clinical and follow-up studies of melanocytomas of the optic disc. Ophthalmology 1979; 86: 1067-83.

**Author Information**

**Hamid Fesharaki, MD**

Associate professor, Eye Research Center Isfahan University Of Medical Sciences

**Marjan Masjedi, MD**

Ophthalmologist, Eye Research Center Isfahan University Of Medical Sciences

**Gholamali Naderian, MD**

Assistant professor, Eye Research Center Isfahan University Of Medical Sciences

**Ali Salehi, MD**

Assistant professor, Eye Department Shahrekord University Of Medical Sciences