

An Avulsion Fracture Of The Tibial Tuberosity With Fracture Of The Tibia In A Hockey Player

R Singh, A Sharma

Citation

R Singh, A Sharma. *An Avulsion Fracture Of The Tibial Tuberosity With Fracture Of The Tibia In A Hockey Player*. The Internet Journal of Orthopedic Surgery. 2004 Volume 2 Number 2.

Abstract

This report describes an avulsion fracture of tibial tuberosity along with tibial fracture in a 32-year-old sports person. The possible mechanism of tibial tuberosity fracture is violent quadriceps femoris contraction subsequent to painful stimulus, while knee was flexing. Direct impact on the shin led to tibial fracture. This rare injury has not been reported in literature

INTRODUCTION

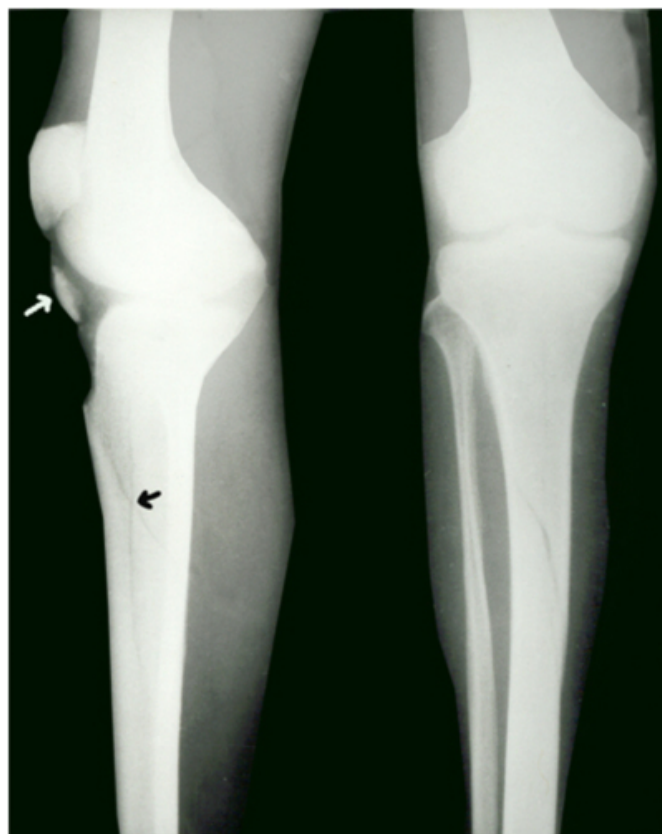
Avulsion of the tibial tuberosity is not an uncommon entity seen in adolescents. In adolescents, this fracture has been reported in isolation and in association with extraarticular and intraarticular injuries of the knee joint [2,3,4,5]. The injury is a very rare event in adults, with only a few cases reported in literature [1,6]. We report a case of avulsion of tibial tuberosity with fracture tibia in a hockey player.

CASE REPORT

During a hockey game, a 32-year-old player was struck with a hockey stick on his right shin when he was running with ball in his possession. Subsequent to the injury, he could not straighten his knee and bear weight on that limb. He had immediate, severe pain and swelling in the right upper leg and knee. When patient reported to Accident and Emergency Department, he had haemarthrosis of the knee and ecchymosis of the upper leg. He was stable haemodynamically and no neurovascular deficit was present. Roentgenograms showed fracture of tibial tuberosity with fracture proximal tibia (Fig 1). Fracture of the tibial tuberosity was displaced, while fracture of tibia showing no displacement.

Figure 1

Figure 1: Anteroposterior and lateral Xrays of the right knee, showing undisplaced fracture of tibia (black arrow) and displaced fracture of tibial tuberosity (white arrow). Patella is superiorly migrated.

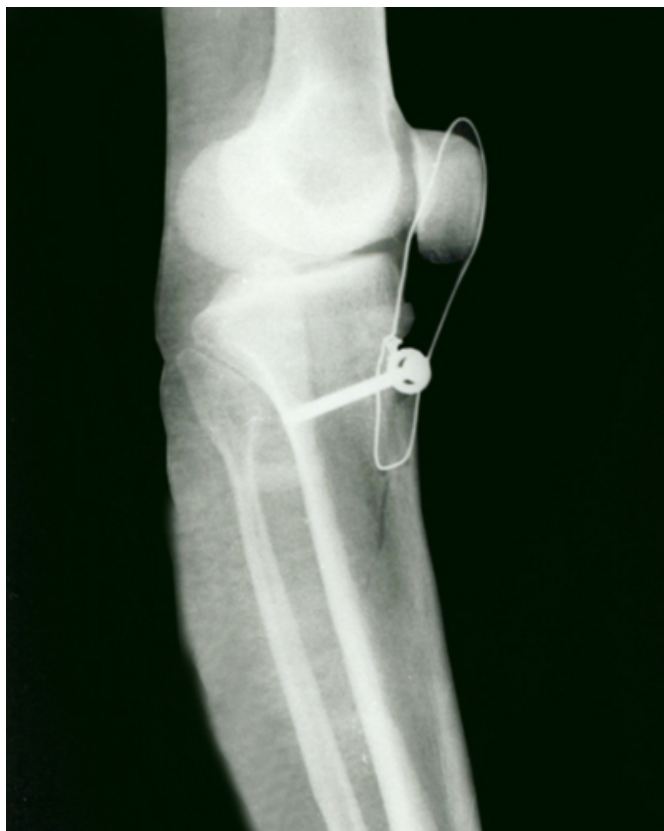

Open reduction and internal fixation was planned. Examination under anaesthesia showed no signs of instability of the knee. A standard midline incision was used to expose patella and tibial tuberosity. Avulsed fragment of

tibial tuberosity was fixed with 4.5-mm cortical screw with a washer. The fixation was supplemented with a neutralization wire (Fig.2). The leg was protected in plaster of Paris back slab for initial two weeks. After suture removal, plaster of Paris cast was given for another four weeks, before starting active knee exercises under physiotherapist supervision. Hinged-knee brace was used another six weeks. At twelve weeks, neutralization wire and screw were removed. Examination under anaesthesia at the time of removal of implants also showed no signs of instability of the knee. At the end of nine months, patient was able to resume the game.

Figure 2

Figure 2: Postoperative lateral Xray shows fixation of the tibial tuberosity with screw and neutralization wire.



DISCUSSION

Few case reports of avulsion fractures of tibial tuberosity have been described in adults [1, 6]. In adolescents, this fracture has been reported in association of other injuries like, lateral plateau rim fracture, medial meniscus tear, opposite tibial tuberosity avulsion [2,3,4,5]. Though bifocal avulsion of the patellar tendon has been reported in nonagenarian diabetic female, this injury is quite uncommon in healthy adults. [1]. our patient suffered this fracture in a peculiar fashion. He was hit by the hockey stick on his right shin while the knee was semi flexed. Painful stimulus on the leg led to violent contraction of the quadriceps muscle avulsing the tibial tuberosity while the knee was further flexing. Since the site of impact was on leg, this led to fracture of the tibia simultaneously. To the best of our knowledge, such type of injury to the extensor mechanism of the knee joint has never been reported in a sports person. This case is presented to highlight the rarity of this injury in an adult sports person.

CORRESPONDENCE TO

Dr. Roop Singh 8J/3, Medical Enclave PGIMS,
Rohtak-124001 (Haryana), India Ph: 91-2-213171 E-mail :
drroopsingh@rediffmail.com

References

1. Chautems R, Michel J, Barraud GE, Burdet A .Bifocal avulsion of the patellar tendon in an adult. Rev Chir Orthop Reparatrice Appar Mot 2001; 87(4): 388-91.
2. Choi NH, Kim NM. Tibial tuberosity avulsion fracture combined with meniscal tear. Arthroscopy 1999 ;15(7):766-9.
3. Legaye J, Lokietek W. Fracture-avulsion of the tibial tuberosity in adolescents. Acta Orthop Belg 1991;57(2): 199-203.
4. Lapse PS, McCarthy RE, McCullough FL. Simultaneous bilateral avulsion fracture of the tibial tuberosity. A case report. Clin Orthop 1988; 288:232-235.
5. Ozer H, Turanli S, Baltaci G, Tekdemir I. Avulsion of the tibial tuberosity with a lateral plateau rim fracture: case report. Knee Surg Sports Traumatol Arthrosc 2002;10(5): 310-2
6. Vella D, Peretti G, Fra F. One case of fracture of the tibial tuberosity in adult. Chir Organi Mov1992; 77(2): 299-301.

Author Information

Roop Singh, M.S.

Lecturer, Department of Orthopaedics, Paraplegia and Rehabilitation, Pt BDS PGIMS

Ashwini Sharma, M.S.

Senior Resident, Department of Orthopaedics, Paraplegia and Rehabilitation, Pt BDS PGIMS