

An Anesthesiologists Focus On Sedation And Complications Of GI Endoscopy Cases- A Case Of Bilateral Pneumothoraces And Pneumomediastinum After Routine ERCP

U Galway

Citation

U Galway. *An Anesthesiologists Focus On Sedation And Complications Of GI Endoscopy Cases- A Case Of Bilateral Pneumothoraces And Pneumomediastinum After Routine ERCP*. The Internet Journal of Anesthesiology. 2009 Volume 23 Number 2.

Abstract

Introduction

Anesthesiologists are now more commonly seen in the GI suite administering sedation as well as general anesthesia. The reasons for this are as a result of recent changes in rules regarding nurse administered sedation, coupled with the need for more sophisticated forms of sedation for the increasing number and complexity of endoscopies being performed. We report a case of bilateral pneumothoraces and pneumomediastinum after endoscopic retrograde cholangiopancreatography (ERCP) to demonstrate that not all GI endoscopy procedures are free from major complications. We discuss the role of the anesthesiologist in the GI suite and complications of GI endoscopies. Method

We describe a case of a 56 year old female who underwent ERCP for evaluation of chronic abdominal pain. During the procedure she developed a duodenal perforation, bilateral pneumothoraces and pneumomediastinum which required operative intervention and repair. Her postoperative course was complicated by an enterocutaneous fistula, retroperitoneal abscesses and a prolonged hospital stay. Conclusion

With increasing number of GI endoscopies being done under anesthesia administered sedation, we need to be educated and vigilant to the potential complications and disasters that may occur during routine endoscopies.

INTRODUCTION

The majority of patients require some form of sedation for gastrointestinal procedures. Traditionally sedation has been administered by endoscopists. Recently, in some U.S States, there have been changes in the rules regarding nurse administered deep sedation. That, combined with an increase in the number and complexity of endoscopy cases and endoscopies being performed on higher risk patients, anesthesiologists are being asked more and more to be involved in these cases to administer deeper and more sophisticated forms of sedation or in many cases general anesthesia. Because sedation for these endoscopies was previously performed by the endoscopists, we may imagine that these are noninvasive, low risk and safe procedures. This may lull us into a false sense of security. Furthermore, the environment and procedures of the GI endoscopy suite may be unfamiliar to the anesthesiologist performing the sedation. As a result we need to be educated and vigilant to

the potential complications that may occur during routine endoscopies.

Our case is one in which the major complication of duodenal perforation, bilateral pneumothoraces and pneumomediastinum occurred during ERCP with anesthesia administered deep sedation.

CASE PRESENTATION

Our patient was a 56 y/o female who presented for an elective outpatient endoscopic retrograde cholangiopancreatography (ERCP) to investigate abdominal pain and cramping which had been present for 8 months. An outside hospital CT scan noted intra and extrahepatic biliary dilation. Past medical history included hypertension, COPD, mild GERD and hyperlipidemia. Past surgical history included open cholecystectomy. She was initially evaluated in the preoperative area by the anesthesia team. MAC

(monitored anesthesia care) sedation administered by anesthesia providers was discussed with her. She was then brought to the ERCP suite by the anesthesia team and placed in the semi prone position. Full ASA monitors were applied as well as oxygen via nasal cannula. The patient was sedated with an infusion of propofol 9 mg/cc combined with alfentanil 45mcgs per cc. Once the patient reached a deep level of sedation a nasal trumpet was inserted to alleviate mild upper airway obstruction and the endoscope was introduced and advanced. She was maintained on a propofol/alfentanil continuous infusion. Vital signs remained stable and the patient maintained an oxygen saturation of 97% on 4 liters nasal cannula while breathing spontaneously throughout the procedure.

A periampullary diverticulum was found with the ampulla inside it. The lip of the diverticulum had to be lifted with the sphinctertome in order to see the ampulla. The bile duct could not be selectively cannulated. The pancreatic duct was cannulated and a guide wire was placed inside the pancreatic duct without injecting contrast. A pancreatic sphincterotomy was then performed. Several attempts were made at cannulation of the bile duct however it proved to be very difficult. While attempting cannulation of the bile duct, the patient desaturated to 80%, other vital signs were stable. She was thought to be obstructing secondary to the sedation so the decision was made to abort the procedure, discontinue the sedation and turn the patient to the supine position. The patient was placed supine and in the sitting position, 100% oxygen via a non rebreathing mask was administered. She was breathing spontaneously, responding normally to commands and alert and orientated times three. Her vital signs were normal except for a saturation of 86% on 100% oxygen via a non rebreathing mask. Upon examination, we found her to have excessive subcutaneous crepitations on her right and left chest wall, extending to her neck. The patient was emergently transferred, fully monitored to PACU for further evaluation.

A chest x ray was ordered which showed moderate right pneumothorax associated with extensive subcutaneous emphysema, free intraperitoneal air and suspected pneumomediastinum (figure1). A right sided chest tube was placed. Her vital signs remained stable and she did not require intubation. A CT of the chest and abdomen were then performed which showed extensive mediastinal free air, involving all compartments of the mediastinum from the thoracic inlet to the diaphragm, a large amount of

subcutaneous emphysema and small bilateral pneumothoraces (figure2). The abdominal CT showed large amounts of retroperitoneal air, moderate amount of free intraperitoneal air and subcutaneous emphysema along the right flank.

The patient was brought to the operating room for laparotomy and exploration after abdominal distention began to worsen on post procedure day number 1. She was found to have a duodenotomy in the second portion of her duodenum and extensive free bile in the peritoneal cavity. She had a resection of her duodenal diverticulum and over-sewing of her duodenotomy. She was transferred to the surgical ICU postoperatively.

Her postoperative course was complicated by an enterocutaneous fistula through her right upper quadrant incision which was treated with catheter drainage and a wound VAC. She also developed two subsequent retroperitoneal abscess which required operative drainage. She had a prolonged hospital course but was eventually discharged 24 days after her initial ERCP.

Figure 1

Fig 1 – Chest Xray showing right sided pneumothorax

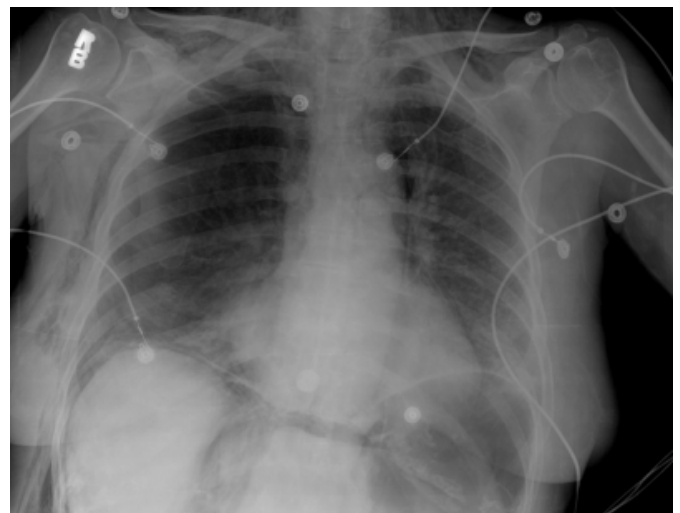
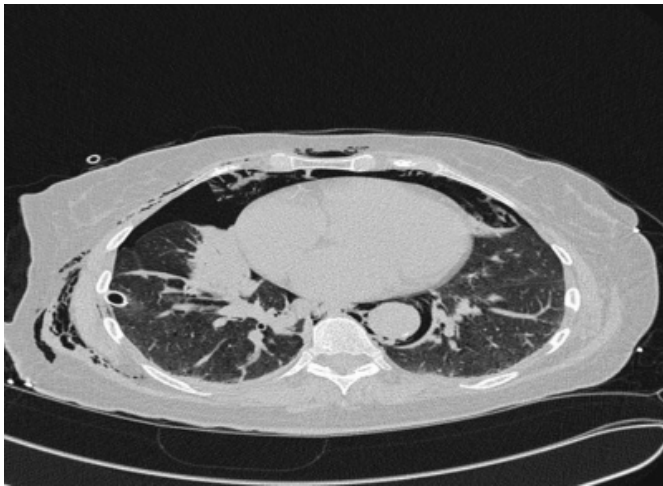

Figure 2

Fig 2 – CT Thorax showing pneumothorax and pneumomediastinum



DISCUSSION

Here we described an elective ERCP done under anesthesia administered sedation which had several severe adverse outcomes. Anesthesiologists often think of endoscopy procedures as benign procedures, given that the endoscopists themselves often both simultaneously perform the procedure and administer the sedation. However we must be vigilant to the adverse outcomes that can occur from a seemingly benign procedure.

WHEN EXACTLY IS AN ANESTHESIOLOGIST NEEDED FOR GI PROCEDURES?

First let us define moderate (conscious) versus deep sedation.

MODERATE (CONSCIOUS) SEDATION

Moderate sedation (conscious sedation) is a drug-induced depression of consciousness during which patients respond purposefully to verbal commands, either alone or accompanied by light tactile stimulation. No interventions are required to maintain a patent airway, and spontaneous ventilation is adequate. Cardiovascular function is usually maintained.¹

Many endoscopy procedures are done under moderate sedation. Examples of procedures that require moderate sedation are EGD and Colonoscopies. Moderate sedation is usually administered by the endoscopist with the assistance of trained nursing personnel. Generally they use a combination of benzodiazepine and opioid such as midazolam with morphine, meperidine or fentanyl.

DEEP SEDATION

Deep sedation is a drug-induced depression of consciousness during which patients cannot be easily aroused but respond purposefully following repeated or painful stimulation. The ability to independently maintain ventilatory function may be impaired. Patients may require assistance in maintaining a patent airway, and spontaneous ventilation may be inadequate. Cardiovascular function is usually maintained.¹

Deep sedation is generally required for a number of complex procedures that are more invasive, usually involving stenting, biopsy or drainage. Examples of procedures requiring deep sedation include:

- ERCP
- ENDOVASCULAR ULTRASOUND
- DOUBLE BALLOON ENDOSCOPY
- FEEDING TUBE PLACEMENT
- GASTRODUODENAL STENTING
- INTERVENTIONAL PROCEDURES

So when is an anesthesiologist needed for administration of sedation for endoscopy? There are several issues at hand which have recently changed the role of the anesthesiologist in the GI suite. In 2007 the Ohio Board of nursing changed its laws regarding nurse administered sedation. Here in Ohio nurses can now only administer moderate (conscious) sedation. Nurses can no longer administer deep sedation. Cases requiring deep sedation require the presence of an anesthesiologist to administer the deep sedation. The Nursing Interpretive Guidelines now state that “The nurse should not engage in activities that are the practice of anesthesia care...Therefore should not administer medications to induce deep sedation and/or anesthesia”²

There are several additional situations where the endoscopist may request an anesthesiologist for the administration of even moderate sedation. Examples include:

1. History of difficult sedation in the past
2. History of problems with anesthesia
3. Pregnancy
4. Morbid obesity

5. Delirium or dementia
6. Alcohol abuse
7. Chronic pain patients
8. Significant medical co-morbidities

Another reason for the increasing need to have an anesthesiologist present to perform deep sedation, is the ever increasing complexity of the endoscopy cases. Procedures have become more complex and instruments sophisticated. This leads to the need for more effective sedation and analgesia techniques and the need to leave the endoscopist free to concentrate on the procedure at hand.³

COMPLICATIONS OF ERCP

ERCP is performed as a diagnostic and therapeutic tool for a variety of biliary and pancreatic problems. Risk factors for complications include sphincter of oddi dysfunction, difficult cannulation, precut sphincterotomy in inexperienced hands, failure to achieve drainage and percutaneous transhepatic biliary access.⁴

Complications of ERCP include

- Hemorrhage (usually after sphincterotomy) 1.34%
- Perforation of viscus 0.6%
- Pancreatitis 3.4%
- Infection 1.44%
- Pneumothorax
- Gas embolism

Overall mortality is 0.33%.⁵

Our patient experienced the complication of duodenal perforation and subsequent pneumomediastinum and bilateral pneumothoraces.

Perforation during endoscopic sphincterotomy is a well recognized complication. It is usually retroperitoneal.⁶ Retroperitoneal perforation occurs due to extension of a sphincterotomy beyond the intramural portion of the biliary or pancreatic duct. Intraperitoneal perforation may occur due to perforation of the bowel wall by the endoscope. Our patient had both intraperitoneal and retroperitoneal air from a duodenal perforation. Risk of perforation is less than 1% of

ERCPs and sphincterotomies. Perforation is more likely in patients with Billroth 2 anatomy, needle-knife sphincterotomy, and sphincter of oddi dysfunction.⁴ The presence of juxtaapillary diverticulum has not been shown to increase risk of perforation.^{6, 7, 8}

Pneumothorax and pneumomediastinum resulting from perforation after ERCP and sphincterotomy has been reported many times in the literature.^{9,10,11,12,13,14,15,16,17} The extensive emphysema is thought to be due to excessive air insufflation during the procedure after the perforation has occurred. The retroperitoneum is divided by the anterior and posterior renal fascia into three compartments which are in communication. After duodenal perforation air enters the right anterior pararenal space and then can further travel inferiorly and communicate with the posterior pararenal compartment. The posterior pararenal compartment extends through the diaphragmatic hiatus and into the mediastinum. Thus air under pressure enters the retroperitoneum and travels into the mediastinum causing pneumothoraces and pneumomediastinum as well as subcutaneous emphysema.⁹ The amount of air leakage may not reflect the size of the perforation as much as the extent and duration of manipulation performed after the perforation.⁶

Duodenal perforation is best diagnosed by abdominal CT.¹⁸ The treatment of perforation depends on the clinical state of the patient. Conservative management is recommended for patients with minimal signs, normal white cell count and absence of fever. This involves treatment with antibiotics, nasogastric suction and nothing by mouth. Surgical management with closure of the perforation and drainage of the retroperitoneal space is recommended for patients with signs of sepsis, contrast leakage or evidence of collections.¹⁹

CONCLUSION

Due to recent changes in nurse administered sedation, coupled with the need for more sophisticated forms of sedation for the increasing number and complexity of endoscopies being performed, anesthesiologists are now more commonly seen in the GI suite administering sedation as well as general anesthesia. As our report here shows, not all GI endoscopy procedures are free from major complications. Therefore we must be vigilant to these possible disastrous events as we anesthetize and monitor these patients.

References

1. American Society of Anesthesiologists Task Force on

Sedation and Analgesia by Non-Anesthesiologists. Practice guidelines for sedation and analgesia by non-anesthesiologists. *Anesthesiology*. 2002. 96(4):1004-17.

2. http://www.aorn.net/chapter3602/files/IG_Mod_Sedation.pdf

3. Trummel J. Sedation for gastrointestinal endoscopy: the changing landscape. *Current Opinion in Anaesthesiology*. 2007. 20(4):359-64.

4. Freeman ML. Adverse outcomes of endoscopic retrograde cholangiopancreatography. [Review] [99 refs] *Reviews in Gastroenterological Disorders*. 2002. 2(4):147-68.

5. Andriulli A. Loperfido S. Napolitano G. Niro G. Valvano MR. Spirito F. Pilotto A. Forlano R. Incidence rates of post-ERCP complications: a systematic survey of prospective studies. *American Journal of Gastroenterology*. 2007. 102(8):1781-8.

6. Catton PB, Lehman G, Vennes J, et al. Endoscopic sphincterotomy complications and their management: an attempt at consensus. *Gastrointest Endosc* 1991; 37: 383-93

7. Vaira D, Dowsett JF, Hatfield AR, Cairns SR, Polydorou AA, Cotton PB, Salmon PR, Russell RC. Is duodenal diverticulum a risk factor for sphincterotomy?. *Gut*. 1989. 30(7):939-42.

8. Shemesh E, Klein E, Czerniak A, Coret A, Bat L. Endoscopic sphincterotomy in patients with gallbladder in situ: the influence of perampullary duodenal diverticula. *Surgery*. 1990. 107(2):163-6.

9. Savides T, Sherman S, Kadell B, Cryer H, Derezin M. Bilateral pneumothoraces and subcutaneous emphysema after endoscopic sphincterotomy. *Gastrointestinal Endoscopy*. 1993. 39(6):814-7.

10. Lagoudianakis EE, Tsekouras D, Papadima A, Genetzakis M, Pattas M, Giannopoulos P, Konstadoulakis MM, Manouras A. Pneumothorax complicating endoscopic sphincterotomy successfully treated conservatively. *Acta*

Gastroenterologica Belgica. 2006. 69(3):342-4.

11. Evrard S, Mendoza L, Mutter D, Vetter D, Marescaux J. Massive gas spread through a duodenal perforation after endoscopic sphincterotomy. *Gastrointestinal Endoscopy*. 1993. 39(6):817-8.

12. Nam JS, Yi SY. Massive pneumoperitoneum and pneumomediastinum with subcutaneous emphysema after endoscopic sphincterotomy. *Clinical Gastroenterology & Hepatology*. 2004. 2(11):xxii.

13. Ibrarullah, Saxena R, Agarwal DK, Saraswat VA. Massive subcutaneous and mediastinal emphysema due to duodenal perforation following endoscopic sphincterotomy. *Indian Journal of Gastroenterology*. 1993. 12(1):21-2.

14. Gya D, Sali A, Angus D. Subcutaneous emphysema and pneumothorax following endoscopic sphincterotomy. *Australian & New Zealand Journal of Surgery*. 1989. 59(11):900-2.

15. Hui CK, Lai KC, Yuen MF, Lam SK. Tension pneumothorax complicating ERCP in a patient with a Billroth II gastrectomy. *Gastrointestinal Endoscopy*. 2001. 54(2):254-6.

16. Ciaccia D, Branch MS, Baillie J. Pneumomediastinum after endoscopic sphincterotomy. *American Journal of Gastroenterology*. 1995. 90(3):475-7.

17. Morley AP, Lau JY, Young RJ. Tension pneumothorax complicating a perforation of a duodenal ulcer during ERCP with endoscopic sphincterotomy. *Endoscopy*. 1997. 29(4):332.

18. Kuhlman JE, Fishman EK, Milligan FD, Siegelman SS. Complications of endoscopic retrograde sphincterotomy: computed tomographic evaluation. *Gastrointestinal Radiology*. 1989. 14(2):127-32.

19. Scarlett PY, Falk GL. The management of perforation of the duodenum following endoscopic sphincterotomy: a proposal for selective therapy. *Australian & New Zealand Journal of Surgery*. 1994. 64(12):843-6.

Author Information

Ursula A Galway, MD

Staff, Department of General Anesthesiology, Cleveland Clinic