

# A rare case of Bone Tuberculosis, associated complexities and cure: A Case Report

H Muppala

## Citation

H Muppala. *A rare case of Bone Tuberculosis, associated complexities and cure: A Case Report*. The Internet Journal of Infectious Diseases. 2006 Volume 6 Number 1.

## Abstract

A rare case of complicated (multiple) bone tuberculosis in atypical locations, the right calcaneum and distal tibia, was effectively treated through simultaneous anti-tuberculosis therapy and surgical treatment (including at least two curettage procedures) on a person in his late 20s. The lesion was also successfully closed through muscle flap and split skin transplantation. No bone grafting was performed. Thenceforth, excellent healing with few limited residual disabilities was reported.

## INTRODUCTION

Tuberculosis still remains a large concern, in one form or the other [1]. Despite advances in medical research, little is discernible as to why osteomyelitis associated to tuberculosis [2] is a frequent concern. Brodie abscess, a form of subacute osteomyelitis, is sometimes difficult to diagnose as the characteristic signs and symptoms of the acute form of the disease may be absent, or mimic other disorders, leading to diagnostic and therapeutic delay [3]. It has an insidious onset, mild symptoms, and lacks a systemic reaction, and supportive laboratory data may be inconsistent. This is a likely reason for the improper diagnosis in this case too. This is a case of multiple-pseudo-cystic tuberculosis in calcaneus in an adult of late 20s, not involving the commonly associated joints [4,5]. Its incidence is reported to be nearly 1% to 2% of all cases of osteoarticular tuberculosis [1, 6]. This atypical case is also involved with complex rectifying procedures. Several cases found in literature, for e.g., [7], report mostly in children.

Complication: Tuberculin and AFB tests were not part of differential diagnosis, until the first operation was conducted.

Setting at: Departments of Accident and Emergency, Internal Medicine, and Hand & Plastic surgery, University of Erlangen, Germany.

## CASE HISTORY

This patient of Asian origin migrated to Europe, when aged 28 suffered with symptoms of mild pain in the right heel

region (end of year 2003); it was treated for as a case of mere muscle distraction/a kind of little common sprain by an orthopaedician for over a span of months, until the situation turned irrecoverable by any simplistic means.

The first MRI report (March 2004) inferred to either infection or tumour of the calcaneus bone. First surgical operation was conducted on 30th April 2004; lateral side of the right calcaneus was opened and debridement of muscle and bone was carried out and the lesion closed with a 'sulmycin-sponge implant' on vacuum assisted closure for local prevention of infection in surgical region. Microbiological swabs taken during surgery showed no sign of bacterial infection. The histopathological analysis of intraoperative biopsy material was still in progress. Patient was discharged following the normal wound conditions.

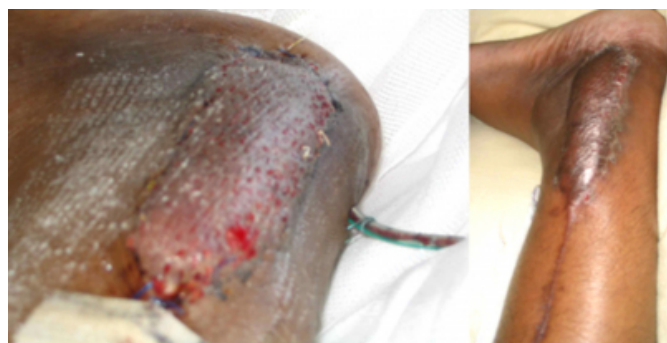Within 8 weeks after the operation, patient was readmitted to the hospital with complaints of pus draining from a newly formed sinus on lateral part of the heel, with severe pain, and a diffuse bony swelling with little restrictive movements. In fact, patient never had pain-free period after the first operation. Large areas of necrosis and substantial dead bone were found. Grey-brown rough solid tissue parts in a span of dia 2.5 cm was found in the calcaneus. In addition, inflamed granulation tissue (granuloma) with Epithelioid cells, lymphocytic infiltration and giant cells of the type of Langhans cells were noticed. The histopathological findings and clinical observations led to the suspicion of bone tuberculosis. The leukocytes were 6.460 / l in the standard range, with CRP 7mg/l. The Tuberculin test (Tine test) was evidently positive by first week of July 2004.

Anti-tuberculosis treatment was given for 12 months. After one month of drug treatment, the lesion was opened up twice in successive months, for launching curettage procedures; followed by sulmycin-sponge implants, with the resection defect of distal tibia filled with calcium alginate to absorb wound exudates and for calcium build up to accelerate formation of granulation tissue. At this stage, patient was complaining of constant severe pain, with impaired mobility, and decreased sensibility. The right foot was in a mid-equinus position.

After conditioning of the wound by vacuum assisted closure therapy, histopathologic, radiologic and szintigraphic verification of a completely remediated bone status, on 30th Aug 2004 the defect on the right lateral ankle (4\*4 cm wide and 6 cm deep bone/soft-tissue) covering with a distal pediculate peroneus brevis muscle flap and split skin transplantation from the right thigh was successfully performed (Fig 1). No bone grafting was performed [8]. This procedure ensured the tissue transplanted into the void bone and surrounding region forming rock-like after several months of steady mobility of the leg, which has been confirmed by MRI performed in April 2005 (Fig. 1&2).

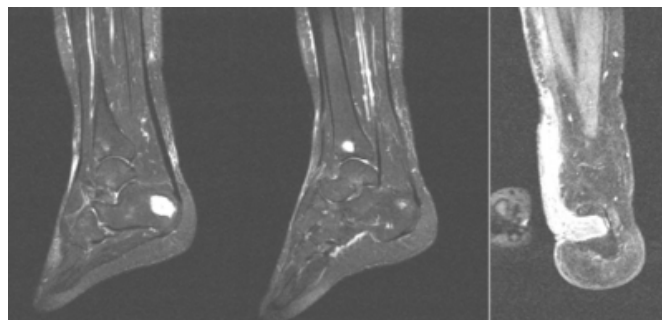
### Figure 1

Figure 1: Photo taken: (L) on third day and (R) after two and half months after plastic surgery. A lengthy scar, on the RHS picture, marks the region where distal pediculate peroneus brevis muscle flap was taken.



### Figure 2

Figure 2: MRI images 2 weeks after plastic surgery (L to R). a) Permanent void regions of calcaneus, and tibia seen in sharp contrast. b) The lengthy region with muscular flap insertion, in 'L' shape.



Precepts of the final culture (C) reports, which were obtained plus or minus two weeks from the date of plastic surgery, are presented here. Requirements involved investigation of mycobacterium and/or Ziehl-Neelsen staining. For the material 1) sputum: microscopic (M) findings of no proof of acid-resistant rods and -ve culture, 2) abscess drainage: -ve C at 28°C and -ve M, nucleic acid (NC) and C findings at 37°C, 3) bronchial lavage: -ve M at 28°C, and -ve M, NC and C findings at 37°C, 4) lesion smear- right ankle: -ve M findings, and 5) wound secretion, M and NC tests were -ve, excepting the C findings +ve.

### POST-OPERATIVE COMPLEXITIES

When this case report was submitted after 20 months of last MRI report, patient complained of having minimal disabilities in the form of inability to walk long distances, run, and carry loads as it would elicit mild pain.

### DISCUSSION

Any individual of Afro/Asian origin dwelling in western countries who has been screened for tuberculosis, inferring "not active" in his/her early years of stay, but who later presents with symptoms of pain in the spine or other skeletal parts, then tuberculosis should also be considered as part of the differential diagnosis and in fact with high degree of suspicion. This will ensure early diagnosis and that treatment can be initiated, thereby reducing associated morbidity.

### ACKNOWLEDGEMENT

Patient's consent in presenting the case report, besides providing photos and MRI images, is gratefully acknowledged.

### References

1. Sequera, W., Co, H., Block, J. Osteoarticular tuberculosis:

- current diagnosis and treatment. *Am J Ther* 2000;Vol.7, pp.393-398.
2. O'Malley, B. W., Zeff, J. H. Disseminated Bone Tuberculosis without pulmonary manifestation. *Ame. Jour. of Med* 1965;Vol.38, pp.932 - 936.
3. Dhillon, M. S., Nagi, O. N. Tuberculosis of the Foot and Ankle. *Clinical Orthopaedics & Related Research* 2002;Vol.398, pp.107-113.
4. Davies, P. D., Humphries, M. J., Byfield SP, Nunn, A. J., Darbyshire, J. H., Citron, K. M., Fox, W. Bone and joint tuberculosis. A survey of notifications in England and Wales. *J Bone Joint Surg Br* 1984;Vol.66, pp.326 - 330.
5. Watts, H. G., Lifeso, R. M. Tuberculosis of bone and joints. *J Bone Joint Surg Am* 1996;Vol.78,pp.288-298.
6. Trikha, V., Gupta, V., Rastogi, S., Kumar, R. Tuberculosis of Calcaneus: Assessing Treatment Response by Tc-99m MDP Scintigraphy. *Clinical Nuclear Medicine* 2004;Vol.29,pp.506.
7. Padmini, U., Thomas, S., Manjunath, K. Y. Multiple pseudocystic tuberculosis of the bone. *Ind. J. Tub* 1978;Vol.XXV No.3.
8. Martin, R., Bernhard, F., Marina, N., Anton, S., Milomir, N. A Single-Stage Operation in the Treatment of Chronic Osteomyelitis of the Lower Extremity Including Reconstruction with Free Vascularized Iliac Bone Graft and Free-Tissue Transfer. *Plastic & Reconstructive Surgery* 2003;Vol.111,pp.2353-2361.

**Author Information**

**H. Muppala**

Women's Health Directorate, Royal Blackburn Hospital