

Necrotizing Granulomatosis Causing A Malignant Airway Obstruction

A Huaringa, N Zetola, F Leyva, J Blanco, N Herrera

Citation

A Huaringa, N Zetola, F Leyva, J Blanco, N Herrera. *Necrotizing Granulomatosis Causing A Malignant Airway Obstruction*. The Internet Journal of Pathology. 2000 Volume 1 Number 2.

Abstract

A 51-year-old Hispanic woman was referred to The University of Texas M. D. Anderson Cancer Center with a 5-year history of dyspnea, coughing, wheezing, mediastinal widening, and a mass in the right upper lobe of the lung. A small cell lymphocytic lymphoma producing an extensive necrotizing granulomatosis reaction was diagnosed during her workup. Ten months later, the patient developed a severe obstructive respiratory syndrome, and died of respiratory insufficiency. This appears to be a case of necrotizing sarcoid granulomatosis causing a malignant airway obstruction.

Abbreviations:

BAL=Bronchoalveolar lavage

NSG=Necrotizing sarcoid granulomatosis

RUL=Right upper lobe

INTRODUCTION

Sarcoidosis is a systemic noncaseating granulomatosis that affects the lungs and lymphatic system. Necrotizing sarcoid granulomatosis (NSG) is an extreme of the spectrum of granulomatous reaction. Although granulomas are found in the tracheal mucosa in sarcoidosis, they do not cause significant airway obstruction.

We present the first case of NSG causing complete bronchial obstruction.

CASE REPORT

A 51-year old Hispanic woman was referred to The University of Texas M. D. Anderson Cancer Center's pulmonary service because of dyspnea, coughing, and wheezing. Nine years earlier, she was diagnosed of bilateral breast cancer. She underwent bilateral mastectomy with a left lymph node dissection, where one node was found positive for malignant cells. The woman then received cyclophosphamide, doxorubicin and fluorouracil.

The patient's symptoms of progressive shortness of breath and dry hacking cough started 5 years before admission. A chest x-ray taken 18 months before showed a right upper lobe (RUL) mass. She underwent bronchoscopy that showed

complete obstruction of the RUL. Bronchoalveolar lavage (BAL) was negative for cancer and biopsy revealed noncaseating granulomata. Patient was discharged on antibiotics, tamoxifen, and corticosteroid therapy.

Her past medical history was remarkable for steroid-induced diabetes, and non-invasive colon carcinoma resected 15 years ago. She denied allergies, smoking, or abusing drugs, and her family history was unremarkable.

Physical examination revealed mild respiratory distress with systemic lymphadenopathy. The examination of the patient's chest revealed bilateral wheezes. The remainder of the physical examination was unremarkable.

Radiography showed a mass involving the RUL and mediastinum, with extensive mediastinal, abdominal, and axillary adenopathy (Figure 1). Bronchoscopy showed non-necrotic vascular tissue almost completely obstructing the RUL, left upper lobe upper division, and the superior segments of both lower lobes. BAL and biopsy of the lesion showed noncaseating granulomata. Pulmonary function tests showed obstructive defect. Biopsy of mediastinal lymph nodes revealed small cell lymphocytic lymphoma, mixed with multiple necrotizing granulomata. Cultures were negative for acid-fast bacillus, fungus and other organisms. The carcinoembryonic antigen level was less than 1.5 (g/liter, a bone scan was negative, and the angiotensin-converting enzyme level was 79 U/liter. The patient's disease was diagnosed as small cell lymphocytic lymphoma with an aggressive NSG obstructing the airways. She was

given prednisone, chemotherapy with fludarabine, and discharged.

Figure 1

Figure 1. Chest CT scan shows obstruction of the right upper lobe bronchus by a mass. Mediastinal and axillary lymphadenopathy can also be observed

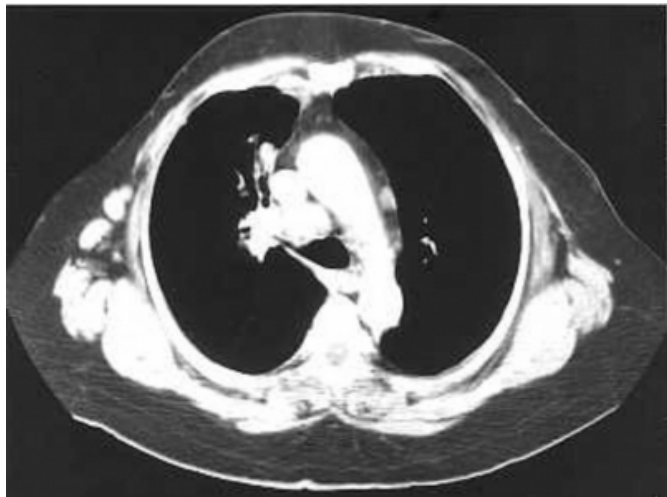


Figure 2

Figure 2. A chest x-ray taken 18 months before showed a right upper lobe (RUL) mass

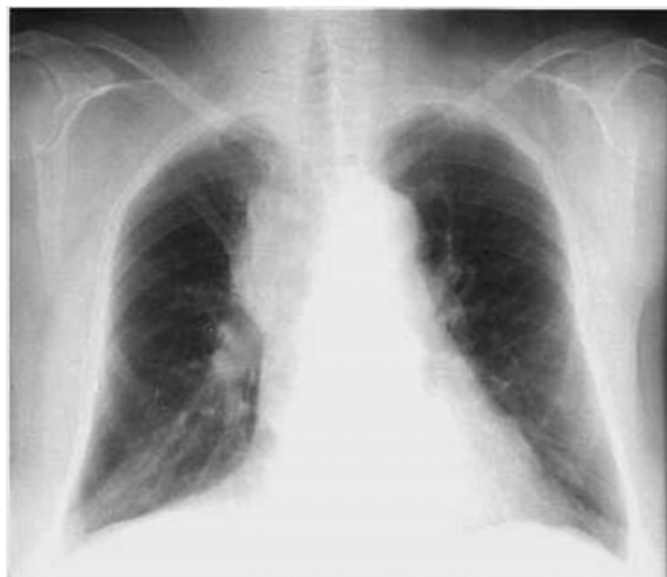

Figure 3

Figure 3. Bronchoscopy showed non-necrotic vascular tissue almost completely obstructing the RUL



Figure 4

Figure 4. Lymph node biopsy disclosing necrotizing granulomata interspersed with small cell lymphocytic lymphoma (hematoxylin-eosin, original X 150)

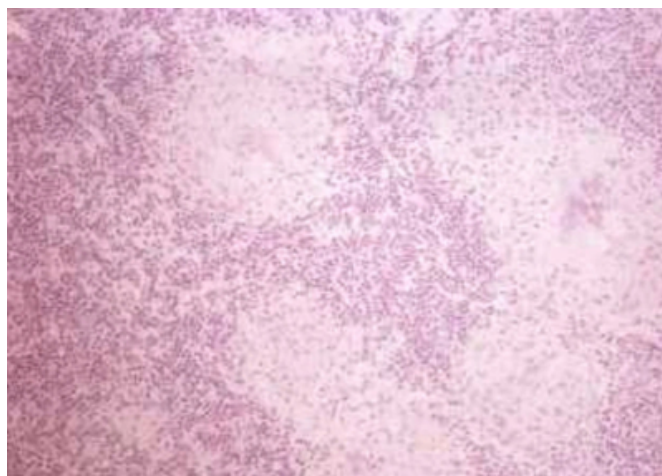
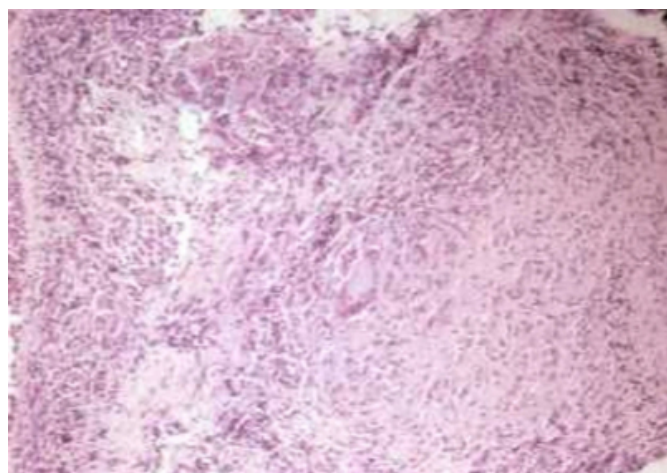


Figure 5



The signs and symptoms of the disease improved. However, four months later, she was readmitted to the hospital due to an exacerbation of her obstructive airway process and pneumonitis. Two months after, she went into respiratory failure and died of multiple opportunistic infections, septic shock and multisystem organ failure.

DISCUSSION

Granuloma formation is a nonspecific immunologic response. A wide range of infections, chemicals, enzyme defects, neoplasms, allergens, and other conditions can trigger the genesis of granulomata ¹.

The diagnosis of sarcoidosis is based on clinical and radiologic evidence, demonstration of typical lesions in more than one organ, and exclusion of any other possible cause of granuloma formation.

A variant of sarcoidosis, the necrotizing sarcoid granulomatosis is believed to have a similar natural history but more aggressive behavior. NSG, as malignant obstructing airway disease, has never been previously reported.

In 1974, Brincker and Wilbek found that the incidence of lymphoma in patients previously diagnosed with sarcoidosis was 11 times higher than in the healthy population ². A decade later, Brincker proposed the existence of a sarcoidosis-lymphoma syndrome³. However, another study showed that the frequency of lymphoma in sarcoidosis patients was similar to that of the general population ⁴. Therefore, existence of an association is still debatable.

The detection and destruction of neoplastic cells are mediated by immunologic mechanisms as evidenced by the higher risk to develop cancer among patients with immunodeficiencies. Based on this concept, some theories have been proposed to explain the relationship between sarcoidosis and lymphoma. The first theory is that abnormal T-cell function is present in sarcoidosis, which may predispose individuals to develop cancer. The appearance of sarcoidosis after cessation of chemotherapy or immunosuppressive treatment and its improvement following corticosteroid therapy supports this theory. Another theory is that sarcoidosis is a generalized cell immune response to antigens, representing the systemic extreme of a spectrum that has sarcoid-like granulomas at the other extreme ⁵. Other authors have tried to find a link between sarcoid-like reaction and cancer treatment. However, there have been reported cases in which sarcoidosis preceded the treatment ⁶.

At any event, the association between lymphoma and sarcoid-like reactions or sarcoidosis has clinical relevance. As shown in this case, the presence of both diseases could make diagnosis and imaging interpretations difficult and could also complicate the course of treatment.

We believe that when a patient presents with necrotizing granulomatosis, we must first rule out infections and immunologic conditions (e.g. Wegener's granulomatosis, or Churg-Strauss syndrome) and then consider the diagnosis of NSG only when all other possible causes are excluded.

References

1. Statement on sarcoidosis. Joint Statement of the American Thoracic Society (ATS), the European Respiratory Society (ERS) and the World Association of Sarcoidosis and Other Granulomatous Disorders (WASOG) adopted by the ATS Board of Directors and by the ERS Executive Committee, February 1999. *Am J Respir Crit Care Med* 1999; 160:736-755
2. Brincker H, Wilbek E. The incidence of malignant tumours in patients with respiratory sarcoidosis. *Br J Cancer* 1974; 29:247-251
3. Brincker H. The sarcoidosis-lymphoma syndrome. *Br J Cancer* 1986; 54:467-473
4. Romer FK. Sarcoidosis and cancer: A critical review. In: Williams WJ, Davies BH, ed. Eight international conference on sarcoidosis and other granulomatous disease. London: Alpha Omega Publishing, 1980; 561-571
5. Reich JM. Acute myeloblastic leukemia and sarcoidosis. Implications for pathogenesis. *Cancer* 1985; 55:366-369
6. Looijen R, Hoekstra HJ, Sleijfer DT, et al. Sarcoid reaction mimicking intrathoracic dissemination of testicular cancer. *Cancer* 1990; 66:2221-2223

Author Information

Armando J. Huaringa, MD, FACP, FCCP

Department of Internal Medicine Specialties, Pulmonary and Critical Care Medicine, The University of Texas M. D. Anderson Cancer Center

Nicola M. Zetola

Department of Internal Medicine Specialties, The University of Texas M. D. Anderson Cancer Center

Francisco Leyva, MD J. Leyva, MD

Department of Internal Medicine Specialties, The University of Texas M. D. Anderson Cancer Center

Jose J. Blanco, MD

Department of Internal Medicine Specialties, The University of Texas M. D. Anderson Cancer Center

Norky E. Herrera, MD

Department of Internal Medicine Specialties, The University of Texas M. D. Anderson Cancer Center