

# Ultrasonographic diagnosis Gallbladder wall thickening

A Aissi, S Touri

## Citation

A Aissi, S Touri. *Ultrasonographic diagnosis Gallbladder wall thickening*. The Internet Journal of Veterinary Medicine. 2007 Volume 4 Number 2.

## Abstract

## HISTORY

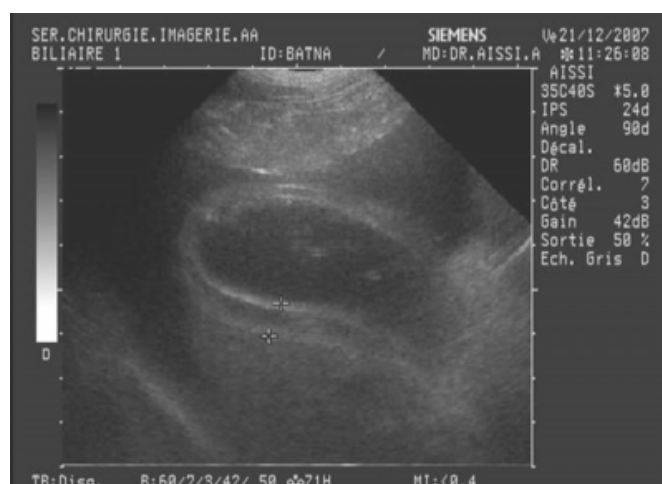
A three-year-old, male, Poodle was referred to the Batna University, Surgery and imaging service for ultrasound diagnosis of a chronic liver problem. The dog was depressed with no appetite for one month and had a high fever during the first week of illness. The dog had been treated for liver disease but the serum alanine aminotransferase (ALT) and alkaline phosphatase (ALP) remained at the high level of 149-254 U/L and 1,056-1,810 U/L, respectively, over a period of three weeks. On the day prior to referral, ALT and ALP were 184 U/L and 2,710 U/L. The dog would not eat unless the owner fed her. On admission to the service, the dog was depressed and lethargic. Rectal temperature was 100.6 oF. Abdominal radiographs were obtained and a mild hepatomegaly was evident.

## ULTRASONOGRAPHIC FINDINGS

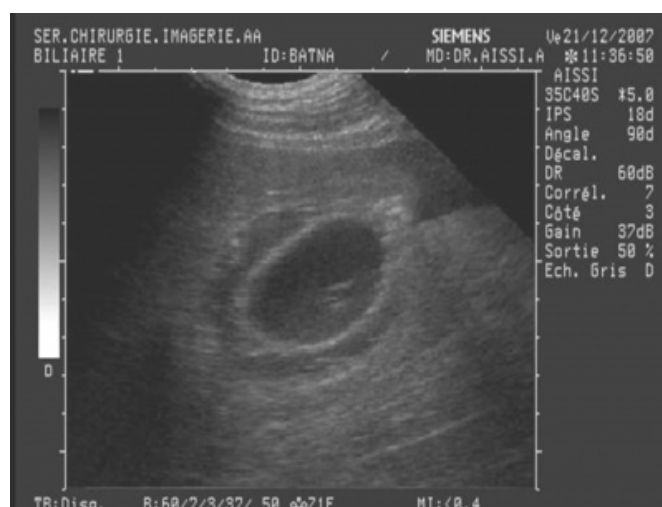Ultrasonographic examination of the abdomen was performed using a real time scanner with an 5 MHz broadband, convex, phased array transducer. Sagittal and transverse scans of the hepatic parenchyma revealed a normal echogenicity (Figures 1) which was slightly more echogenic compared to that of the cortex of the right kidney and hypoechoic to the head of the spleen. The gallbladder was oval in shape and anechoic in echogenicity with distal acoustic enhancement. The gallbladder wall was symmetrically thickened, about 5 mm. It appeared as a hypoechoic region between the two echogenic lines. A small amount of echogenic sediment was present within the gall bladder. Other abdominal organs appeared normal.

## Figure 1

Figure 1: Right sagittal ultrasonographic image of the liver, in a 3-year-old, Poodle, in dorsal recumbency. Gallbladder wall thickening was demonstrated as a hypoechoic region between the two echogenic lines.



## Figure 2



## DIAGNOSIS

Ultrasonographic diagnosis Gall bladder wall thickening.

### **COMMENTS**

The normal gallbladder is sonographically seen as an anechoic, smooth-marginated, round to oval structure within the liver, just to the right of the midline. Acoustic enhancement is commonly seen distal to the gallbladder.

Slice thickness and side lobe

artifacts can be seen within the gallbladder lumen and can be minimized by changing the angle of the transducer and ultrasound beam or repositioning the patient. The size of the gallbladder varies with the fasting or fed condition of the patient.

Echogenic sediment may be detected within the gallbladder but this finding does not correlate with disease in the dog or cat. Normally, the gallbladder wall is nonvisualized or poorly visualized as a thin echogenic line (Nyland and Hager, 1985) When the gallbladder wall becomes thickened from wall edema in inflammatory diseases, an echogenic double-rim effect is produced by reflections from the inner

chronic hepatitis, cholecystitis or cholangiohepatitis(Nyland and Park, 1983; Nyland and Hager, 1985). It can also be seen in association with other conditions such as sepsis and neoplasia (Willard et al., 1988; Rivers et al., 1997).

Ultrasonically guided, percutaneous, liver biopsy and cholecystocentesis for cytological examination and culture of bile have been suggested as aids to determine the cause of gallbladder wall thickening.

### **References**

- r-0. Nyland, T.G. and Hager, D.A. 1985. Sonography of the liver, gallbladder, and spleen. *Vet. Clin. North Am. Small Anim. Pract.* 15(6): 1123-1148.
- r-1. Nyland, T.G. and Park, R.D. 1983. Hepatic ultrasonography in the dog. *Vet. Radiol.* 24(2): 74-84.
- r-2. Rivers, B.J., Walter, P.A., Johnston, G.R., Merkel, L.K. and Hardy, R.M. 1997. Acalculous cholecystitis in four canine cases: ultrasonographic findings and use of ultrasonographic-guided, percutaneous cholecystocentesis in diagnosis. *J. Am. Anim. Hosp. Assoc.* 33: 207-214.
- r-3. Willard, M.D., Dunstan, R.W. and Faulkner, J. 1988. Neuroendocrine carcinoma of the gallbladder in a dog. *J. Am. Vet. Med. Assoc.* 192(7): 926-928.

**Author Information**

**A. Aissi**

Head of surgery and imaging service, Veterinary Department, Faculty of sciences, Batna University

**S. Touri**

Surgery and imaging service, Veterinary Department, Faculty of sciences, Batna University