

# Transdermal Methyl Alcohol Intoxication:Case Report

D YAVUZ DEMİRAY, D ULUDÜZ, B GÖKSAN

## Citation

D YAVUZ DEMİRAY, D ULUDÜZ, B GÖKSAN. *Transdermal Methyl Alcohol Intoxication:Case Report*. The Internet Journal of Toxicology. 2009 Volume 7 Number 2.

## Abstract

## INTRODUCTION

Methyl alcohol is a toxic substance which is used as a raw material in industrial production of a wide array of end products including dye, wax, ice solvents etc (1). We do seldomly observe acute methyl alcohol intoxications as a result of accidents, suicide attempts and substance abuse. Methyl alcohol metabolites are formaldehyde and formic acid, which produce a toxic effect causing intracranial bilateral putamen necrosis and neurological symptoms which could progress from metabolic acidosis, loss of vision and extrapyramidal signs to seizure and coma. Toxication ensues most frequently via oral route but it may also result via industrial inhalation route and, although very seldomly, via transdermal route (2,3).

Herein, a forty-four years-old woman with severe central nervous system involvement due to transdermal methyl alcohol intoxication is presented.

## CASE REPORT

A forty-four year old female patient applied to our clinic with bilateral loss of vision, difficulty in speaking, dysphagia and a noticeable slowdown in movements.

According to the anamnesis given by the patient, almost two months ago she did apply a mixture of ethyl and methyl alcohol (known as 'spirit') as an air-tight compression on her right knee for a duration of six hours in order to alleviate her severe joint pain resulting from rheumatoid arthritis. Soon after compression severe nausea and vomiting started. Next day sudden and bilateral loss of vision, difficulty in speaking and dysphagia were accompanied. In time a progressive slowdown in movements developed.

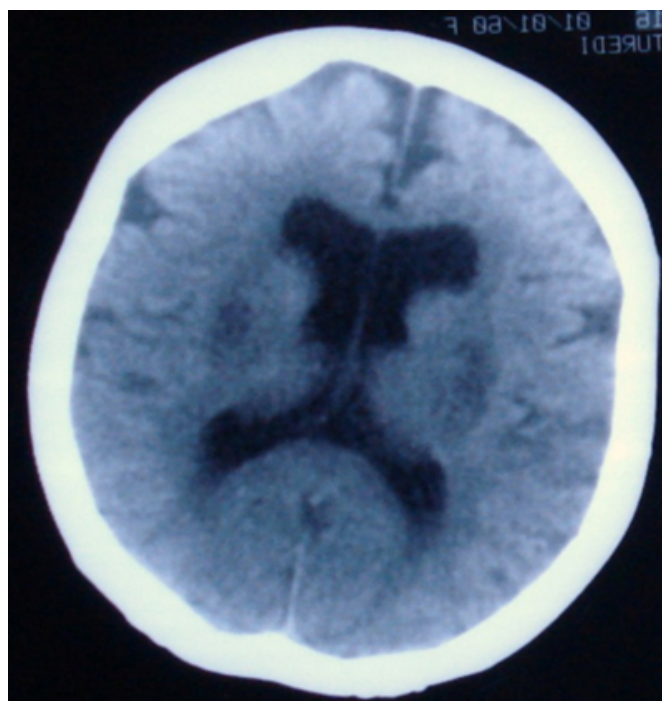
Two months later when the patient has finally applied to our clinic, a thorough neurological examination revealed bilateral optic nerve atrophy, total loss of vision, dysarthria, dysphagia, dysarthria and rigidity of the extremities. Routine

biochemical evaluation was normal. A hypodense appearance of basal ganglia bilaterally was noticed on the cranial CT examination (Picture 1). Cranial MRI revealed bilateral putamen necrosis (Picture 2).

Serum levels of methyl alcohol could not be determined owing to the fact that the patient applied to our clinic 2 months after the incident. But the analysis of the spirit revealed that it actually contains almost ten times more methyl alcohol content compared to ethyl alcohol. After the analysis of the results obtained from clinical and laboratory investigations, the clinical picture is suggested to be related to methyl alcohol intoxication via transdermal route.

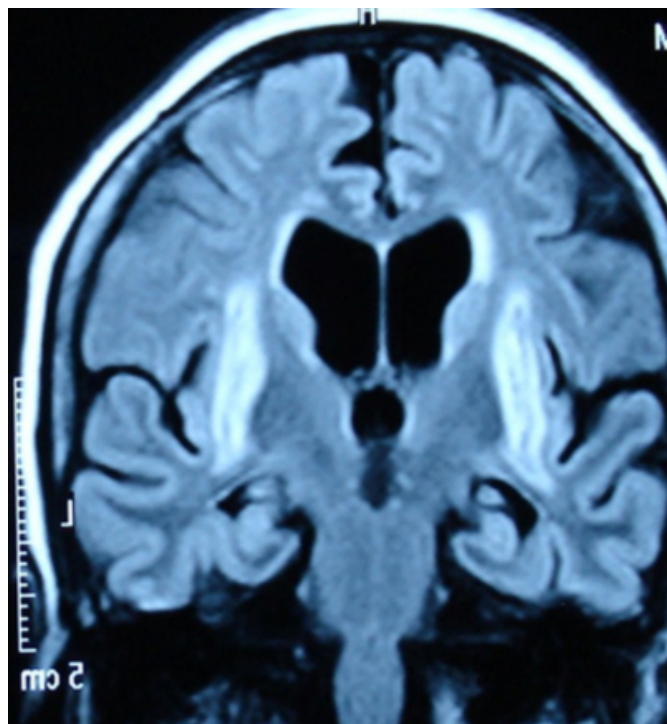
## Figure 1

Figure 1: Bilateral hypodensity in basal ganglia



**Figure 2**

Figure 2:Bilateral putaminal necrosis in cranial MRI



## DISCUSSION

Methanol is a component of varnishes, paint removers, perfumes, antifreeze, copy machine fluid and gasoline mixtures, and may be ingested accidentally or intentionally. Methyl alcohol is rather cheap thus it may be mixed on purpose into alcoholic drinks in our country and can cause deaths. It is most frequently consumed orally but industrial exposure to its vaporised form and transdermal intake via heavily contaminated clothes may also result in toxicity (4). It is a CNS depressant that is potentially toxic after ingestion, inhalation or transdermal exposure like in our case. Methyl alcohol intoxication tends to involve optic nerves and basal ganglia especially putamen in the central nervous system. (5,6) Putamen necrosis occurs as a direct toxic effect of formic acid with higher concentrations of formic acid accumulating in the putamen compared to other areas of the brain. These findings suggest that the putamen may indeed be more sensitive to an acidic environment than other areas of the brain. Formic acid accumulation due to methyl alcohol poisoning inhibits cytochrome oxidase activity and because of dependence of axoplasmic transport in nerves on oxidative metabolism, severe disruption of optic nerve function occurs (7). In the differential diagnosis of cranial involvement, Wilson disease, Leigh disease, Kearns-Sayre syndrome and Leber's optic atrophy should be all kept in mind (8). In addition to these conditions carbon monoxide

inhalation and hypoxic anoxic damage may also manifest themselves on basal ganglia but the combination of optic atrophy and bilateral putaminal haemorrhagic infarctions is unique to methanol intoxication.

Methanol poisoning typically induces nausea, vomiting, abdominal pain, and mild central nervous system depression. If it progresses, uncompensated metabolic acidosis develops and visual function becomes impaired, ranging from blurred vision and altered visual fields to complete blindness. (9). In the patient there was also a time between initial symptoms and the visual symptoms, this characteristic latent period is thought to result from the slow metabolism of methanol to the principal toxic product, formic acid.

The diagnosis is sometimes elusive and requires a high index of suspicion, it is important to recognize methanol poisoning promptly because it has an antidotal treatment. The mainstay of treatment for methanol intoxication is the administration of ethanol. The other treatments are intravenous sodium bicarbonate, fomepizole and haemodialysis (10). Ethanol and fomepizole blocks methanol metabolism. The presence of metabolic acidosis associated with an increased anion gap and increased osmol gap are important laboratory findings. (2,11)

In our case all other etiological factors were excluded with the help of clinical and laboratory findings. The distinguishing feature of this case is that six hours-long spirit compression resulted in severe central nervous system findings with diffuse necrosis on putamen bilaterally. There are published papers in the literature reporting that these clinical findings are frequently seen after oral intake of methyl alcohol. However it should be kept in mind that although infrequent, transdermal application, as it was in our case, may also result in severe intoxication.

## References

1. HP Gaul, CJ Wallace, RN Auer, TC Fong 'MR findings in methanol intoxication' *AJNR* 1995;16(9):1783-1786
2. Soysal D, Yersal Kabayegit O, Yilmaz S, Tatar E, Ozatli T, Yildiz B, Ugur O 'Transdermal methanol intoxication: a case report.' *JBR-BTR*. 2006 Nov-Dec;89(6):315-7.
3. Baselt RC. *Disposition of Toxic Drugs and Chemicals in Man*, 6th eds. Biomedical Publications, Foster city, CA, 2002, pp 652-655.
4. A Downie, T.M. Khattab, M.I.A. Malik, N. Samara 'A case of percutaneous industrial methanol toxicity' *Occupational Medicine* 1992;vol:42:47-49
5. Hsieh FY, Leu TM, Chia LG 'Bilateral putaminal necrosis caused by methanol poisoning: a case report.' *Zhonghua Yi Xue Za Zhi (Taipei)*. 1992 ;49(4):283-8.
6. S. Sefidbakht & A. R. Rasekhi, K. Kamali, A. Borhani Haghighi, A. Salooti, A. Meshksar, H. R. Abbasi, M. Moghadami, S. A. Nabavizadeh

'Methanol poisoning:acute MR and CT findings in nine patients' Diagnostic Neuroradiology ,2007,vol: 49;427-435  
7. Gladys Martin-Amat et al, 'Methyl Alcohol Poisoning II. Development of a Model for Ocular Toxicity in Methyl Alcohol Poisoning Using the Rhesus Monkey' Arch Ophthalmol,1977,vol:95,pp:1847-1850  
8. Koopmans RA,Li DK,Paty DW 'Basal ganglia lesions in methanol poisoning.MRappearance'. JCAT 1998;12(1):168-169  
9. Barceloux DG, Bond GR, Krenzelok EP, Cooper H, Vale JA, ' American Academy of Clinical Toxicology Ad Hoc

Committee on the Treatment Guidelines for Methanol Poisoning' J American Academy of Clinical Toxicology practice guidelines on the treatment of methanol poisoning. Toxicol Clin Toxicol. 2002;40(4):415-46.  
10. K. E. Hovda, O. H. Hunderi, A.-B. Tafjord, O. Dunlop, N. Rudberg, D. Jacobsen 'Methanol outbreak in Norway 2002-2004: epidemiology, clinical features and prognostic signs' Journal of Internal Medicine 2005;258 (2) :181–190  
11. Kruse JA. 'Methanol poisoning.' Intensive Care Med. 1992;18(7):391-7.

**Author Information**

**Derya YAVUZ DEM?RAY**

Neurology Department, Cerrahpaşa Medicine Faculty

**Derya ULUDÜZ**

Neurology Department, Cerrahpaşa Medicine Faculty

**Baki GÖKSAN**

Neurology Department, Cerrahpaşa Medicine Faculty