

Cystic Pathology Of The Abdominal Wall After Laparotomy: A Three-Case Report

J Carvajal Balaguera, S Oliart Delgado de Tórres, M Martín García — Almenta, V Jiménez Carneros, J Camuñas Segovia, L Peóla Gamarra, P Fernández Isabel, S Viso Ciudad, P Gómez Maestro, A Prieto Sánchez, C Cerquella Hernández

Citation

J Carvajal Balaguera, S Oliart Delgado de Tórres, M Martín García — Almenta, V Jiménez Carneros, J Camuñas Segovia, L Peóla Gamarra, P Fernández Isabel, S Viso Ciudad, P Gómez Maestro, A Prieto Sánchez, C Cerquella Hernández. *Cystic Pathology Of The Abdominal Wall After Laparotomy: A Three-Case Report*. The Internet Journal of Surgery. 2005 Volume 8 Number 1.

Abstract

Cystic pathology of the abdominal wall after laparotomy is a little known and rarely diagnosed condition, in spite of its definite clinical setting and treatment. It is very important for to the surgeon, as it may be mistaken frequently for incarcerated ventral hernia, postoperative abdominal haematoma or abdominal wall tumours. We present three patients with cystic mass at the previous laparotomy site. The duration of their symptoms ranged from 3 to 12 months. The patients underwent surgical exploration and excision of the mass, which was revealed by histology to be a unspecific cystic tumour without evidence of malignancy. The pathogenesis, clinical features, diagnostic examinations and treatment are discussed.

INTRODUCTION

Abdominal wall cyst (AWC) of surgical scar after laparotomy is a rare late complication. Its may be misdiagnosed and incorrectly treated. Although not reported frequently, this pathology should be recognized by the surgeons. A mass in the abdominal wall over a previous laparotomy scar raises the suspicion of incisional hernia. However, other diagnoses, such cystic endometriosis, organized postoperative haematoma, suture granuloma, organized seroma, benign tumour and malignant deposition, are also possible ^{1,2}.

We herein report three cases of cystic mass over laparotomy scar observed and treated in our service. The authors take this opportunity to review the underlying pathogenic mechanism, clinical manifestations and therapeutic procedures.

CASES REPORTS

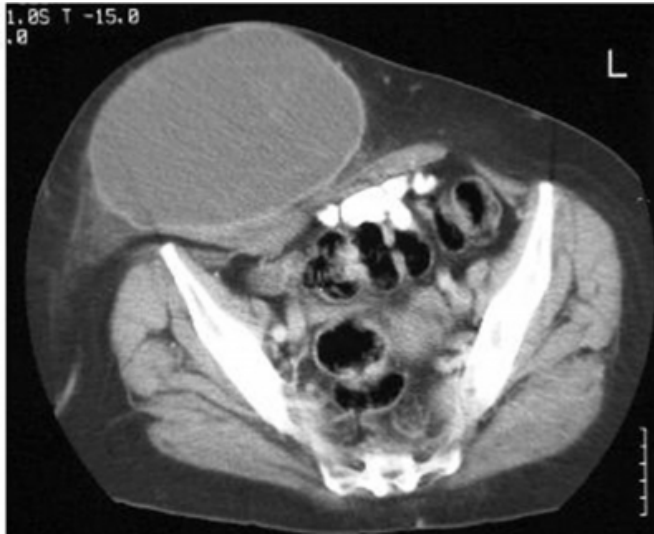CASE 1

A 56-year-old woman with history of open bariatric surgery and four caesareans. She consulted for presenting an asymptomatic progressive growing a tumour of three months

of evolution. On examination, the patient had a pendulous anterior abdomen wall and a tender mass between her scar and her umbilicus. The mass was not reducible and the size of that mass could not be determined because of the obesity of the patient. The laboratory analyses did not show alterations. The abdominal computed tomography (CT) scan (Fig. 1), revealed an umbilical cystic tumour, and that was not infiltrating muscular fascia.

Figure 1

Figure 1: Contrast-enhanced CT scan show large fluid density mass lesion in relation to previous laparotomy scar.



Fine needle aspiration (FNA), was negative for malignancy. She was diagnosed as a AWC and surgical repair was recommended. She underwent an operation when an encapsulated mass was found in the midline, between anterior to muscle aponeurosis and subcutaneous tissue. The mass did not penetrate to the muscle aponeurosis plane. Local excision of the cystic mass and dermolipectomy was performed without any difficulty and was not necessary to utilize any prosthesis since the aponeurosis was harmless. The histology report confirmed the diagnosis of a unspecific cystic tumour without evidence of malignancy (Fig. 2 and 3). The postoperative recovery was uneventful, and the patient had a full recovery, with a follow up of twelve months.

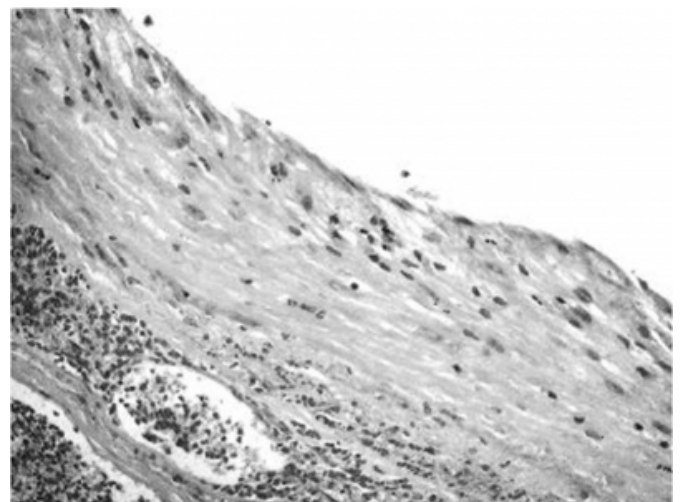
Figure 2

Figure 2: Operative photo showing a cystic mass. The greatest dimension is 12 cm, and the capsule of the specimen had a reddish appearance with central gelatinous aspect and a yellowish appearance.

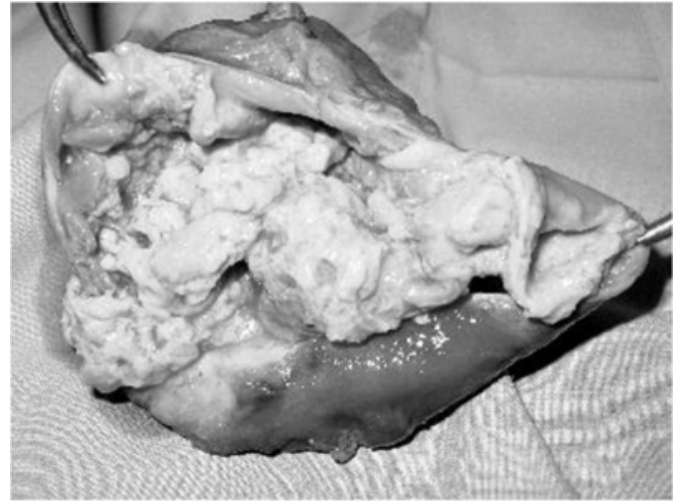

Figure 3

Figure 3: Microscopic aspect of cyst with H&E, 4 x 10 staining: Cyst wall showing conjunctive tissue to laminate very vascularized.



CASE 2

A 61-year old female was referred by her family physician for surgical consultation with a one year history of pain and abdominal mass. Her surgical history was a total hysterectomy for ovary carcinoma through of an infra-umbilical middle incision. Her abdominal exploration showed a mass, mobile and not reducible, located at the infraumbilical midline scar. Routine laboratory analyses did not showed alterations. The abdominal CT scan (Fig 4), showed a cystic mass of 17 cm of diameter located between

the cellular subcutaneous tissue and the muscular fascia of the abdominal wall. AWC was suspected and operative treatment was recommended. Intraoperatively, an encapsulated mass was found anterior to the right rectus abdominis muscle fascia. The local excision of tumour and abdominoplasty were performed and the histology report confirmed the diagnosis of a nonspecific cystic tumour, after to discard the presence of foreign body in the whole surgical extirped piece (Fig. 5). The patient had an uneventful postoperative course and was discharged 7 days after of the surgical intervention. She no recurrences have been diagnosed after twenty five months of follow up.

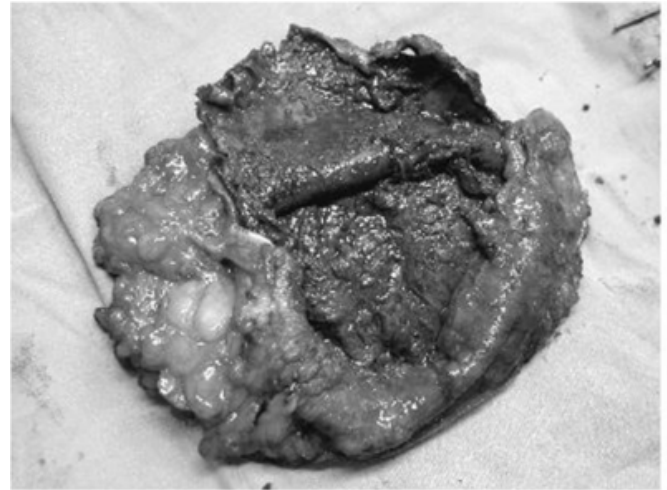
Figure 4

Figure 4: Abdominal CT scan showed a cystic mass over the rectus abdominis muscle aponeurosis but invading the posterior aspect of the subcutaneous tissue.

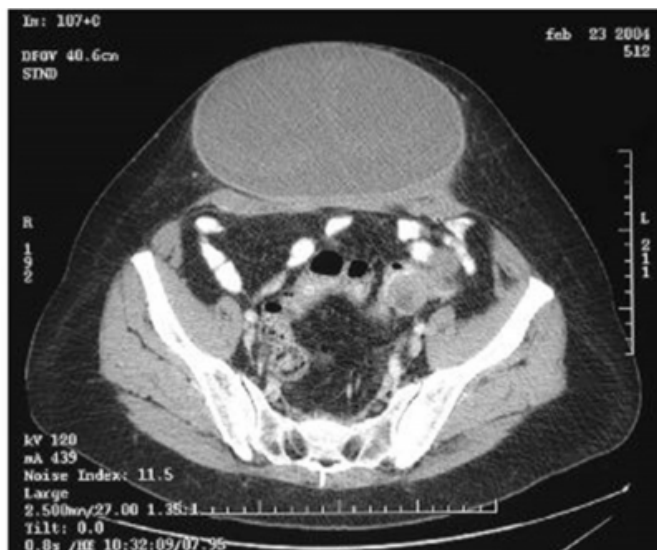

Figure 5

Figure 5: Operative photo showing the resected cystic mass. The greatest dimension is 17 cm, and the capsule of the specimen had a yellowish appearance with central necrosis with a brown appearance.



CASE 3

A 56-year-old woman with precedents of open bariatric surgery, consulted for presenting an asymptomatic abdominal mass under the laparotomy scar of six months of evolution, and progressive growth. On examination of the abdomen, a nontender mass and not reducible with ill-defined borders was felt in the epigastrium and pendulous anterior abdominal wall. The laboratory analyses did not show alterations. The abdominal CT scan (Fig 6), revealed a hypodense mass of the 10x8 cm of diameter. Fine needle aspiration was negative for malignancy. The lesion The lesion was extirpated totally without any difficulty and was not necessary to use any mesh because the aponeurosis of the right muscles didn't present any lesion (Fig. 7). Histopathology revealed a cystic lesion. No evidence of granulomatous pathology or malignancy was found in the whole surgical extirped piece. The patient had an uneventful postoperative course. She is still asymptomatic after forty five months of follow up.

Figure 6

Figure 6: Abdominal CT scan revealed a cyst mass arising from the medial aspect of the abdominal wall aponeurosis.

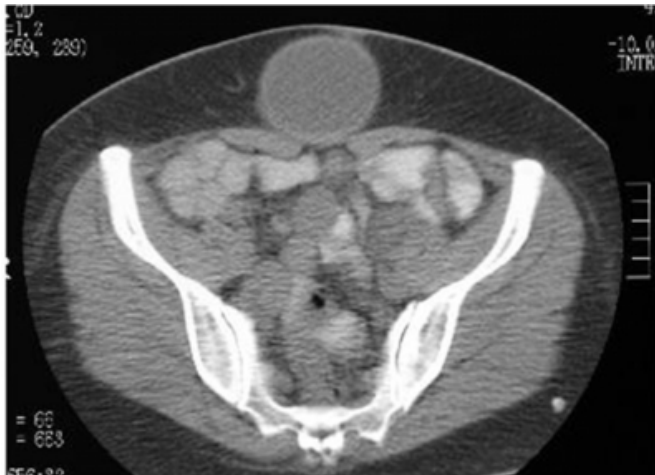
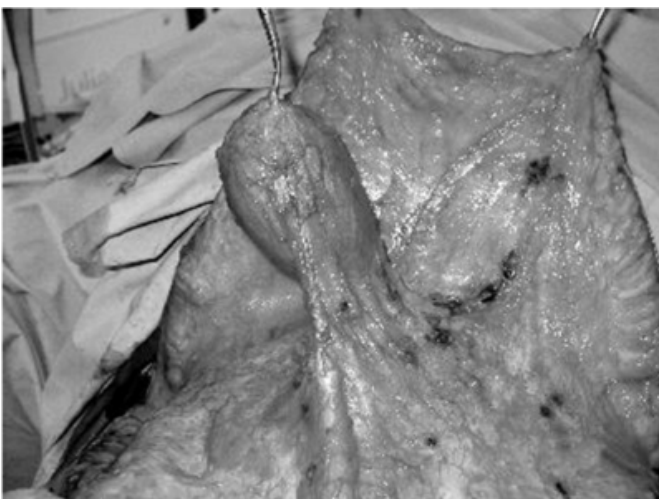
Figure 7

Figure 7: Intraoperative photo showed a cystic mass.



DISCUSSION

The surgical wound after abdominal surgery can originate a significant and varied morbidity, as incisional hernia, haematoma, seroma, inflammatory processes, endometriosis and others pathologies less frequent.

Persistence of cavities between the muscle layer and the subcutaneous tissue, after laparotomy, encourages fluid collection, which in turn causes haematomas, seromas and abscesses. These complications can turn into cystic formations or masses that can simulate a tumour of the abdominal wall, if they are not readily solved³. For this reason, a careful surgical technique, careful haemostasis and placement of suction drains in the subcutaneous tissue is recommended, principally in obese patients or when a

dermolipectomy or abdominoplasty, is associated, to avoid fluid collection¹. Some authors^{2,4}, have described that the use of biological adhesives improve the results of surgical repair of large abdominal incisions after laparotomy and associated dermolipectomy, because adhesive (fibrin glue) allows immediate fixation, which prevents haematomas, seromas and infections in a 50%, lessens the severity of complications which intern shortens hospital stay by 50%, and lessens the amount of postoperative wound care needed.

The described cases until now are related to the presence of meshes used during the closing of the laparotomy, however obesity is considered the main risk factor for local morbidity after laparotomy⁵. Obesity was an important factor in our group. We have not observed any foreign body associated to none of our cases. Others risk factor are local infection, absence of drainage, contaminated surgery, amount of abdominal panniculus, surgical wound size and the number of days of drainage implanted¹.

Management of patients with a suspected AWC, after laparotomy, should include a careful history, physical examination, routine laboratory investigation, radiological tests, and serological screening to rule out any parasitic cyst. The AWCs are generally asymptomatic or cause non-specific symptoms. Symptoms appear when the cysts enlarge sufficiently to cause pain or become palpable. The two most common clinical features found are dull pain in the abdominal wall and a palpable mass. Routine laboratory investigations are generally helpful. Anaemia may be found if there has been significant intracystic bleeding, leukocytosis may be found if the cyst is infected, and eosinophilia may be found in a parasitic. A hydatid cyst may be positive for echinococcal serology.

Fine needle aspiration (FNA) is also very useful in the management of large seromas or haematomas, however tissue manipulation can promote infection. FNA can confirm the diagnosis and eliminate the doubt of possible malignancy. FNA or percutaneous biopsy should be avoided when endometriosis is suspected to avoid further transportation of endometrial tissue along the biopsy tract. FNA should be also avoided when hydatid cyst is suspected to evitate parasite dissemination and anaphylaxis⁶.

Radiological test may be used to rule out incisional hernia or other associated pathology when making the preoperative diagnosis. With the wider use of ultrasound for various abdominal symptoms, the detection of AWC has increased, although CT is the method of choice for identification of the

abdominal wall masses, assess for local spread and exclude hernia. On CT, the cysts usually present as round low-density masses with smooth borders and a thin wall. On ultrasound an AWC will most likely present as a vesicular hypo echoic mass and can differentiate between a cystic or solid mass. Magnetic resonance imaging (MRI) helps with the differential diagnosis with other cystic pathologies ⁷.

The differential diagnosis for AWC after laparotomy include: Incarcerated postoperative scar hernia ², abdominal wall endometriomas or cystic endometriosis ^{8,9,10,11}, organized haematoma or seroma ¹², inflammatory lesions (abscess, omphalitis, granulomas) ^{13,14}, mature bone metaplasia ¹⁵, urachal cyst ¹⁶, hydatidic cyst ¹⁷, soft tumors of the abdominal wall (neuroma, hemangioma, lipoma, mixoma, leiomioma) ^{18,19}, primary sarcoma ²⁰, malignant fibrous histiocytoma ²¹, desmoids tumour ²² and metastatic carcinoma ¹⁸.

Ventral hernia is the first diagnosis to suspect when a mass appears on the surgical scar during the late postoperative period, however other benign and malignant processes have to be kept in mind for differential diagnosis.

The inflammatory processes of the surgical wound after abdominal surgery are relatively frequent, so they must be suspected in the presence of a mass on the surgical incision. The clinical history and radiological tests are very important in the differential diagnosis ^{13,14}.

Organized postoperative haematoma or seroma of the abdominal wall are less frequent, but difficult to diagnose due to their similarity with other pathologies ¹².

Cystic endometriosis of the abdominal wall following obstetric or gynaecological surgery is a rare condition that may confuse the differential diagnosis with other abdominal inflammatory or tumoural processes. The most common presentation is an abdominal wall mass associated with pain during the menstrual cycle and diagnosis is only confirmed by histology. A diagnosis of endometrioma must be considered when a scar mass is present in fertile women with antecedents of gynaecological or obstetric surgery. The medical history is extremely useful in the differential diagnosis ^{10,11,23}.

Tumour implants on the surgical wound after abdominal surgery for malignant pathology, it is a known fact in the surgical practice. Though the frequency is less than 1% ²⁴, it must be discarded in the presence of a mass over the surgical scar.

The hydatidic cyst of the abdominal wall is an exceptional entity, however it can appear due to dissemination after surgery of hydatidic abdominal disease. The clinical history, image tests and serology orientate the diagnosis ¹⁷.

Surgical excision of AWC is the treatment of choice. We have not had any difficulty to extirpate these lesions and we have not used any mesh because the abdominal wall was not injured. The surgery is necessary to investigate the aetiology, to discard malignancy and to avoid complications.

Indications for surgery are patients symptoms, size of the lesion, haemorrhage, and possibility of malignancy.

CONCLUSION

In conclusion, the cystic lesions of the abdominal wall gathered in this series, they are characterized for appearing in obese patients, and with antecedents of a abdominal surgery in the months precedents. The image tests are very important to confirm the diagnosis, to study the location and to evaluate the affection of neighbouring structures. The surgery is necessary to investigate the aetiology, to discard malignancy and to avoid complications. In the greater part of the cases, the result of the histological study is unspecific.

References

1. Haritopoulos KN, Labruzzo C, Papalois VE, Hakim NS. Abdominoplasty in a patient with severe obesity. *Int Surg* 2002;87:15-18.
2. Fernández R, García J, Ortega P, Marin F, Ruiz J, Limones M. Tissucol application in dermolipectomy and incisional hernia repair. *Int Surg* 2001;86:240-245.
3. Vestweber KH, Lepique F, Haaf F, Loratz M, Reink A. Results of recurrent abdominal wall hernia repair using polypropylene mesh. *Zentralb Chir* 1997;122:885-888.
4. Chevrel JP, That AM. The use of fibrin glues in the surgical treatment of incisional hernias. *Hernia* 1997;1:9-14.
5. Hesselink VJ, Luijendijk R, de Wilt JH, Heide R, Jekel J. An evaluation of risk factors in incisional hernia recurrence. *Surg Gynecol Obstet* 1993;176:228-234.
6. Matthes G, Zabel D, Nastala CL, Shestak KC. Endometrioma of the abdominal wall following combined abdominoplasty and hysterectomy: case report and review of the literature. *Ann Plast Surg* 1998;40:672-675.
7. Goodman P, Raval B. CT of the abdomen wall. *AJR* 1990;154:1207-1211.
8. Santos JC, Vidal J, Candón J, Royo A, Carranza G. Endometriosis de la pared abdominal tras cirugía ginecológica. *Clin Invest Gin Obst* 2003;30:235-237.
9. Hidalgo LA, Heredia A, Fontava MJ, Badía JM, Suñol X. Endometriomas de pared abdominal: aspectos diagnósticos. *Cirugía Española* 2001;70:34-37.
10. Bachir J, Bachir N. Scar endometrioma: Awareness and prevention. *Wisconsin Med J* 2002;101:46-49.
11. Roncoroni L, Costi R, Violi V, Nunziata R. Endometriosis on laparotomy scar. A three-case report. *Arch Gynecol Obstet* 2001;265:165-167.
12. Soria-Aledo V, Carrasco-Prats M, Flores-Castro B, Aguilar-Jiménez J. Hematoma de la vaina de los rectos. Las pruebas de imagen evitan laparotomías innecesarias. *Cirugía*

Española 2002;1:330-332.

13. Perea J, Turégano F, Pérez M, Medina J, Rodríguez M, Sanz M. Actinomicosis primaria de pared abdominal con peritonitis asociada. *Cirugía Española* 2001;70:207-208.

14. Fernández C, Cañada J. Absceso de pared abdominal por *Eikenella corrodens*. *SEMERGEN* 2004;30:580-582.

15. Daoud RA, Watkins MJ, Brown G, Carr N. Mature bone metaplasia in abdominal wall scar. *Postgrad Med J* 1999;75:226-227.

16. Omar R, Marqueta JM, Pérez F, Llobet M. Tumores de pared abdominal como diagnóstico diferencial con masas anexiales. A propósito de dos casos. *Clin Invest Gin Obst* 2001;28:436-438.

17. Prousalidis J, Tzardinoglou K, Sgouradis L, Katsohis C, Aletras H. Uncommon sites of hydatid diseases. *World J Surg* 1998;22:17-22.

18. Stojadinovic A, Hoos A, Karpaff H, Leung D, Antonescu C, Brennan H. Soft tissue tumors of the abdominal wall. *Arch Surg* 2001;136: 335-338.

19. Martín J, Manuel J, Alonso J, Alonso Gayon J. Mixoma intramuscular en pared abdominal. *Cirugía Española*

2003;73:188-190.

20. Omer K, Kadri A, Emin E, Orguz D, Gokan G, Ayse K. Anterior abdominal wall synovial sarcoma: A rare presentation. *Am J Clin Oncol* 2005;28:323-325.

21. García M, Morales D, Seco I, Martín J, Arce F, Casanova D. Histiocitoma fibroso maligno de pared abdominal. *Rev Oncol* 2003;44-46.

22. Manuel C, Alonso J, Alonso L, Fernández MJ, Barcena JM. Tumor desmoide de la pared abdominal. Reconstrucción con mioplastia y doble malla. *Cirugía Española* 2001; 69:523-524.

23. Wasfie T, Gómez E, Seon S, Zado B. Abdominal wall endometrioma after caesarean section: A preventable complication. *Int Surg* 2002;87:175-177.

24. Veldkamp R, Kuhry E, Hop W, Jeekel J, Kazemier G, Bonjer HJ, Haglind E, Palman L, Cuesta M, Msika S, Morino M, Lacy A. Laparoscopic surgery versus open surgery for colon cancer: short-term outcomes of a randomised trial. Colon cancer Laparoscopic or open resection study group (COLOR). *Lancet Oncol* 2005;6:477-484.

Author Information

J. Carvajal Balaguera

Surgeon assistant, Service of General and Digestive Surgery, Hospital Central Cruz Roja

S. Oliart Delgado de Tórres

Surgeon assistant, Service of General and Digestive Surgery, Hospital Central Cruz Roja

M. Martín García — Almenta

Surgeon assistant, Service of General and Digestive Surgery, Hospital Central Cruz Roja

V. Jiménez Carneros

Surgeon assistant, Service of General and Digestive Surgery, Hospital Universitario de Getafe

J. Camuñas Segovia

Surgeon assistant, Service of General and Digestive Surgery, Hospital Central Cruz Roja

L. Peóla Gamarra

Surgeon assistant, Service of General and Digestive Surgery, Hospital Central Cruz Roja

P. Fernández Isabel

Surgeon assistant, Service of General and Digestive Surgery, Hospital Central Cruz Roja

S. Viso Ciudad

Surgeon assistant, Service of General and Digestive Surgery, Hospital Central Cruz Roja

P. Gómez Maestro

Surgeon assistant, Service of General and Digestive Surgery, Hospital Central Cruz Roja

A. Prieto Sánchez

Surgeon assistant, Service of General and Digestive Surgery, Hospital Central Cruz Roja

C.M. Cerquella Hernández

Chief of Service, Service of General and Digestive Surgery, Hospital Central Cruz Roja