

# Time Course of Reversible Cerebral Segmental Vasoconstriction (Call's Syndrome): Case Report of a 3 Year Follow-up With TCCS

S Zipper, G Sell

## Citation

S Zipper, G Sell. *Time Course of Reversible Cerebral Segmental Vasoconstriction (Call's Syndrome): Case Report of a 3 Year Follow-up With TCCS*. The Internet Journal of Neurology. 2002 Volume 2 Number 1.

## Abstract

A 34 year old woman without a history of migraine experienced acute and severe left-sided throbbing headache followed by remitting periods of right-sided hemiparesis. MRI revealed ischemic stroke of the left lenticulostriate artery (LA). Transcranial color-coded duplexsonography (TCCS) studies and angiography showed cerebral segmental vasoconstriction in different vessels. Therapy with iv heparin, nimodipin and dexamethasone was begun followed by azathioprine over 15 months. There was full and persistant clinical recovery on day 6 after the onset of symptoms. TCCS follow-up showed a slow decline of elevated blood flow velocity (BFV) in both middle cerebral arteries (MCA) over a period of 12 months with persistant normal values over another 2.5 years.

## CASE REPORT

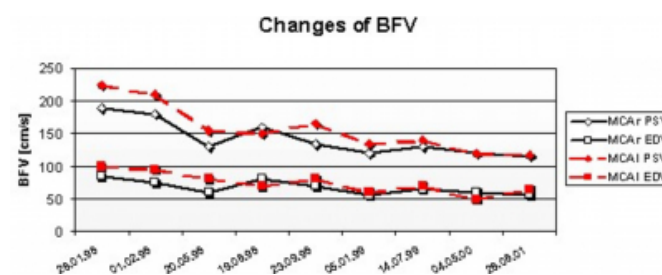
A 34 year old obese woman (92 kg, 155 cm) without a history of migraine suddenly experienced severe left-sided throbbing headache which was followed by a right-sided hemiparesis minutes afterward. She had no history of cigarette smoking, hypertension, hypercholesterinemia, diabetes or of using illicit drugs nor diet pills. CT scan on admission was non-diagnostic. SAH was ruled out by lumbar puncture which was non-diagnostic (4/3 cells, protein 37 mg/dl, IgG 3.25 mg/dl, oligoclonal band neg.). TCCS on admission revealed elevated BFV in both MCA (Fig. 1). Echocardiography and extracranial duplexsonography did not show any signs of atherosclerotic changes and no other abnormalities. IV therapy with heparin and nimodipine was started. During the following hours severity of her hemiparesis varied greatly. On the second hospital day MRI showed ischemic infarction of the left lenticulostriate area. There was full clinical recovery on day 6 after the onset of symptoms despite of persistence of elevated BFVs in both MCA.

**Figure 1**

Figure 1: Changes of peak-systolic and end-diastolic BFV in both MCA

28.1	▶	13.2	- iv Heparin, Nimodipine
4.2	▶	23.5	- Dexamethasone p.o.
13.2	▶	23.5	- Dalteparin s.c.
12.3	▶	14.7	99 - Azathioprin
12.3	▶		Acetylsalicylic acid

**Figure 2**



Laboratory Data: Normal routine parameter were found. There was no F V Leyden deficiency nor hyperhomocystinemia. Antiphospholipid Ab, ANA, anti-double-stranded DNA Ab, anti-Sm, anti-SS-A, anti-SS-B, anti-Scl, pANCA, cANCA and AMA were negative. IgG 1370 (700-1600), IgA 408 (70-400), IgM 112 (40-230), / : 1.94 (1.29-2.61), and Borrelia burgdorferi Ab neg.. A bone specimen was non-diagnostic.

DSA showed multiple sites of segmental vasoconstriction in

different sized vessels. Oral therapy of 16 mg dexamethasone was started on hospital day 8. After clinical stabilization iv heparin and nimodipine were stopped, and anticoagulation was switched to subcutaneous Dalteparine 2x5000 I.U. for 4 months followed by 100 mg acetylsalicylic acid on a daily ongoing basis. After 6 weeks dexamethasone was tapered and subsequently substituted by 150 mg azathioprine, which lasted for the subsequent 16 months. TCCS follow-up in the following year showed a significant decline of BFV, and finally normalization within 12 months. BFV has remained normal over a 2.5 years period. (Fig. 1). There has been no recurrence of headache nor any neurological deficit.

One year before admission the patient had an episode of high fever of unknown origin. Subclinical hyperthyroidism was found then, two years after the stroke Hashimoto's thyroiditis was diagnosed and treatment with 75ug Levothyroxine was started.

## DISCUSSION

Segmental vasoconstriction of cerebral arteries is a well known but poorly understood phenomenon <sup>1</sup>. Migraine <sup>2, 8, 9</sup>, traumatic vessel injury <sup>10</sup> and intoxication with sympathomimetic drugs <sup>11</sup> can precipitate vasoconstriction, suggesting various mechanical and chemical stimuli capable of causing vasoconstriction. In 1988 Call et al. described 4 patients with RCSV who presented similarly with severe headache, fluctuating or recurring motor or sensory deficits, and angiographical findings of multiple vasoconstrictions of vessels originating from the circle of Willis or smaller cortical arteries <sup>3</sup>. Despite similar clinical and angiographical findings, various cases with different associated conditions were described: post partum angiopathy <sup>6</sup>, vasculitis <sup>8</sup>, post endarterectomy <sup>5, 7</sup>, during Guillain-Barré neuropathy <sup>3</sup>, and in migrainous infarction <sup>4</sup>.

Women seem to be more often affected than men, suggesting a hormonal influence. In most cases the clinical course is benign, and no relapses are seen after treatment with steroids, anticoagulation and vasodilation - however resolution may be spontaneous.

In the case under discussion we found significant elevated BFV in both MCA on admission which slowly returned to normal values over a period of twelve months during immunosuppressive therapy. (Fig.1) Over another period of 2.5 years, BFV remained normal. No trigger or typical associate condition could be found. Unresolved questions

are, whether the normalization of BFV was spontaneous or due to immunosuppressive therapy, and whether HD was an associated condition or just coincidental. During acute phase the patient presented with stroke and headache. Though a subclinical hyperthyroid condition was found, clinical signs consistent with HE (i.e. seizures, psychiatric abnormalities, decrease of consciousness and myoclonus) definitely were not seen, which makes coincidence by chance much more likely. On the other hand stroke like episodes are known to occur in HE, too. MRI shows white matter lesions in HE but not strokes and the CSF in most cases is abnormal <sup>12</sup>. Angiographic abnormalities reflecting large vessel disease have not been reported in HE.

The etiology of vasoconstriction in Call's syndrome has not been established. There is acute onset of symptoms accompanied by significant elevated BFV, and as we could show with serial TCCS investigation a very slow decline in BFV while clinical signs have already resolved. Further systematical studies are needed to answer the question, what causes headache and stroke in Call's syndrome.

## CORRESPONDENCE TO

Stephan G. Zipper M.D. Department of Neurology and Clinical Neurophysiology Katharina-Kasper-Kliniken gGmbH Richard-Wagner-Str. 14 D-60318 Frankfurt/Main Tel: +49-69-1563-581 Fax: +49-69-1563-534 e-Mail: sgzipper@neurosonology.de

## References

1. Heros R, Zervas N, Varsos V. Cerebral vasospasm after subarachnoid hemorrhage: an update. *Ann Neurol* 1983; 14:599-608.
2. Caplan L. Migraine in posterior circulation disease: diagnosis, clinical findings, and management. Boston, 1996.
3. Call G, Fleming M, Sealfon S, Levine H, Kistler J, CM F. Reversible cerebral segmental vasoconstriction. *Stroke* 1988; 19:1159-1170.
4. Martin-Araguez A, Fernandez-Armayor V, Moreno-Martinez J, et al. Segmental arteriographic anomalies in migrainous cerebral infarct. *Rev Neurol* 1997; 25:225-9.
5. Lopez-Valdez E, Chang H-M, Pesin M, Caplan L. Cerebral vasoconstriction after carotid surgery. *Neurology* 1997; 49:303-304.
6. Modi M, Modi G. Case reports: postpartum cerebral angiopathy in a patient with chronic migraine with aura. *Headache* 2000; 40:677-81.
7. Brick J, Dunker R, Gutierrez A. Cerebral vasoconstriction as a complication of carotid endarterectomy. Case report. *J Neurosurg* 1990; 73:151-3.
8. Serdaru M, Chiras J, Cujas M, Lhermitte F. Isolated benign cerebral vasculitis or migrainous vasospasm? *Journal of Neurology, Neurosurgery, and Psychiatry* 1984; 47:73-76.
9. Dukes H, Vieth R. Cerebral arteriography during migraine prodrome and headache. *Neurology* 1964; 14:636-9.
10. Khodadad G. Middle cerebral artery embolectomy and

prolonged widespread vasospasm. Stroke 1973; 4:446-450.  
11. Rumbaugh c, Bergeron R, H G, al. e. Cerebral  
angiographic changes in the drug abuse patient. Radiology

1971; 101:335-344.  
12. Seipelt M, Zerr I, Nau R, et al. Hashimoto's encephalitis  
as a differential diagnosis of Creutzfeld-Jacob disease. J  
Neurol Neurosurg Psychiatry 1999; 66:172-176.

**Author Information**

**Stephan G. Zipper**

Department of Neurology and Clinical Neurophysiology, Katharina-Kasper-Kliniken gGmbH

**Gerhard Sell**

Medical Department, St. Katharinenkrankenhaus GmbH