

Neuroblastoma In An Adult

A Manchanda, U Manchanda

Citation

A Manchanda, U Manchanda. *Neuroblastoma In An Adult*. The Internet Journal of Internal Medicine. 2009 Volume 9 Number 1.

Abstract

Neuroblastoma is an uncommon malignancy in adult life as compared with childhood. Considering the location of the primary neuroblastomas and the fact that in some instances convincing documentation to support a diagnosis is lacking, these tumors can be diagnosed as other small, round-cell tumors, such as primitive neuroectodermal tumor (PNET)/Ewing's sarcoma (ES) and olfactory neuroblastoma. The present case highlights a stage 4 neuroblastoma in a 54 year old female. Adults with neuroblastoma have significantly worse outcome than children. This may be due to tumor biology, more virulent clinical course, or possibly due to the fact that adults are less sensitive or have poor tolerance to pediatric chemotherapy regimens.

INTRODUCTION

Neuroblastoma is the second most common solid extracranial neoplasm of infancy and childhood. More than 90% of cases of this tumor occur in patients younger than 10 years; however, it has been reported in adults, though rarely.^{1,2,3,4,5} The locations of primary neuroblastomas in adults are similar to the locations in younger patients, with the abdomen and pelvis being the most common areas of occurrence, followed by the thorax, head or neck, and extremities. However, considering the location of the primary neuroblastomas and the fact that in some instances convincing documentation to support a diagnosis is lacking, these tumors can be diagnosed as other small, round-cell tumors, such as primitive neuroectodermal tumor (PNET)/Ewing's sarcoma (ES) and olfactory neuroblastoma. In addition, because of the rarity of adult neuroblastoma (ANB), little is known about its histologic and immunohistochemical features.⁶

Neuroblastoma is characterized by its variable evolution. Most localized tumours have an excellent prognosis when treated by surgical resection, with or without chemotherapy. Infants less than 1 year have better prognosis than children regardless of tumour stage. Some of these tumours may even show spontaneous regression (localized or stage IVs). In contrast, approximately 60% of children with neuroblastoma present metastatic disease at diagnosis with poor outcome despite intensive treatment protocols. The clinical diversity correlates with numerous biological and molecular factors. Regardless of patient's age and stage of disease, amplified expression of MYCN oncogene is the worst paraclinical

prognostic factor. Other variables associated with poor survival include elevated serum ferritin, lactate dehydrogenase and neuron-specific enolase, lack of CD44 expression and unfavourable histologic features at diagnosis.⁷

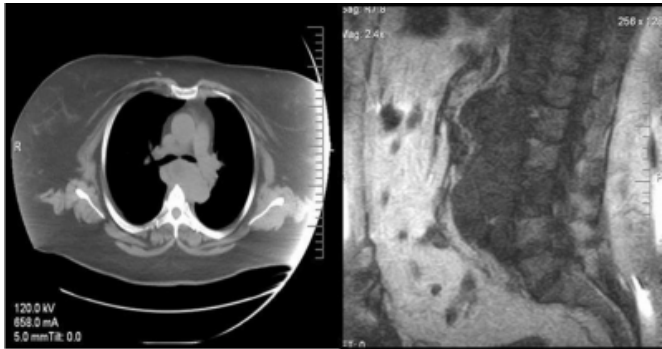
Herein is present a case of an adult female who was diagnosed with Neuroblastoma.

CASE REPORT

A 54 year old female presented with back pain in the L3-L4 region which radiated on to the right leg. Past medical history was significant for stage 1b endometrial cancer on which hysterectomy was done several years ago. An MRI of the lumbo sacral spine revealed an extra peritoneal mass overlying L2-L4 with lytic focal involvement of the body of L3. She also complained of respiratory distress which on CT presented (Figure 1a) as an extensive lymphadenopathy in the thoracic inlet, mediastinum and retroperitoneum. A hypermetabolic midline mass in the medial left supraclavicular fossa region was seen extending into the left infraclavicular fossa region and paralaryngeal region inferiorly down to the S1 level (Figure 1b).

Figure 1

Figure 1a: CT chest showing mediastinal mass pressing on trachea. Figure 1b: MRI of lumbosacral spine showing retroperitoneal mass of neuroblastoma



Differential diagnosis included lymphoma or a metastatic disease. Laboratory findings revealed an elevated vanillylmandelic acid level (VMA). Fine needle aspiration biopsy of the left supraclavicular lymph node showed a poorly differentiated neoplasm with extensive necrosis. The patient was scheduled for lymph node resection via mediastinoscopy and was started on Epidural steroid injection (ESI) for back pain and Neurontin 300 mg qhs titrate.

The histopathology report revealed a high grade anaplastic small blue cell neoplasm with neuronal differentiation. Sheets of small round, blue cells with hyperchromatic irregular nuclei and a scanty cytoplasm were seen (Figure 2,3).

Figure 2

Figure 2: Sheets of small round blue cells in a fibrocellular connective tissue stroma.(H&E, 10X)

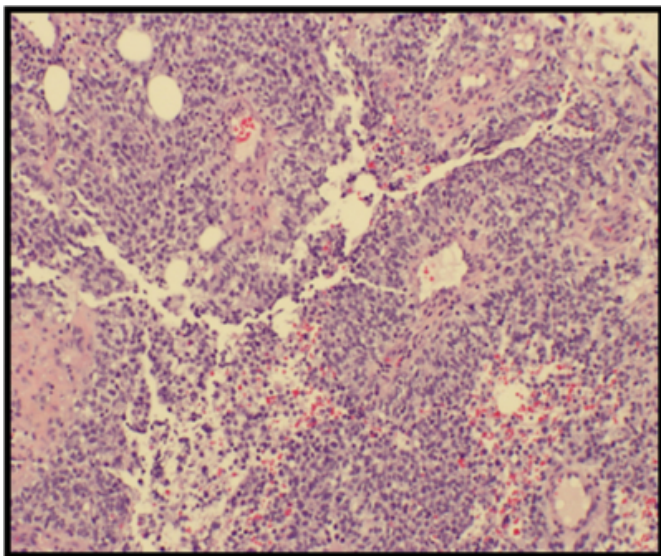
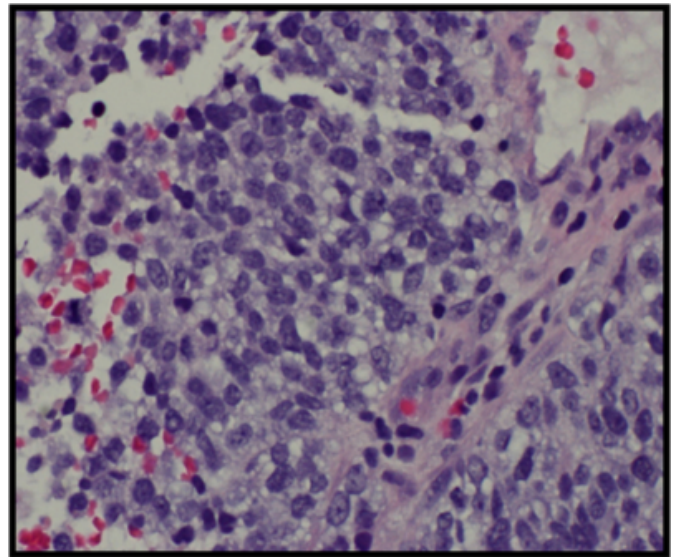


Figure 3

Figure 3: Poorly differentiated neuroblastoma, with scattered neuroblasts in a background of light pink, fibrillary neuropil. (H&E, 40X)



The findings were consistent with adult variant metastatic neuroblastoma of Stage 4. Since this malignancy is rare in adults, a palliative radiation therapy for pain control was started upon. During her hospitalization, the patient developed urinary tract infection and acute kidney injury, anuric renal failure, shock liver, atrial fibrillation with rapid ventricular rate and finally passed away.

DISCUSSION

Neuroblastoma is a malignant tumour of neural crest cells which give rise to the sympathetic nervous system. It is a childhood tumour occurring in infants and young children (5 years and less in 90% of all cases) that accounts for 8 to 10% of pediatric cancers. It may arise at any site in the sympathetic nervous system, most commonly in the abdomen. At diagnosis, the tumour may be limited to a single organ, locally or regionally invasive, or widely disseminated. Bone, bone marrow, liver and skin are among the most common metastatic sites. Disease-free survival ranges from 95% for some localized tumours to 30% for metastatic disease in children over 1 year.⁷

Clinical symptoms depend on the location of the primary tumour, the locoregional and metastatic dissemination. Symptoms are frequent but non-specific. About 60% of primaries are localized in the abdomen. They may be associated with palpable mass, digestive problems, discomfort and pain. Thoracic neuroblastomas ($\approx 20\%$) are often diagnosed coincidentally by chest X-rays. Respiratory

distress, dysphagia and circulatory problems may be observed in upper thoracic tumours. Cervical location ($\approx 5\%$) often shows palpable mass and Horner's syndrome. Pelvic neuroblastoma ($\approx 5\%$) may cause constipation, voiding urine and oedema. In about 10%, the localization of the primary remains unknown.^{7,8}

Clinical symptoms in metastatic disease also vary widely. In infants, metastatic involvement of the liver (Pepper syndrome) may result in prolonged jaundice, circulatory and respiratory problems. In this age group, subcutaneous metastases (bluish nodules) may be the presenting sign. Older children show a different pattern of metastatic spread. Diffuse bone pain, proptosis and periorbital ecchymoses (Hutchinson syndrome) may be present in case of bone, bone marrow and orbital tumour location. Lymph node metastases are also frequent. Constitutional symptoms include failure to thrive, fever, hypertension, bouts of sweating and pallor.^{7,8}

The major clinical staging systems (International Neuroblastoma Staging System (INSS)) based on the Evans staging system is shown in Table 1.⁷

Figure 4

Table 1: The international neuroblastoma staging system (INSS)

| | |
|----------|---|
| Stage 1 | Tumour with complete gross excision, with or without microscopic residual disease; representative ipsilateral lymph nodes negative for tumour microscopically (nodes attached to and removed with the primary tumour may be positive). |
| Stage 2A | Localized tumour with incomplete gross excision; representative ipsilateral nonadherent lymph nodes negative for tumour microscopically. |
| Stage 2B | Localized tumour with or without complete gross excision, with ipsilateral nonadherent lymph nodes positive for tumour. Enlarged contralateral lymph nodes must be negative microscopically. |
| Stage 3 | Unresectable unilateral tumour infiltrating across the midline (vertebral column) with or without regional lymph node involvement; or localized unilateral tumour with contralateral regional lymph node involvement; or midline tumour with bilateral extension by infiltration (unresectable) or by lymph node involvement. |
| Stage 4 | Any primary tumour with dissemination to distant lymph nodes, bone, bone marrow, liver, skin and/or other organs (except as defined for stage 4S). |
| Stage 4S | Localized primary tumour (as defined for stage 1, 2A or 2B), with dissemination limited to skin, liver and/or bone marrow (limited to infants <1 year of age). |

Increased urinary catecholamine metabolites and positive meta-iodobenzylguanidine (MIBG) scintigraphy of the

primary support the diagnosis of neuroblastoma. CT scan and/or MRI should be carried out to localize the tumour accurately, to provide anatomical information and mass measurements. For the detection of metastases, MIBG scan, bone scan and/or standard radiography may be indicated. Bone marrow aspiration and trephine biopsies are required from different sites to detect microscopic tumour involvement.⁹

Histological material is required to confirm diagnosis and to study prognostic factors in order to define treatment strategy. Electron microscopy helps to establish a diagnosis of neuroblastoma. Long cell processes resembling axons or dendrites are commonly observed and synaptic junctions may also be evident. These two features are particularly useful for distinguishing neuroblastoma from the other tumors which resemble it by light microscopic examination. Dense core neurosecretory granules are also frequently present in neuroblastomas by electron microscopy, but are nonspecific because they are also seen in small cell undifferentiated carcinomas. Microtubules and

intermediate filaments are two other characteristic but nonspecific electron microscopic findings.^{7, 10}

Different treatments are required at different stages of disease. Moreover, age at diagnosis, as well as prognostic factors influence treatment strategies. Patients should be treated following national or international treatment protocols or recommendations.

Briefly, localized tumours are treated by primary surgery if possible (stage 1 and 2). In case of unfavourable prognostic factors, adjuvant chemotherapy may be indicated. Pre-operative chemotherapy is recommended in inoperable stage 3 neuroblastoma. Megatherapy followed by autologous stem cell transplantation is indicated for children with MYCN amplified tumours. Local radiotherapy may be indicated in aggressive tumours with or without total resection of the primary.^{7,8}

Metastatic neuroblastoma (stage 4) requires neoadjuvant chemotherapy followed by surgery of the primary if possible. Megatherapy followed by autologous stem cell transplantation is indicated for patients with good responsiveness. Following megatherapy, retinoic acid as treatment for minimal residual disease was shown to increase survival. Treatment strategies in infants (less than 1 year) are similar to those in children, but whether megatherapy is indicated in infants remains matter of debate.

The treatment of the particular stage 4S disease may be extremely variable. About 50% are clinically “silent” tumours which may benefit from a “wait and see” strategy. They may regress spontaneously without any treatment, but half of them may need treatment because of tumour progression. In case of rapid evolution, chemotherapy, and/or radiotherapy are indicated. Surgery of the primary should be discussed after tumour response.^{7,8}

CONCLUSION

In the adult patient the diagnosis of neuroblastoma can sometimes elude the unwary. Although it is uncommon in adults, neuroblastoma should be considered in the differential diagnosis of patients with “small blue cell tumors”, particularly with primary sites of disease in the abdomen or retroperitoneum. Electron microscopy should be performed and urinary catecholamine metabolites measured in suspicious cases. A chest x-ray and bone marrow aspiration and biopsy are essential for accurate initial staging. Appropriate immunohistochemical studies and laboratory examination allow discrimination of this tumor from other differential diagnoses.

References

1. Allan SG, Cornbleet MA, Carmichael J, et al. Adult neuroblastoma: report of three cases and review of the literature. *Cancer* 1986; 57: 2419–21.
2. Cowan JM, Dayal Y, Schwaitzberg S, et al. Cytogenetic and immunohistochemical analysis of an adult anaplastic neuroblastoma. *Am J Surg Pathol* 1997; 21: 957–63.
3. Franks LM, Bollen A, Seeger RC, et al. Neuroblastoma in adults and adolescents: an indolent course with poor survival. *Cancer* 1997; 79: 2028–35.
4. Kaye JA, Warhol MJ, Kretschmar C, et al. Neuroblastoma in adults: three case reports and a review of the literature. *Cancer* 1986; 58:1149–57.
5. Mackay B, Luna MA, Butler JJ. Adult neuroblastoma: electron microscopic observation in nine cases. *Cancer* 1976; 37: 1334–51.
6. Hasegawa T, Hirose T, Ayala A, Ito S, Tomaru U, Matsuno Y, Shimoda T, Hirohashi S. Adult neuroblastoma of the retroperitoneum and abdomen clinicopathologic distinction from primitive neuroectodermal tumor. *The Am J Surg Pathol* 2001; 25(7): 918–924.
7. Schell M and Bergeron C. Neuroblastoma. *Orphanet Encyclopedia*. October 2003. <http://www.orpha.net/data/patho/GB/ukneuroblastoma>.
8. Esiashvili N, Goodman M, Ward K, Marcus R, Johnstone A. Neuroblastoma in adults: Incidence and survival analysis based on SEER data. *Pediatr Blood Cancer* 2007; 49: 41–46.
9. Tateishi U, Hasegawa T, Makimoto A, Moriyama N. Adult neuroblastoma: radiologic and clinicopathologic features. *Journal of Computer assisted tomography* 2003; 27(3): 321–26.
10. McLean TW, Iskandar SS, Shimada H, Hall MC. Neuroblastoma in an adult. *Urology* 2004; 64(6): 1232.e18–19.

Author Information

Adesh Manchanda, MDS, Oral Pathologist

Senior Lecturer, SGRD Institute of Dental Science & Research

Upasna Manchanda, MD

Internal Medicine