

# Letter to the editor: Otologic Complications Of Radiotherapy In Nasopharyngeal Carcinoma: Usefulness Of Pre-Therapy Grommet Insertion

K Mohanna, H Nasser, M Tariq

## Citation

K Mohanna, H Nasser, M Tariq. *Letter to the editor: Otologic Complications Of Radiotherapy In Nasopharyngeal Carcinoma: Usefulness Of Pre-Therapy Grommet Insertion*. The Internet Journal of Oncology. 2003 Volume 2 Number 1.

## Abstract

Nasopharyngeal carcinoma (NPC) is often managed by megavoltage radiotherapy (RT). However, both NPC (5) and RT (4) are associated with the risk of developing otitis media with effusion (OME). Since the introduction of grommet (ventilation tube) by Armstrong in 1954 (1) its usage following myringotomy became a common practice for the management of OME. Several investigators also recommended that patients with NPC treated with RT should have the accompanying secretory otitis media treated with grommet insertion (2,8). These studies emphasized the audiological success of middle ear ventilation but without any commentary on the complications arising from grommet insertion. Later, Skinner and van Hasselt (7) clearly showed significantly greater complications with grommet insertion in NPC patients as compared to control group. Although myringotomy with grommet insertion is considered an acceptable method of management of patients with secretory otitis media the clinical advantage of the use of grommet for the treatment of OME in patients who had received RT for NPC is still a matter of debate. Overall, there is no general agreement if grommet should be used for the treatment of OME in NPC patients who received RT.

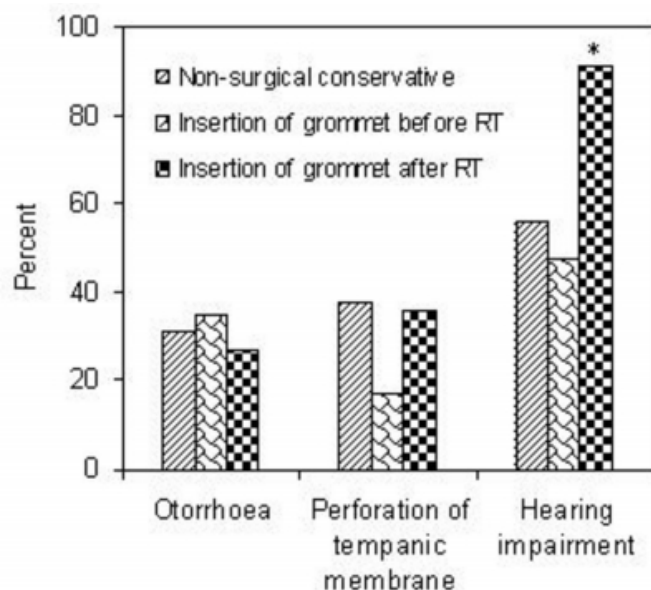
The purpose of this study was to compare otologic complications in 50 adult NPC patients (mean age, 41 years, range = 16-80 years; male:female ratio, 4:1) who received conservative treatment (N=16) or surgical intervention in the form of grommet insertion before (N=23) or after (N=11) external beam radiotherapy (dose, 70-75 Gy over a period of 6 weeks). The selection criteria and grouping of patients were based on the presentation of disease. The NPC patients who presented with the symptoms of significant hearing loss and ear blockade accompanied by OME received myringotomy and grommet insertion to relieve their

symptom and to avoid risk of spontaneous tympanic membrane perforation and subsequent infection even before radiating them. As both NPC and RT may initiate/aggravate OME with subsequent hearing loss and ear blockade such cases were categorized for myringotomy plus grommet insertion post-radiotherapy. Whereas the conservative treatment (hearing aids and pharmacotherapy for infection/inflammation) was intended to avoid the chronic complications associated with grommet insertion that might outweigh its short-term benefits. The incidence of complications including otorrhoea, hearing impairment and perforation of tympanic membrane was recorded in all the treatment groups. The mean follow-up period in this study was 4 years and 4 months.

Out of total 16 patients who received conservative treatment following RT, the incidence of otorrhoea, perforation of tympanic membrane, and hearing impairment were observed in 31%, 38% and 56% of the patients, respectively (Fig. 1). In the patients who were inserted with grommet before radiotherapy, otorrhoea was observed in 35% of cases, perforation of tympanic membrane in 17%, and hearing impairment was recorded in 48% of patients. On the other hand, for the patients, who were inserted with grommet after the radiotherapy, the incidence of otorrhoea and perforation were 27% and 36% respectively, however, a very high percentage of patients (91%) suffered from hearing impairment.

**Figure 1**

Figure 1: Comparison of various methods for controlling otological complications in nasopharyngeal carcinoma patients treated with radiotherapy. \*P



Our results clearly indicate that insertion of grommet before radiation therapy reduced the incidence of hearing loss. A lower frequency of tympanic membrane perforation was also seen, compared with the group of patients on conservative therapy. On the other hand, a significant increase in hearing impairment was observed in patients in which grommet was inserted after the radiation therapy. These findings are in agreement with some earlier investigators who observed higher incidence of complication following the post-RT insertion of grommet (<sup>7,9</sup>). The mechanism by which insertion of grommet after radiotherapy results in enhancement of complications is far from clear. Irradiation damage followed by insertion of grommet (a foreign body) around the tympanic membrane might contribute to a variety of complications including tubal inflammation and obstruction and diminished ability to combat and resist infection (<sup>3,6</sup>). It is also probable that RT can produce an altered local immune state and/or a change in the mucosa of the structures adjacent to the primarily irradiated area, which may account for further complications following grommet insertion. Surgical trauma due to myringotomy and grommet insertion following RT may further aggravate inflammation and infection that might exacerbate hearing impairment (<sup>3</sup>). On the other hand, insertion of grommet before radiotherapy might clear obstruction and relieve some of the otological

symptoms leading to a better tolerability to RT.

In conclusion, none of the 3 approaches used to control OME is free from otological complications though our findings suggest that insertion of grommet before radiotherapy is relatively a better choice. However, an alternative to grommet insertion for the sake of minimizing complications associated with it must be found. Two forms of possible treatment as alternative to ventilating tube in the middle ear cavity have been suggested (<sup>7</sup>). The first type is thermal myringotomy, the aim being to produce a semi-permanent perforation in the pars tensa of the tympanic membrane to allow adequate ventilation without the presence of foreign body (grommet). Secondly, the use of a hearing aid could be a useful form of long-term audiological rehabilitation in some of the patients.

## CORRESPONDENCE TO

Professor Mohammad Tariq Senior Consultant and Director  
Research Center Armed Forces Hospital P.O. Box 7897  
(W-912) Riyadh 11159, Saudi Arabia Fax: 966-1-470 0576  
E-mail: yasom70@hotmail.com

## References

1. ARMSTRONG B.: A new treatment for chronic secretory otitis media. *Arch. Otolaryngol. Head Neck Surg.* 59 (1954), 653.
2. Fletcher G.H., Healey J.E., McGraw J.P.: *Nasopharynx. In Cancer of the Head and Neck* (eds. W.W. MacComb and G.H. Fletcher), Williams & Wilkins, Baltimore (1967), pp. 152-153.
3. HO W., WEI W., YUEN A. et al.: Otorrhea after grommet insertion for middle ear effusion in patients with nasopharyngeal carcinoma. *Am. J. Otolaryngol.* 20 (1999), 12.
4. LAU S., WEI W., SHAM J. et al.: Effect of irradiation on middle ear effusion due to nasopharyngeal carcinoma. *Clin. Otolaryngol.* 17 (1992), 246.
5. LOW W., LIM T., FAN Y. et al.: Pathogenesis of middle ear effusion in nasopharyngeal carcinoma: a new perspective. *J. Laryngol. Otol.* 11 (1997), 431.
6. O'NEILL J., KATZ A. & SKOLNIK E.: Otologic complications of radiation therapy. *Otolaryngol. Head Neck Surg.* 87 (1979), 359.
7. SKINNER D. & VAN HASSELT C.: A study of the complications of grommet insertion for secretory otitis media in the presence of nasopharyngeal carcinoma. *Clin. Otolaryngol.* 16 (1991), 480.
8. WEI W., ENGZELL U., LAM K. et al.: The efficacy of myringotomy and ventilation tube insertion in middle ear effusions in patients with nasopharyngeal carcinoma. *Laryngoscope* 97 (1987), 1295.
9. WEISS M., LIBERATORE L., KRAUS D. et al.: Otitis media with effusion in head and neck cancer patients. *Laryngoscope* 104 (1994), 5.

**Author Information**

**Khabti Al Mohanna, MD**

Department of Otorhinolaryngology and Head and Neck Surgery, Armed Forces Hospital

**Haifaa Al Nasser, MD**

Department of Otorhinolaryngology and Head and Neck Surgery, Armed Forces Hospital

**Mohammad Tariq, FRCPath**

Department of Otorhinolaryngology and Head and Neck Surgery, Armed Forces Hospital