

# Vertebral Artery Dissection Stroke

A Mathew, M Roshen, V Biradar

## Citation

A Mathew, M Roshen, V Biradar. *Vertebral Artery Dissection Stroke*. The Internet Journal of Neurology. 2007 Volume 9 Number 2.

## Abstract

Vertebral artery dissection is a cause of stroke in young patients. It often occurs spontaneously and is sometimes accompanied by a history of sudden neck movement or trauma. The stroke developing presents mostly as a Wallenburg syndrome or depending on the area of compromise involved. We highlight here a case of bilateral Wallenburgs syndrome, associated with a right Vertebral artery dissection compromising the basilar artery. Our patient is a 55 year old man who developed left sided hemiparesis and bilateral truncal and limb ataxia on presentation. It is important to recognize this as a cause of stroke in young patients because timely intervention as been associated with minimal morbidity and near full recovery in most cases.

## INTRODUCTION

Vertebral Artery dissection (VAD) is a rarely encountered cause of stroke in clinical setting. It has an annual incidence of 1-1.5/10,000.<sup>[1]</sup> The incidence of bilateral dissection is about 30%<sup>[2]</sup> in cases reported. It plays an important role, especially as a cause of vertebro-basilar stroke in patients less than mean age of 48yrs of age.<sup>[10]</sup>

## CASE PRESENTATION

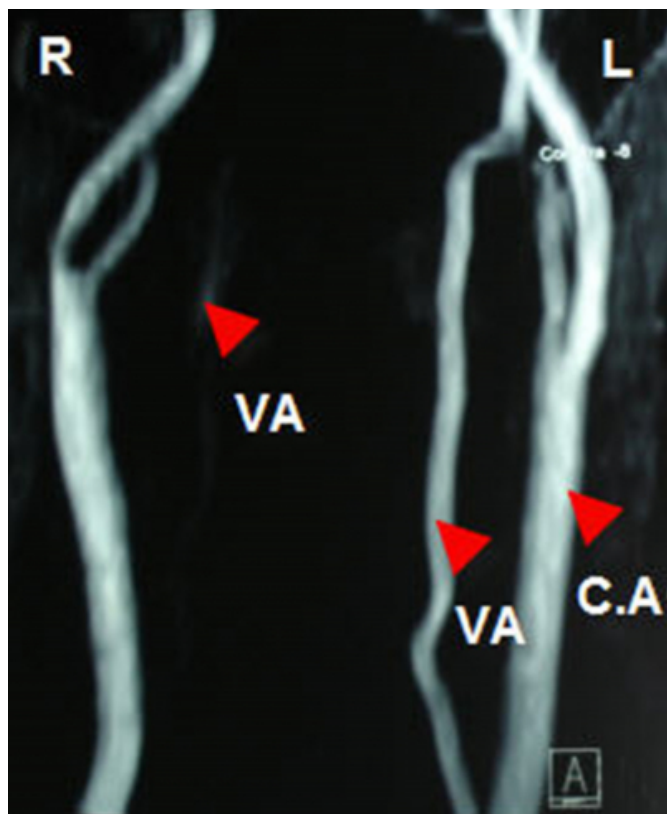
55 years, male patient, developed sudden dizziness, vertigo during manual labor at home. After an hour he complains of recurrent vomiting, severe occipitocervical pain and sense of imbalance. He also complained of mild weakness in the left side upper and lower limbs. On presentation BP was 180/120 mm Hg at the hospital. He had an asymmetry of face, right sided Horner's syndrome with nystagmus to the right. Power was 4/5 left upper and lower limb; 5/5 right upper and lower limb, which later progressed to 3/5 weakness of all limbs on left side in the hospital. Deep tendon reflexes brisk on the left side, and plantar reflexes extensor bilaterally. The patient had slurred speech and difficulty swallowing, with paresis of soft palate on both sides. Sensory examination showed decreased sensation on both sides of face. Finger nose test showed past pointing on both sides. He had difficulty in doing a tandem gait. Fundoscopy was normal. All other systems within normal limits. Our patient had a history of ischemic heart disease and hypertension for which he was on treatment. No history of diabetes mellitus. Complete blood counts, bleeding parameters, ESR all were within normal limits. Anti-

phospholipid antibodies, ANA, Anti-cardiolipin antibodies were also normal excluding vasculitis and collagen vascular diseases and VDRL was negative. MRI Brain showed: Acute infarct involving inferior cerebellar hemispheres both sides with, chronic infarct involving corona radiata on right side. All other investigations were within normal limits, except for the ECG which showed old same changes of IHD. MR Neck Angiogram (Fig 1.1) showed: normal caliber and flow in both carotid and left vertebral artery, with reduced flow in the vertebral artery on right side. T1 axial scan of neck shows hyperintense signal in the wall of the right vertebral artery suggestive of dissection.



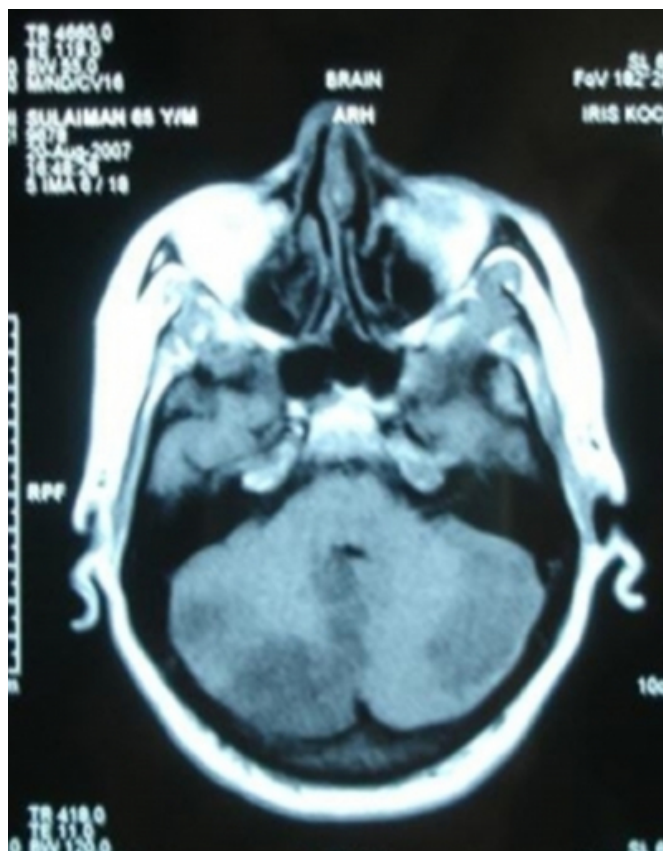
**Figure 1**

Figure 1.1: MR NECK ANGIOGRAM: Normal caliber and flow in both carotid arteries and left vertebral artery with reduced flow in vertebral artery right side. T1 scan shows hyperintense signal suggestive of dissection on right side. VA- Vertebral artery C.A- Carotid artery.



**Figure 2**

Figure 1.2: MRI BRAIN: Acute infarct involving inferior cerebellar hemispheres both sides.



## DISCUSSION

Vertebral artery Dissection is an uncommon cause of stroke in young patients. It accounts for about 67% [4] of the causes for cerebellar infarcts in age less than 45 years. It has a female preponderance [4] with 3:1 ratio. It's usually spontaneous during exercise, swimming, practice of yoga or sometimes associated with a history of neck trauma during chiropractic manipulation. (11%) [10] Few other causes contributing also include vasculitis, secondary to hypertension, Marfans syndrome, Ehler-Danlos Type 4 syndrome, syphilis and fibro muscular dysplasia.

The pathophysiology [12, 11, 3, 4] involves depending on the plane of the dissection. Most commonly it's a subintimal dissection, leading to intraluminal thrombi which propagate as emboli distally, and occlude the origin of posterior inferior cerebellar artery. This results in an infarction of the involved side cerebellum. Sometimes a dissecting hematoma may also progress to compromise the basilar artery also. If a subadventitial dissection occurs it may give rise to a sub arachnoid hemorrhage. Bilateral cerebellar infarcts can occur if the vertebral arteries are involved bilaterally as in



30% [3] cases reported, or it can occur very rarely due the dissection extending into the basilar artery, and causing spasm of the opposite cerebellar supply as in our case. [12]

The constellation of clinical symptoms [10, 11, 6, 8] is dependant on the area involved. Most commonly it involves the posterior inferior cerebellar artery and presents as a Wallenburgs syndrome with vertigo, nausea, occipital headache and posterior nuchal pain. It may also show nystagmus, dysdiadokinesis, dysmetria, dysphagia and dysphonia on ipsilateral side with ipsilateral Horner's syndrome and hemianesthesia of face. If the anterior inferior cerebellar artery is involved, a lateral inferior pontine syndrome may result. Rarely it may also cause an anterior spinal artery involvement, with spinal infarction and medial medullary syndrome.

The standard [5, 2] in the diagnosis of vertebral artery dissection is cerebral angiography. An angiographic pattern of 'string and pearl' sign due to focal narrowing of a long segment, and distal dilatation of the vertebral artery is seen characteristically.

With the advent of noninvasive imaging modalities MR imaging and MR angiogram have been used to demonstrate luminal abnormalities related to dissection, such as aneurysmal dilatation, an intimal flap, or occlusion. An intramural hematoma on T1 weighted imaging becomes isointense or mildly hyperintense for the first few days then it becomes more hyperintense.

The conservative treatment [8, 10, 11] includes immediate anticoagulation with Heparin, then follow up treatment on oral warfarin for 3 months as in our case. If there is persistence of stenosis after 3 months on MR Angiogram, anticoagulation is continued for further 3 months. If after 6 months stenosis persists patient is shifted onto antiplatelets agents continued for 2 years. Patients with bilateral cerebellar infarction can develop life-threatening complications because of edema of the infarcted tissue with resultant hydrocephalus and pressure on the brainstem, both of which can cause an altered mental state that may progress to coma.[6,7] Such patients should be monitored closely and if needed subjected to neurosurgical intervention. Surgical

options include balloon occlusion, surgical ligation, stenting or repair of the origin of the vertebral artery if transient ischemic symptoms present. [9,8] Gladly our patient didn't have any such complications and recovered with anticoagulation therapy.

The prognosis is excellent with 85% patients recovering near completely with residual hemianesthesia of the face, and they have less than 5% mortality rates. [10,11] Sub arachnoid hemorrhage associations had poor outcomes.

[10,11] Physicians and neurologists should promptly recognize and treat complications if any associated with bilateral cerebellar infarcts. Vertebral artery dissection should also be strongly suspected as a cause of cerebellar strokes especially in young patients.

### References

1. Blunt SB, Galton C : Cervical carotid or vertebral artery dissection- an under diagnosed cause of stroke in young. *BMJ* 1997; 314 : 243-245.
2. Morris P. *Practical Neuroangiography*. Williams & Wilkins, Baltimore. 1997.
3. Schievink WI: Spontaneous dissection of the carotid and vertebral arteries. *N Engl J Med* 2001 Mar 22; 344(12): 898-906
4. Mokri B, Houser OW, Sandok PA et al : Spontaneous dissections of the vertebral arteries. *Neurology* 1988; 38 : 880-885.
5. Mascalchi M, Bianchi MC, Mangiafico S et al. MRI and MR angiography of vertebral artery dissection. *Neuroradiology* 1997; 39(5):329-340.
6. Tada Y, Mizutani T, Nishimura T, Tamura M, Mori N. Acute bilateral cerebellar infarction in the territory of the medial branches of posterior inferior cerebellar arteries. *Stroke*. 1994;25:686-688.
7. Gopalan Umashankar, MD; Vivek Gupta, MD; Sami I. Harik, MD Acute Bilateral Inferior Cerebellar Infarction in a Patient With Neurosyphilis. *Arch Neurol*. 2004;61:953-956.
8. Schievink WI : The treatment of spontaneous carotid and vertebral artery dissections. *Curr Opin Cardiol* 2000; 15 : 316-321.
9. Hamada J, Kai Y, Morioka M, et al: Multimodal treatment of ruptured dissecting aneurysms of the vertebral artery during the acute stage. *J Neurosurg* 2003 Dec; 99(6): 960-6.
10. Saeed AB, Shuaib A, Al-Sulaiti G, Emery D: Vertebral artery dissection: warning symptoms, clinical features and prognosis in 26 patients. *Can J Neurol Sci* 2000 Nov; 27(4): 292-6.
11. Prabhakar S, Bhatia R, Khandelwal N, Lal V, Das CP: Vertebral artery dissection due to indirect neck trauma :an underrecognised entity. *Neurology India* 2001 49:384-90.
12. P Amarenco, JJ Hauw and JC Gautier: Arterial pathology in cerebellar infarction. *Stroke* 1990;21:1299-1305.



**Author Information**

**A. Mathew**

Department of Neurology Cooperative Medical College, Indira Gandhi Hospital

**M. Roshen**

Department of Neurology Cooperative Medical College, Indira Gandhi Hospital,

**V. Biradar**

Department of Neurology Cooperative Medical College, Indira Gandhi Hospital