

Third Pharyngeal Pouch Remnant Presenting As A Neck Cyst

C Gadepalli, R Mortimer, J Cooper

Citation

C Gadepalli, R Mortimer, J Cooper. *Third Pharyngeal Pouch Remnant Presenting As A Neck Cyst*. The Internet Journal of Head and Neck Surgery. 2006 Volume 2 Number 1.

Abstract

Objective:

We report an interesting case of a cystic swelling in the neck arising from third pharyngeal pouch and discuss the diagnostic dilemma, management and briefly review the literature.

Case report:

A 39 year old lady presented with a cystic lump in the left lower neck. Clinically it appeared to be thyroid swelling. Ultrasound scan confirmed it to be cystic, attached to the lower pole of the thyroid. It was cytologically acellular. Excision was performed as it recurred despite numerous aspirations. Histopathology showed both thymic and parathyroid tissue, suggesting an origin from third pharyngeal pouch.

Conclusion:

Understanding branchial arch development is important in managing developmental neck cysts. This avoids unnecessary surgery. Anomalies are commonly seen from the second arch but unusual from the rest. Clinical observations, imaging, fine needle aspiration cytology, surgical and histologic findings together aid in definitive diagnosis. Treatment of these cysts is surgical excision.

INTRODUCTION

Cystic swellings in the neck have varied aetiology and can be a diagnostic dilemma. Some of the commonly seen cystic swellings are thyroglossal cyst, branchial pouch cysts and cystic hygroma. Branchial pouch cysts usually arise from the first and second, unusually from the rest. We present an interesting case report of a neck cyst arising from the third pharyngeal pouch mistaken clinically as a thyroid cyst.

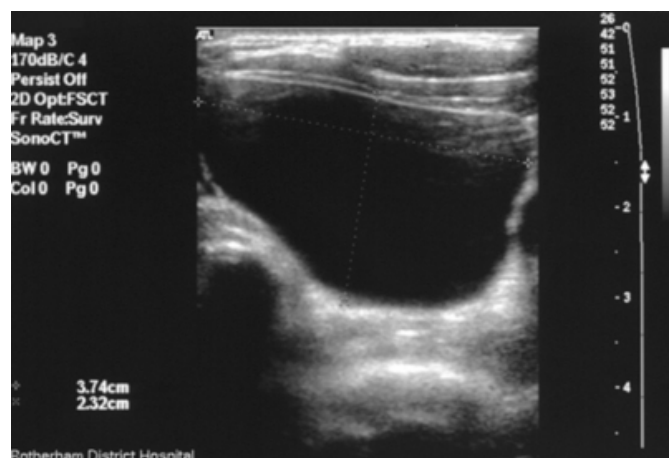
CASE REPORT

A 39 year old female presented to our clinic with a lump in the left lower neck. On examination it appeared to be a thyroid swelling. Ultrasound scan showed a cystic lesion close to the lower pole of the thyroid gland (figure 1). A clinical diagnosis of thyroid cyst was made. Fine needle aspiration showed a clear fluid and the contents were cytologically acellular. The swelling disappeared completely only to recur at a later date. Despite aspirating four times the cyst recurred causing a prominent swelling.

Elective surgical excision was planned. Intraoperatively there was a 4 X 6 cm, translucent cyst, behind the sternomastoid muscle, close to the tracheoesophageal groove and inferolateral to the thyroid. The lower pole of the cyst was attached to parathyroid. It showed no signs of invasion into the surrounding structures. The cyst was completely excised along with part of the parathyroid attached to it. Histopathological examination confirmed that it was a unilocular cyst. The key to the diagnosis was the tissue in the lower pole, which contained both parathyroid and thymic tissue. Postoperative recovery was good.

Figure 1

Figure 1: Ultrasound scan of the neck showing a unilocular cyst



DISCUSSION

Branchial pouch remnants causing swellings / sinuses are usually seen in younger individuals, uncommonly in adults. Amongst the branchial cleft anomalies second branchial cleft sinuses are the most common¹.

Thymus and inferior parathyroids develop from the third pharyngeal pouch around the sixth fetal week. The inferior parathyroids separate from the thymic tissue and remain close to lower pole of the thyroid, while the thymus descends into the mediastinum².

Neck masses moving upwards on deglutition could be thyroid or thyroglossal cyst in origin. It is difficult to differentiate between Thyroid, Parathyroid or Thymic swellings clinically.

Third pharyngeal cysts may be asymptomatic, minimally symptomatic or reach a size that causes obstruction to the larynx and hypopharynx³. It can be a diagnostic dilemma and frequently confused with thyroid or parathyroid swellings, as in our case. Children typically undergo multiple surgical procedures before the diagnosis of a third or fourth pouch anomaly is made⁴.

The differential diagnoses for cystic lesions in the neck include thyroglossal and branchial cleft cysts, cystic hygromas, primary and metastatic tumours, dermoids, teratomas, choristomas, tracheoesophageal and cervical bronchogenic cysts, as well as cystic neuromas, abscesses and lipomas. Ultrasound and CT scan are both good modalities to assess cervical cysts. They help in surgical planning and assessing the extent of the lesion⁵. On

ultrasound, they appear as hypoechoic masses and internal echoes. CT scan with contrast shows better margination and their relationship to the adjacent vessels. MRI plays important role in soft tissue evaluation⁵. Parenchymal cysts of the neck may be difficult to differentiate just by imaging. Clinical observations, fine needle aspiration cytology, surgical and histologic findings together aid in definitive diagnosis⁶.

Anatomically most of the cervical thymic lesions usually lie medial to the sternocleidomastoid muscle, anterior to the carotid sheath and lateral to the thyroid gland⁵. Nests of thymic tissue may be found anywhere along the descent of the thymic primordia from the angle of the mandible to the mediastinum. Mediastinal extension is seen in 50% of cervical thymic cysts⁶.

An understanding of the branchial apparatus and its anomalies may lead to greater precision in the clinical diagnosis and management of these congenital head and neck lesions. Although branchial anomalies have been well described, controversial issues, such as the branchial origin of lateral cervical cysts and the differentiation between third and fourth branchial pouch sinuses, remain unresolved⁷.

The treatment of these conditions is by surgical excision, particularly if symptomatic. If the patient has a sole parathyroid tissue cyst, then there is a risk of postoperative hypocalcemia if excised completely.

The cystic mass in our case had both thymic and parathyroid tissue which suggests a common origin. Hence we concluded that this mass is a third pharyngeal pouch cyst.

References

1. Ford GR, Balakrishnan A, Evans JN, Bailey CM. Branchial cleft and pouch anomalies. *J Laryngol Otol.* 1992 Feb;106(2):137-43.
2. Nguyen Q, Tar M de, Wells W, Crockett D, Cervical thymic cyst: case reports and review of literature. *Laryngoscope* 1996;106: 247-252.
3. Boysen ME, de Besche A, Djupesland G, Thorud E. Internal cysts and fistulae of branchial origin. *J Laryngol Otol.* 1979 May;93(5):533-9.
4. Rea PA, Hartley BE, Bailey CM. Third and fourth branchial pouch anomalies. *J Laryngol Otol.* 2004 Jan;118(1):19-24.
5. Jones JE, Hession B, Cervical thymic cysts. *ENT _ Ear, Nose and Throat Journal* 1996; 75-10: 678-680.
6. Ballal HS, Mahale A, Hegde V, Shetty R, Bhavikatti M, Naik S, Case Report: Cervical Thymic Cyst, *Ind J Radiol Imag* 1999; 9:4: 187-189
7. Mandell DL. Head and neck anomalies related to the branchial apparatus. *Otolaryngol Clin North Am.* 2000 Dec;33(6):1309-32.

Author Information

Chaitanya Gadepalli, MRCS, DOHNS

SHO General Surger, Rotherham NHS trust

Rachel Mortimer

PRHO General Surgery, Rotherham NHS trust

J.C. Cooper, FRCS

Consultant surgeon, Rotherham NHS trust