

A Fatal Case Of Methomyl Poisoning Leading To Fulminant Hepatic Failure

A Agha, S Dib, M Al-Hakami, M Abdulhadi Ali

Citation

A Agha, S Dib, M Al-Hakami, M Abdulhadi Ali. *A Fatal Case Of Methomyl Poisoning Leading To Fulminant Hepatic Failure*. The Internet Journal of Toxicology. 2008 Volume 7 Number 1.

Abstract

Methomyl is highly toxic carbamate poison which can cause muscarinic, nicotinic and central nervous system side-effects. It has also been associated with acute pancreatitis, as well as hepatic and renal dysfunction. Here we attempt to describe a case of 24-year-old male with suicidal ingestion of methomyl poisoning who developed fulminant hepatic failure in the absence of any evidence for acute viral or ischemic hepatitis, which later proved to be fatal. To-date this is the first reported case of methomyl associated fulminant hepatotoxicity. However further studies are warranted to closely study the association of liver failure with methomyl toxicity.

CASE REPORT

A 25 year old married male was presented in the emergency room in an unconscious state. The family gives a history that the patient was completely with no documented past medical history, when he was seen to drink a half a cup full of whitish powder mixed with juice and about 30 minutes later started to complain of abdominal pain, became drowsy and then unresponsive. He was brought to the emergency room within about 30 minutes of becoming unconscious. His Glasgow coma scale (GCS) of 4/15 on presentation with constricted pupils with normal pulse and blood pressure while examination for other systemic signs was negative. He was immediately intubated and shifted to intensive care unit on mechanical ventilation with 70% FiO₂. The same night the family brought the near empty wrapper of the powder sachet and it was found to be a locally manufactured carbamate poison with 90% methomyl inside. The patient's toxicology screen was negative for ethanol, benzodiazepines, barbiturates, cocaine metabolites, cannabinoids, opiates and amphetamine like compounds. He had metabolic acidosis with pH of 7.25 and bicarbonate of 17 which was treated with bicarbonate infusion. The facility for serum levels for methomyl were not available but as per the witnessed history and partially emptied wrapper of the sachet of poison was confirmed to be Methomyl. The patient was started on 2 mg atropine every 15-20 minutes and received about 62 mg of atropine which was titrated to achieve atropinization while keeping in mind pulmonary secretions and by the second day the patient was opening eyes spontaneously and alert,

oriented to person but difficult to arouse. He did not require any inotropic support nor had any hypotension spells and his ECG remained normal. He was not put on any antibiotics. His chest x-ray showed no abnormality and CT brain was normal (see figure 1A).

Figure 1

Figure 1 (A) showing normal CT scan on admission and (B) showing diffuse cerebral edema on 7 post admission day.

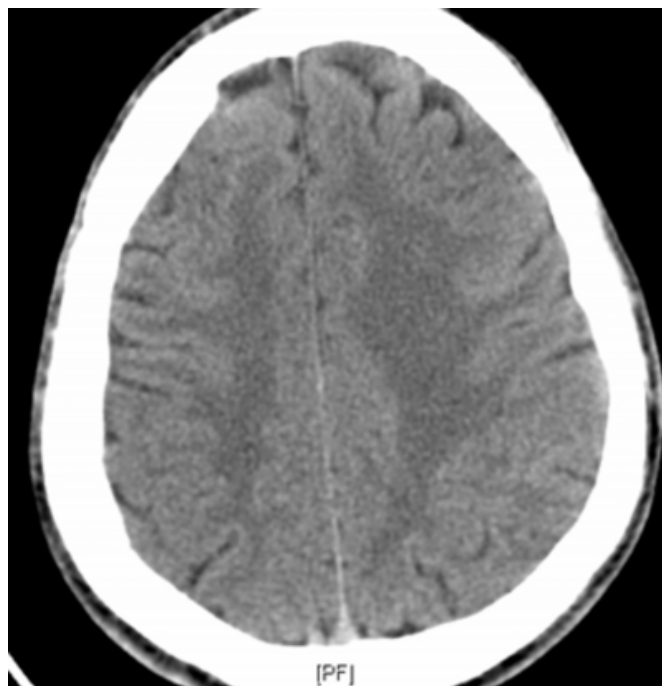
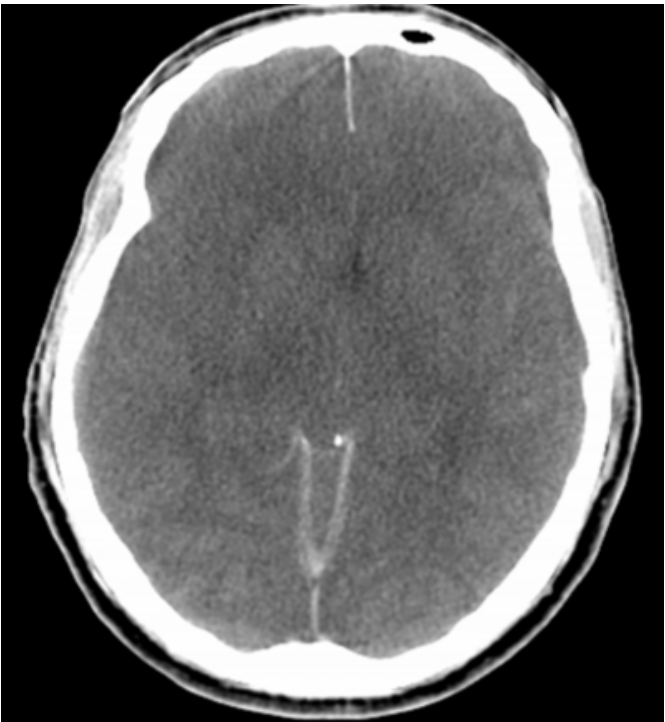
Figure 2



On the third day the patient started to have deranged renal and liver function tests and visible jaundice (see table 1). The acute hepatitis screening (HBsAg, Anti HCV, Anti HAV IgM, Anti HEV IgM) were negative with normal creatinine kinase. Because of deterioration of renal function continuous veno-venal hemodialysis was started on 4th post admission was started at 100 ml per hour. The patient also developed right sided pulmonary infiltrates, (figure 2) and blood culture showed *Klebsiella pneumoniae* sensitive to piperacillin/tazobactam, which was started.

Figure 3

Figure 2: Chest X-ray showing non-homogenous right lower lobe infiltrates

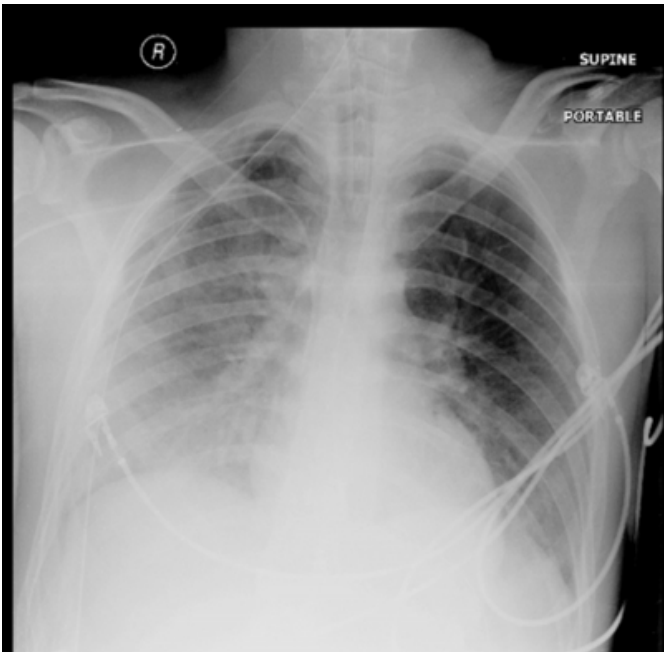


Figure 4

Table 1: Summary of Laboratory Data

Laboratory Data	08-03-2009	11-03-2009	18-03-2009	23-03-2009
Sodium mEq/L	136	146	145	140
Potassium mEq/L	2.7	5.0	3.0	4.3
ALT IU/L	26	13190	7006	280
AST IU/L	46	11712	2379	570
Bilirubin mmol/L	20	184	350	544
Prothrombin time seconds	14.4	88.3	35.6	23.2
Albumin G/L	36	32	21	19
GGT IU/L	23	111	86	105
ALT IU/L	58	116	350	179
WBC cells/L	16.1	10.5	25.9	22.4
Hemoglobin G/dl	14.8	11.6	9.1	10.1
Urea mmol/L	3.5	6.7	16.1	65.4
Creatinine mmol/L	83	322	231	534

Legends: ALT=alanine aminotransferase, AST=aspartate aminotransferase, ALP=alkaline phosphatase, GGT=gamma glutamyl transferase, WBC= white blood cells

The patient continued to have further deterioration of Bilirubin along with deranged albumin and prothrombin time with near normalization of AST and ALT indicating an acute liver necrosis picture. The patient required multiple fresh frozen plasma and albumin infusions to correct the

biochemical abnormalities. The patient then started to become drowsy and developed hypotension and was thus put on inotropic support. The patient became unconscious over the next 2 days and developed absent brainstem reflexes and repeat CT scan showed diffuse cortical edema (see figure 1B). Brain death was declared as per electroencephalogram done on 9th post admission day. The patient continued to be on ventilatory and inotropic support for another 4 days with continued decline of vital signs and finally had cardiac arrest on 14th post admission day.

This case shows methomyl poisoning case which recovered within three days of initial nicotinic, muscarinic and central nervous system (CNS) signs and symptoms to develop fulminant hepatic failure later on and subsequently died.

REVIEW OF LITERATURE

Carbamate insecticides are widely used in agriculture and home gardening. They are derivatives of carbamic acid (as the organophosphates are derivatives of phosphoric acid) and, like organophosphates, their mechanism of action is that of inhibiting the vital enzyme acetyl cholinesterase which is reversible as compared to organophosphates which is irreversible.¹ Carbamylation of the acetyl cholinesterase enzyme is reported to be short-lived and they are reported to hydrolyze spontaneously from the cholinesterase enzymatic site within 48 hours but the drug is metabolized via hepatic demethylation and excreted through feces.² Carbamates allow accumulation of acetylcholine at parasympathetic neuroeffector junctions (muscarinic effects) causing bradycardia, vomiting, diarrhea, miosis, excessive salivation and fluid losses causing systemic hypotension; accumulation at skeletal muscle myoneural junctions and autonomic ganglia (nicotinic effects) causing muscle tremors and weakness, and in the brain (central nervous system effects) causing agitation, seizures and coma.³ It can also cause metabolic acidosis however respiratory depression combined with pulmonary edema is the usual cause of death from poisoning by N-methyl carbamate compounds.⁴

Differentiating carbamates from organophosphates based on clinical presentation is often difficult because of the similarity of symptoms, yet urgent treatment decisions must often precede analytical or historical confirmation. Atropine is the primary drug used to treat symptomatic cases involving both organophosphate and carbamate insecticides.⁵ The use of pralidoxime in carbamate intoxications is often not recommended, is considered unnecessary, or is specifically contraindicated, especially with the use of

carbaryl (Sevin).⁵

Methomyl is highly toxic N-methyl carbamate with (Z)- and (E)-isomers and used in agricultural pesticides with lethal dose (LD₅₀) of less than 50 mg/kg.⁶ Several fatal cases of accidental and suicidal poisoning with methomyl has been reported in literature with CNS depression being the most common cause.⁷ Methomyl intoxication can cause some degree of hepatic and renal dysfunction but acute hepatic or acute renal failure has not been reported secondary to its poisoning.⁸ Methomyl intoxication is also associated with development of acute pancreatitis and various case reports have proposed oxidative injury mechanism as a possible explanation for the acute pancreatitis.^{9,10} To the best of the authors' knowledge this is the first case in which the patient after taking suicidal methomyl overdose developed cholinergic symptoms and CNS depression with deep coma and recovered with atropine treatment in 48-60 hours only to develop fulminant hepatic failure three day after exposure likely due to direct toxicity as the drug is metabolized in the liver, leading on to brain death and ensuing circulatory collapse.

CONCLUSION

Methomyl is highly toxic carbamate poison associated with many complications. This is probably the first case in which the patient after taking suicidal methomyl overdose, developed cholinergic symptoms and CNS depression with deep coma but recovered with atropine treatment within 3 days. He later developed fulminant hepatic failure and renal failure, leading to brain death and ensuing circulatory collapse. The lethal dose of methomyl is about 6400 mg/kg and studies have shown chronic exposure of 2 mg/kg/day to be safe among healthy volunteers. We conclude that there is a probable association of acute liver necrosis with hepatic-metabolized methomyl overdose that needs further research to avoid this complication in the future.

References

1. Farm Chemical Handbook. Willoughby, Ohio, Meister Publishing, 1991
2. Taylor P: Anticholinesterase agents, hI Gilman AG, Rall TW, Nies AS, Taylor PGB (Eds): The Pharmacological Basis of Therapeutics, 8th edition. New York, NY, Pergamon Press, 1990, pp 131-149
3. Baron RL: Carbamate insecticides, In Hayes WJ, Laws ER (Eds): Handbook of Pesticide Toxicology-Vol 3, Classes of Pesticides. San Diego, Calif, Academic Press, 1991, pp 1125-1 189
4. International Life Sciences Institute (ILSI). Common Mechanism of Toxicity: Evaluation of Carbamate Pesticides(International Life Sciences Institute, Washington, DC). 1999

5. Martinez-Chuecos J, Molinero-Somolinos F, Sole-Violan J, Rubio-Sanz R: Management of methomyl poisoning. *Hum Exp Toxicol* 1990; 9:251-254
6. Liddle JA, Kimbrough RD, Needham LL, et al: A fatal episode of accidental methomyl poisoning. *Clin Toxicol* 1979; 15:159-167
7. Miyazaki T, Yashiki M, Kojima T, Chikasue F, Ochiai A, Hidani Y: Fatal and non-fatal methomyl intoxication in an attempted double suicide. *Forensic Sci Int* 1989; 42:263-270
8. Kurtz PH: Pralidoxime in the treatment of carbamate intoxication. *Am J Emerg Med* 1990; 8:68-70
9. Panieri E, Krige JE, Bornman PC, Linton DM. Severe necrotizing pancreatitis caused by organophosphate poisoning. *J Clin Gastroenterol* 1997; 25:463-5.
10. Pederzoli P; Bassi C; Vesentini S; Campedelli A. A randomized multicenter clinical trial of antibiotic prophylaxis of septic complications in acute necrotizing pancreatitis with imipenem. *Surg Gynecol Obstet* 1993; 176:480-3.
11. Munidasa UA, Gawarammana IB, Kularatne SA, Kumarasiri PV, Goonasekera CD. Survival pattern in patients with acute organophosphate poisoning receiving intensive care. *J Toxicol Clin Toxicol* 2004; 42:343-7.

Author Information

Adnan Agha

Registrar, Internal Medicine, Department of Internal Medicine, Armed forces Hospital Southern Region

Saudi Dib

Consultant, Gastroenterologist, Department of Internal Medicine, Armed forces Hospital Southern Region

Mohammad Al-Hakami

Consultant Neurologist, Department of Internal Medicine, Armed forces Hospital Southern Region

Mamdouh M. Abdulhadi Ali

Consultant Gastroenterologist, Department of Internal Medicine, Armed forces Hospital Southern Region